



Review

CLINICAL AND RADIOLOGICAL RESULTS OF SEVERE ACETABULAR BONE DEFECTS IN REVISION TOTAL HIP ARTHROPLASTY USING MODULAR POROUS METAL COMPONENTS: A NARRATIVE REVIEW

S. Rizzo¹, M. Grasso¹, A. Benedetto¹, M. Smaldino¹, G. Solarino¹ and A. Pannella²

¹Orthopaedics University of Bari “Aldo Moro”- AOU Policlinico Consorziiale, Department of Translational Biomedicine and Neuroscience, Orthopaedic & Trauma Unit, Bari, Italy;

²Orthopaedics Unit, Don Tonino Bello Hospital, Molfetta, Italy

Corresponding author:

Stefano Rizzo, Md

School of Medicine,

University of Bari “Aldo Moro”- AOU Policlinico Consorziiale,

Department of Translational Biomedicine and Neuroscience,

Orthopaedic & Trauma Unit Policlinico,

Piazza Giulio Cesare 11,

Bari 70124, Italy

e-mail: dr.stefanorizzo@gmail.com

ABSTRACT

The incidence of total hip arthroplasty (THA) revisions is expected to rise significantly in the future, due to the population's greater life expectancy and the decreasing age of patients undergoing primary THA. Several alternative surgical techniques have been suggested depending on the extent and kind of acetabular bone loss. The aim of this review is to analyze the clinical and radiological mid-term and long-term outcomes of Paprosky II and III acetabular bone defects treated with modular porous metal components and their survivorship rate. We reviewed 15 articles in the literature based on the treatment of acetabular revisions. The literature review was conducted using electronic databases from their dates of inception. In severe acetabular bone defects, especially those classified as Paprosky II e III, metallic materials are proposed for their biomechanical properties to ensure primary fixation by a roughness effect. Modular porous metal components represent a promising type of implant, but the literature is controversial, and few articles show mid-term follow-up. The studies reviewed demonstrate an excellent result in follow-up but also reported complications and limitations; therefore, the use of certain implants and specific surgical techniques must be performed according to the severity of the bone loss and the patient's clinical conditions.

KEYWORDS: *total hip arthroplasty, revision, bone defect, trabecular metal, Paprosky*

Received: 15 June 2023
Accepted: 02 August 2023

ISSN 1973-640

Copyright © by BIOLIFE 2023

This publication and/or article is for individual use only and may not be further reproduced without written permission from the copyright holder. Unauthorized reproduction may result in financial and other penalties. **Disclosure: All authors report no conflicts of interest relevant to this article.**

INTRODUCTION

The incidence of total hip arthroplasty (THA) revisions is expected to rise significantly in the future, due to a greater life expectancy of the population and the age of patients undergoing primary THA. By 2030, there will be a 174% increase in THA procedures in the U.S. (1).

The most frequent cause of acetabular revisions is symptomatic aseptic loosening due to fixation failure and osteolysis; infection and instability represent less frequent reasons (2). Acetabular bone defects are the most popular reasons for revision THA and could be a technically demanding and surgical challenge for orthopaedic surgeons.

Depending on the extent and type of acetabular bone loss, several alternative therapeutic methods have been suggested: uncemented hemispherical cups, structural allografts, impaction bone grafting (IBG), antiprotusio cages, reinforcement rings or cages with allograft, oblong cups, trabecular metal (T.M.) augments and shells, titanium porous-coated acetabular shell, cup-cage constructs, saddle prosthesis, and custom-made triflange components (3, 4). In several recent studies, some authors prove the effectiveness of managing major acetabular bone loss with custom-made options and modular solutions characterized by the combination of T.M. or titanium prosthetic components (5). T.M., like titanium, is safe in terms of biocompatibility, shares native bone's biomechanical properties, and both facilitate bone ingrowth (6, 7).

This review of the current literature aims to analyze the clinical and radiological mid-term and long-term outcomes of Paprosky II and III acetabular bone defects treated with modular porous metal components and their survivorship rate. Consequently, we reviewed 15 articles of the literature on the treatment of revision THA.

METHODS

Because of the rarity of the case reported here, this article begins with a review of the literature focusing on revision THA in Paprosky type II and III acetabular bone defects using modular porous metal components. The preferred reporting items for systematic reviews and meta-analyses (PRISMA) guidelines were followed (8).

Literature and database searches

Two researchers (S.R. and M.S.) independently searched three databases – PubMed, the Cochrane Library, and Google Scholar – for the keywords “total hip arthroplasty”, “revision”, “bone defect”, and “trabecular metal”. A third researcher (M.G.) independently verified the number of articles identified to avoid potential discrepancies (Table I).

Table I. *The search strategy summary*

| Items | Specification |
|--|--|
| Date of Search (specified to date, month and year) | January 2 nd 2023 |
| Databases and other sources searched | PubMed, the Cochrane Library, and Google Scholar |
| Search terms used | total hip arthroplasty; revision; bone defect; trabecular metal; Paprosky |
| Timeframe | From January 2005 until January 2022 |
| Inclusion and exclusion criteria | <p>The inclusion criteria were:</p> <ul style="list-style-type: none"> • Human studies that considered different postoperative complications; • Studies written in English. <p>The Exclusion Criteria Were:</p> <ul style="list-style-type: none"> • Articles published before 2004 or after the end of 2022; • Cadaveric and biomechanical studies; • Paprosky Type I bone defects • Paprosky Type IV bone defects and/or pelvic discontinuity; • Non porous metal implants; • Studies that did not report complications. |
| Selection process | Two non-blinded authors reviewed the titles and abstracts of each article identified in the literature search. If a study met all the criteria or the abstract did not provide enough information to include or exclude the report, full texts were obtained, reviewed and considered for data extraction. Whenever an agreement about study inclusion could not be resolved by consensus between the two reviewers, a third author decided about the inclusion |

Data extraction

Several articles were excluded after reviewing the titles and abstracts. The remaining articles extracted data regarding Paprosky type II and III acetabular bone defects and use of modular porous metal components. The following data were extracted (when reported): authors and year of publication, type of study and level of evidence, number of patients enrolled and mean follow-up, type and timing of complications, surgery technique, clinical and radiological outcomes, and percentage of survivorship of the implants.

RESULTS

A total of 3482 articles were identified in the following databases: PubMed (92), Cochrane (0) and Google Scholar (3390). Titles and abstracts were screened, 3462 articles were excluded, including 86 duplicates and 3376 articles that did not meet the inclusion criteria. The full text of 20 articles was reviewed, and 15 studies were included in the final meta-analysis (Fig. 1). These articles were published between 2015 and 2021. The characteristics of the included studies are summarized in Table II.

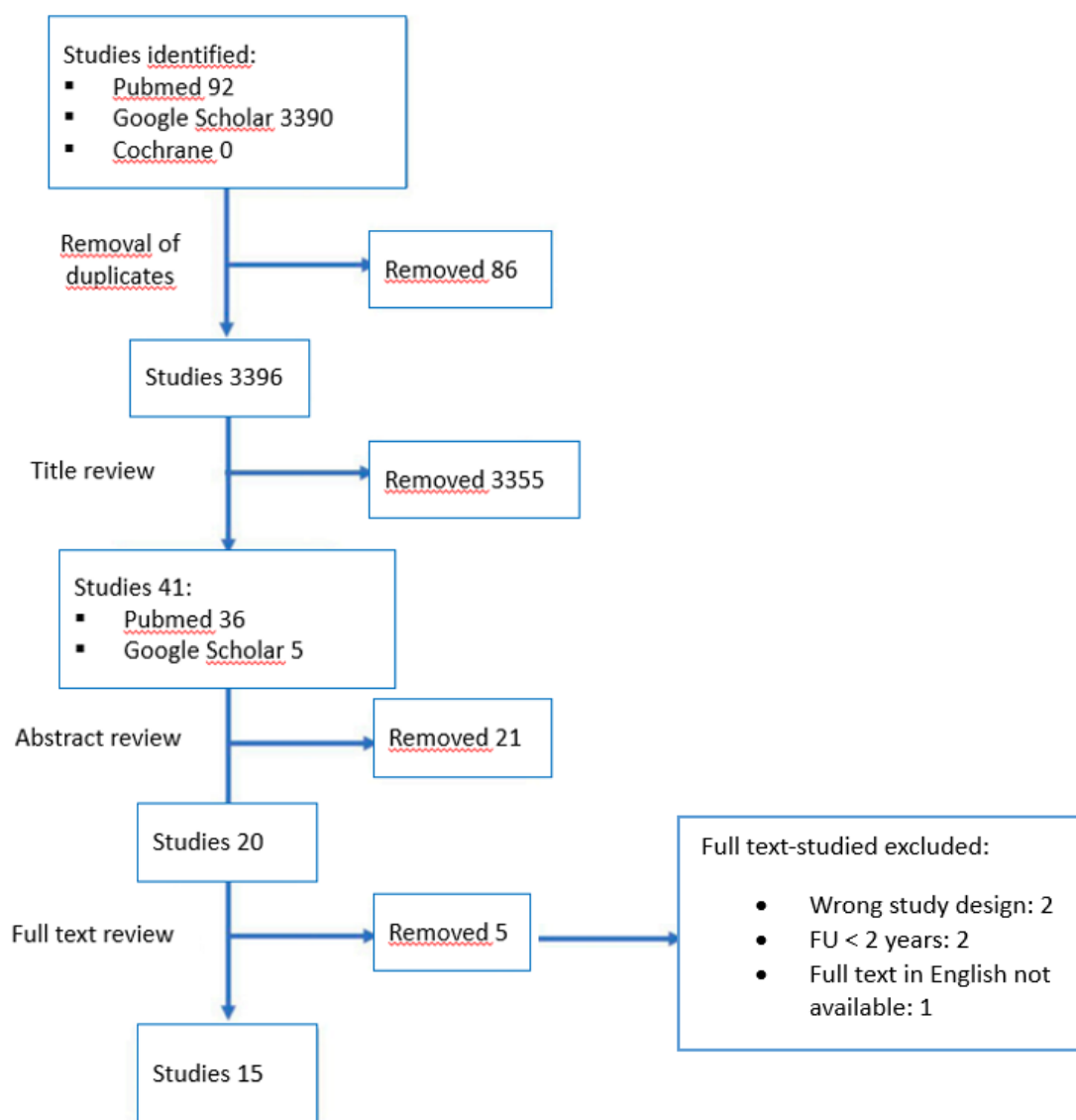


Fig. 1. Prisma flow chart

The published articles consist of studies describing the use of porous metal in revision THA in patients with the preoperative classification of Paprosky type II and III. Only two of these were prospectively performed (9, 10). The remaining studies were conducted retrospectively. The main indication for revision surgery was aseptic loosening. In general, revision was performed based on clinical symptoms and radiological findings. The outcome measures are summarized in Table III.

All studies included post-operative hip scores. In the studies in which preoperative hip scores were reported, the scores improved postoperatively. The review of 634 revision THA described in these articles has a mean follow-up period of 61.9 months and a mean survival rate with revision due to aseptic loosening of 95.7%. We found different treatment options for large acetabular defects. The TM Augment was the most widely used method in the included studies (7 studies, 331 hips). Trabecular titanium cups were used only in 2 studies (153 hips) (10, 11). Three studies (93 hips) involved using either a bone graft and/or a T.M. augment to provide stability for the acetabular component, with different goals. Prieto et al. (12) wanted to demonstrate excellent midterm survival, with 94% of acetabular components obtaining stable union onto host bone at 5 years, with Trabecular metal shells combined with structural bone allograft in revision THA.

Allograft restored bone stock with minimal resorption, and when it occurred, it did not alter the acetabular component's survivorship. Rowan et al. (13) compared IBG and trabecular metal for revision THA achieving good clinical outcomes for both, but there is greater success with T.M. in higher grades of acetabular deficiency regardless of prior infection. The purpose of Zhang et al. (14) study was to compare and analyze the clinical and radiological outcomes of the use of double

Table II. *Characteristics of the included studies*

| Authors | Year | Material of implants | N of Patients Enrolled | Type of defect (Paprosky) | Mean follow-up (months) |
|--------------------|------|----------------------|------------------------|--|-------------------------|
| Russell et al. | 2020 | Tantalum | 38 | 29 (76.3%) Type IIIA 9 (23.7%) Type IIIB | 87.6 (range 64,8-129,6) |
| Perticarini et al. | 2021 | Trabecular Titanium | 95 | 23 (24.2%) Type IIA 17 (17.9%) Type IIB 13 (13.8%) Type IIC 22 (23.1%) Type IIIA 20 (21.0%) Type IIIB | 91 (range 24-146) |
| Loppini et al. | 2018 | Tantalum | 16 | 7 (43,75%) Type IIIA 9 (56,25%) Type IIIB | 34 (range 24-72) |
| Grappiolo et al. | 2015 | Tantalum | 54 (55 hips) | 42 (76,36%) Type IIIA 13 (23,63%) Type IIIB | 53.7 (range 36-91) |
| Eachempati et al. | 2018 | Tantalum | 41 | 36 Type IIIA (87.8%), 5 Type IIIB (12.2%) | 39.4 (range 24-96) |
| De Meo et al. | 2018 | Trabecular Titanium | 58 | 25 Type IIB (39%), 15 Type IIC (23.4%), 15 Type IIIA (23.4%) 9 Type IIIB (14.1%) | 48.3 (range 38-82) |
| Jenkins et al. | 2017 | Tantalum | 57 (58 hips) | 28 Type IIIA (48%) 22 Type IIIB (38%) 4 Type IIA (7%) 3 Type IIB (5%) 1 Type IIC (2%) 11 Pelvic Discontinuity (19%) | 105 (range 60-150) |
| Konon et al. | 2016 | Tantalum | 46 | 20 Type IIA 4 Type IIB 9 Type IIC 6 Type IIIA 4 Type IIIB | 120 (range 120-144) |
| O' Neill et al. | 2018 | Tantalum | 38 | 29 Type IIIA 9 Type IIIB | 36 (range 18-74) |
| Zhang et al. | 2020 | Tantalum | 18 | 11 Type IIIA (61.1%) 7 Type IIIB (38.9%) | 61 (range 56-65.8) |
| Prieto et al. | 2017 | Tantalum | 56 (58 hips) | 6 Type IIA (10%) 12 Type IIB (21%) 12 Type IIC (21%) 11 Type IIIA (19%), 17 Type IIIB (29%) | 64,8 (range 24-144) |
| Rowan et al. | 2016 | Tantalum | 15 (17 hips) | 3 Type IIB 6 Type IIC | 64,8 (range 9,6-124,8) |
| Ji et al. | 2021 | Tantalum | 21 | 9 Type IIC 12 Type IIIB | 31 (range 18-57) |
| Webb et al. | 2017 | Tantalum | 20 | 11 Type IIIA 8 Type IIIB | 28,8 |
| Clement et al. | 2016 | Tantalum | 52 (55 hips) | 2 Type IIA 7 Type IIB 21 Type IIC 15 Type IIIA 10 Type IIIB | 63 (range 34- 105) |

T.M. cups alone or combined with IBG for revision surgery in complex acetabular defects, hypothesizing that these two methods were dependable techniques to manage Paprosky III acetabular defects without pelvic discontinuity. In addition to Zhang’s paper, three other studies use the Double TM cup technique (75 hips) to manage Paprosky type III defects. The results of the present review should not be considered conclusive but rather, hypothesis-generating.

Table III. Outcome measures

| Authors | Survival or reoperation rate | Complications | Clinical outcomes (Pre-operative / Final Follow Up) | Radiological evaluations |
|---------------------------|---|---|---|---|
| Russell et al. | mean survivorship of 8.99 years (± 0.56, 95% CI: 7.89-10.09). | Early postoperative - 1 (2.6%) Early infection recurrence (Washout, debridement, implant retention) - 1 (2.6%) Allograft resorption (Revised) - 1 (2.6%) Transient sciatic neuropraxia (No) Late postoperative - 3 (7.9%) Late infection recurrence (Revised) - 2 (5.3%) Aseptic loosening (with augment failure) (Revised) - 1 (2.6%) Dislocation from constrained liner (Revised) - 1 (2.6%) Recurrent dislocations due to greater trochanter nonunion (No) | WOMAC 49.15 (range: 3.1 to 98.4) / 22.75 (range: 0 to 89.6) | - Well integrated in 29 of 31 (93.5%) non revised cases. - 28 of 31 (90.0%) well osseointegrated (97%) (3 or more signs of osseointegration according to Moore's Criteria) |
| Perticarini et al. | 88.54% (95% CI 80.18–93.52%) at 71 months, | Late postoperative - 7 (7.3%) patients suffered of deep infection at a mean time of 35.85 months after surgery. (Revised) - 7 (7.3%) patients underwent dislocation - 2 (2.1%) periprosthetic femoral shaft fractures - 1 (1.05%) case of trochanteric bursitis. | HHS 43.7 (range 25–70) / 84.4 (range 46–99) | - 1 case of reabsorption of the graft, resulting in cup loosening 1 year after surgery (1.05%) - In all other acetabular components evident signs of osseointegration, without any radiolucent lines, sclerotic areas, or periprosthetic osteolysis. |
| Loppini et al. | 100% at 34 months | 3 (6.3%) patients: - 1 deep venous thrombosis - 1 femoral artery occlusion - 1 postoperative haematoma | HHS 19.38 (range: 14–26) / 77.2 (range: 62–88) WOMAC 34.4 (range: 28.6–40.5) / 82.3 (range: 70.8–92.4) | Radiolucent lines: 1 of the 16 (6.3%) of the 16 hips was noted a radiolucent line in zone I which was not progressive at the latest follow-up. |
| Crappiolo et al. | The survival rate at 2 and 5 years was 96.4% and 92.8%, respectively. The mean implant survival was 85.8 months (95% CI: 80.9–90.8). | Early postoperative 1 (1.8%) recurrent instability Late postoperative 3 (5.4%) aseptic loosening of the cup (in 2 cases cup + augment) | HHS 40 (range: 27–52) / 87.1 (range: 61–91) | Radiolucent lines: 3 of the 55 (5.4%) of the 16 hips (not progressive) |
| Eachempati et al. | The survival rate at 8 years was 100% | Overall complications in 2/41 patients (4.87%) 1 persistent wound discharge (Washout, debridement, implant retention) - 3 recurrent dislocations (5.2%); - 2 deep infections (3.4%); - 1 suspected aseptic loosening | HHS 26,5 (range: 14–34) / 90.5 (range: 61–100) | No radiological failures at the time of latest follow-up |
| De Meo et al. | The survival rate at 48.3 months was 89.7% for revision and of 94.8% for acetabular cup removal | In 6 cases (10.3%) reoperation was necessary: - 3 recurrent dislocations (5.2%); - 2 deep infections (3.4%); - 1 suspected aseptic loosening | HHS 36,5 / 83,7 (range: 58,9-91,3) | No radiolucent lines or other sign of migration were observed. |
| Jenkins et al. | rate of survivorship free of any re-revision of 100% at 5 years and 97% at 10 years. | 2 of the 58 constructs (3%) failed because of aseptic loosening. | MAYO Hip Score 35,7 (range: 6 to 72; n = 19) / 61,7 (range: 33 to 80; n = 42) | - No lucencies of >1 mm were identified immediately postoperatively - 6 of 58 hips (10%) clear radiographic evidence of separation (>2 mm) in zone 3 (risk for future failure) |
| Konan et al. | The survivorship for further revision of the acetabular component as the end point, was 96% at 11 years (95% CI 92.7 to 98.7) The survivorship for any reason as the end point, was 92% at 11 years (95% CI 90.2 to 94.8). | 2 of the 46 failed because of aseptic loosening 2 recurrent hip dislocations within two years | WOMAC 91.1 (range: 33.3 to 100) UCLA 5.5 (range: 2 to 10) Oxford Hip Score* 91.2 (range: 31.8 to 100) | Radiographs follow-up at a mean of 30.9 months (24 to 51): In 39 of 40 hips (40 patients) there was radiological evidence of osseointegration (Moore's criteria) Radiographs follow-up at the time of review: 32 of the 38 patients who remained alive showed evidence of osseointegration |
| O' Neill et al. | 3-year survival rate with revision due to any cause 92.1% (83-101) with 35 patients at risk 3-year survival rate with revision due to aseptic loosening was 94.7% (87-102) | 2 radiographic metal debris at the shell-augment interface. 8 Brooker grade 1 HO 3 grade 2 HO 3 grade 3 HO 2 deep infections. 1 trochanteric nonunion 1 transient sciatic nerve palsy In 4 patients bone graft resorption and medial migration of the shell | WOMAC 53 / 78.8 SHORT FORM 12 (SF-12) 27.7 / 30.1 | 31 of 38 patients: shell-augment construct satisfied the criteria for osseointegration (Moore's criteria) |
| Zhang et al. | Survivorship of the last follow-up: No failure | Complication incidence (33.3%), - dislocation (16.7%), - delay wound healing (16.7%) - Trendelenburg-positive in 2 hips (11.1%) - Asymptomatic grade-1 HO in 3 (16.7%) No patients underwent re-revision surgery for any reasons at the last follow-up | HHS 44.1 (range: 35 to 50) / 73.7 (range: 68 to 85) UCLA score 2.6 (range: 2 to 4) / 7.3 (range 7 to 8) | Bone graft incorporation in all hips one year after the revision operation |
| Prieto et al. | 5-10 year survival rate with revision due to any cause 90% and 88%, respectively 5-10 year survival rate with revision due to aseptic loosening: 94% | 8 complications in 7 patients in the entire cohort: 1 periprosthetic infection 1 periprosthetic femoral fracture 1 femoral stem loosening 2 sciatic neuropraxias 3 patients with recurrent dislocations. | HHS 47 (range: 29-80) / 79 (range: 45-100) | Average allograft coverage was 42% of the acetabular component (28%-70%): 12 hips >50% of graft coverage 36 hips between 30% and 50% 7 hips <30% Allograft resorption < 25% in 14 hips (26%) >35% in 3 hips |
| Rowan et al. | | 1 dislocation Reconstruction failure requiring revision 0% | HHS 52.2 / 83,3 (range: 58,9 - 91,3) | |
| Ji et al. | Survivorship free from re-revision for acetabular loosening after 2 years was 100 %. | 2 deep venous thrombosis (10 %) | HHS 37.0 ± 7.1 (range: 24.3–47.7) / 76.4 ± 9.0 (range: 55.1–90.1). | - All acetabular components were all stable without migration - Non-progressive acetabular radiolucencies in no more than two zones in 2 patients. - A total of 18 patients (86 %) satisfied at least ½ Moore's criteria |
| Webb et al. | 100% survivorship for aseptic loosening and an 80% survivorship from revision for any cause of the double cup constructs | 12 (60%) of recorded complications were in 8 patients. - 6 total dislocations (30%) - 4 deep infection (20%) | HHS 28,2 (range: 14-45) / 28,7 (range: 19-89) | - No radiographic evidence of failure based on Moore's criteria |
| Clement et al. | implant survival was 92% (95% confidence interval: 80.2-96.9%) at 5 years | - 2 Early infections (1 and 7 Months to Failure) - 2 recurrent hip dislocations (15 and 28 Months to Failure) - 1 quadriceps palsy - 1 abductor weakness | *follow-up rate of 78%. OHS 34 (range, 5-48) | - All cases involving the use of bone grafts had radiographic evidence of incorporation - No progressive radiolucent lines or component migration - All acetabular components: Moore score >3 |

DISCUSSION

Acetabular revisions in complex bone defects are challenging procedures that often require an expert surgeon. There are many different options of reconstruction in literature, such as the Jumbo cup component, IBG combined with a cemented cup, metal mesh, bulk autograft or allograft combined with hemispherical cups, and cup cage construct (14). Although there are different surgical options, the literature remains controversial, showing complications and mid-term failures (15).

Reconstruction rings and cages are usually used in acetabular revisions where residual bone stock is available to gain fixation (16-18). However, literature has shown that off-the-shelf cages have no osteoinduction and osteoconduction potential and may loosen within seven to ten years, especially when morselized allograft is used (19, 20).

Using Jumbo uncemented acetabular component may require reaming the anterior column because most superior defects are elliptical (21). The surgical technique that uses a smaller hemispherical component at a high hip centre (17, 22) may alter the hip biomechanics and can cause a high dislocation rate (11%, five of 46 hips) and loosening rate (6%, two of 36 hips) (23, 24). Another promising surgery technique is custom tri-flange components, which have a high dislocation rate and require up to six weeks to create and achieve the component from a C.T. scan (25, 26). Custom-made implants are one way to manage large bone defects in revision surgery, adequately filling the bone gap and increasing interaction with native bone (14).

Most recently, modular trabecular titanium or tantalum implants like T.M. (Zimmer, Warsaw, IN, USA) have become popular in large acetabular bone defects. T.M. is made from elemental Tantalum on a uniform porous carbon skeleton and has several advantages, such as high porosity (75-85%), a high friction coefficient, and a similar modulus of elasticity (175 GPa for Tantalum vs 113 GPa for titanium) to the cancellous bone (350 MPa–15 GPa) (14). Those characteristics increase the shear strength at the bony interface, minimize stress shielding, promote an adequate grip where bone loss is present and consequently reduce implant failure rate (27).

Also, highly porous titanium cups recently developed, with a high porosity (>60%), a large pore size (>200 μm), a low elastic modulus (0.01–30 GPa), and a high coefficient of friction have demonstrated, in the same way, good results in acetabular replacement in acetabular bone loss defect despite some concerns about osseointegration and radiolucency that had developed (28).

The literature shows that the use of Tantalum represents the most elected type of implant in complicated THA revision: in the 15 articles analyzed, only in 2 papers did the surgeons use porous titanium. Perticarini et al. (10) and De Meo et al. (11) analyzed 95 and 58 hips treated with trabecular titanium revision cups, respectively; the choice of implant is based on surgeon experience. One study did not report significant differences in implant survival and complication rate reduction when used for acetabular revision surgery (7). Unfortunately, this study presents different limitations: it is a retrospective review of prospectively entered data with no control group for comparison. Furthermore, there may be variations in the data due to different surgical techniques performed by different surgeons, even though all the surgeons are experts in revision hip surgery and follow the surgical technique described in the literature.

All the lectures analyzed in our review have shown similar excellent results at midterm follow-up, demonstrating that the acetabular augment used for structural support and cemented to the acetabular shell promotes bone ingrowth, a good fixation of the acetabular component and adequate midterm results in revision cases. From a clinical point of view, patients of our review improved at mid-term follow-up. Clinical outcomes are described in all the studies: Harris Hip Score (HHS), Mayo Hip Score, WOMAC, UCLA and Oxford Hip Score.

Eachempati et al. (29) noted a good functional outcome in their series [preoperative HHS 26,5 (range: 14-34) to 90.5 (range: 61–100) at 39.4 months of mean follow-up]; these results are in line with the series of the other authors (12-15, 29-34). The clinical results of the other authors who evaluated different scores are also satisfactory. Table III shows raw data from WOMAC, Oxford scores, and Mayo hip score of the other series.

Few studies have evaluated the results of modular porous metal components in patients with Paprosky IIIA and IIIB defects. Russell et al. (9) reported an estimated mean implant survivorship of 8.99 years with an overall complication rate of 34% (13 of 38) inclusive of an 18.4% (8 of 38) repeat surgery rate (1 washout, debridement, and implant retention and 7 revision THA procedures) at a mean follow-up of 87-6 months. Grappiolo et al. (35) described 55 revisions in 54 patients with Paprosky IIIA (42) and IIIB (13) defects and reported a lower overall complication rate (9,1%). Four acetabular component revisions were made for aseptic loosening (5,4%) at a mean follow-up of 25 months (17 to 38 months). There was no description of the preoperative bone defects in the hips revised for aseptic loosening. The survival rate at two years was 96.4%, and 92.8% at five years. O'Neill et al. (36) evaluated 38 patients with Paprosky IIIA (29), Paprosky

IIIB (9) defects, and four patients with pelvic discontinuity. They described a 94.7% survivorship with aseptic loosening in a follow-up of three years. Perticarini et al. reported a mean survivorship of 88.54% (95% CI 80.18–93.52%) at 91 months follow-up (maximum 146 months) in 95 patients treated with trabecular titanium cups (10). These results align with those presented by De Meo et al. in a recent article where they used trabecular titanium in hip revision with an overall survivorship of the cup of 94.8% at a follow-up of 48.3 months. The authors reported a rate of aseptic loosening of 1.5% at 48.3 months (11).

Other series with Paprosky IIIA and IIIB defects managed with tantalum augments and T.M. acetabular components ranging from 16 to 58 hips with follow-up ranging from 28.8 to 120 months have reported low failure rates related to aseptic loosening (12-15, 29-34).

Complications related to surgery were also described despite the significant survival rates reported in the studies. Five authors describe deep infections in post-operative follow-up: Russell et al. (9) showed one early infection recurrence, successfully treated with washout, debridement, and implant retention, and 3 (7.9%) Late deep infections that required a two-stage revision; in Perticarini et al. seven (7.3%) patients had a deep prosthetic infection at a mean time of 35.85 months post-surgery. Two had a history of periprosthetic joint infection sustained by *Pseudomonas Aeruginosa* and *Staphylococcus Aureus*. All of them required two-stage revision surgery (10). Webb et al. described four hips (20%) with a deep infection within one year. They undergo chronic suppression and irrigation/debridement with an exchange of modular components. One of these patients developed sepsis, and the components were removed (33). At least Clement et al. reported two cases of patients with deep infections treated with removal of all components at 1 and 7 months to failure, respectively (34).

Although the excellent bone-implant osseointegration has been described in the literature, several studies have described cases of aseptic loosening. Russell et al. reported 2 patients revised for augment hardware failure, one of which had extensive acetabular resorption after radiotherapy for bowel cancer (9). In Grappiolo et al. (35), 4 patients underwent acetabular component revision surgery: in one patient, the augment was still integrated into the bone, and a revision shell with a cemented liner without the removal of the augment was performed. Instead, another patient had an aseptic loosening 17 months post-surgery, and a revision with both shell and augment change was performed. After 16 months, he developed another aseptic loosening of the cup and underwent a third revision with Ganz's cage and tantalum-coated cup used as augmentation. Jenkins et al. (31) reported 2 cases of failure because of aseptic loosening. In one of these, the porous tantalum augment was not paired with a porous tantalum revision shell using their standard reconstructive technique with screws and methacrylate cement between augment, stressing the importance of creating a monolithic construct to reduce micromovements at the interface of the components and increase the stability of the implant.

Konan et al. reported a case where a patient needed another revision to a porous tantalum component with an augment after one year from the first revision surgery because the allograft used had been resorbed and the tantalum acetabular component migrated superiorly (15). Also, O'Neill et al. showed the same condition in the other 4 patients. These cases show how bone grafting coupled to augments is still debated in literature to improve osseointegration (36).

Another major complication in numerous studies is prosthetic dislocation: Webb et al. described a dislocation rate of up to 30% (6 hips). They treated those patients using closed reduction and bracing. One patient dislocated after one year post-surgery and was treated with revision to a constrained liner (33). Similar results are reported in the other revised articles.

The assumption is that a high rate of dislocation may depend on the severity of bone loss at the acetabular level, which prevents an optimal orientation of the cup; an interesting technique is described by Ji et al. that used a "multi-cup reconstruction technique" to achieve the desired cup anteversion and abduction based on the re-evaluated anatomic hip centre. They reported no cases of displacement in the follow-up with the use of this surgical technique (32).

The studies also reviewed a radiological evaluation to evaluate the stability of the components. The most used criteria are the radiolucent line and radiographic signs of osseointegration in porous-coated acetabular components according to Moore's criteria (37).

Russel et al. evaluated 31 THA and described well-osseointegrated components in 28 revisions with 3 or more signs of osseointegration according to Moore's Criteria (9). Perticarini et al. reported 1.05% reabsorption of the graft, resulting in a cup loosening 1 year after surgery (10). Loppini et al. (30) noted a radiolucent line in 6.3% of 16 hips in zone 1, which was not progressive at least follow-up; meanwhile, Grappiolo et al. (35) describe a non-progressive radiolucent line in 5.4% of the 16 hips, Ji et al. non-progressive radiolucencies in no more than 2 zone in 2 patients (32); Jenkins et al. quote no lucencies of > 1 mm were identified immediately postoperatively and 10% of hip ha clear radiographic evidence of separation (>2mm) in zone 3 (risk for future failure) (31). Non-progressive radiolucent lines or component migration have been described by De Meo et al. and Clement et al. (11, 34).

Konan et al. describe radiological proof of osseointegration in 39 of 40 hips (40 patients) (15), O’Neil reports 31 of 38 patients: shell-augment design met the requirements for osseointegration (36), and Webb et al. demonstrated no radiological failure according to Moore criteria (33). Moore’s Criteria are based on the radiographic findings of these reviews by Ji et al. and Clement et al. in the papers.

CONCLUSIONS

The modular porous metal components have become the most promising treatment of Paprosky II and III acetabular bone defects, demonstrating excellent results regarding midterm follow-up survivorship and clinical outcomes. Although the good results were reported in the articles reviewed, few articles are still focusing on this argument and with a limited follow-up. The studies reviewed also reported complications and limitations in using this technique, which must, therefore, be customized according to the bone loss severity and the patient’s clinical conditions.

REFERENCES

1. Kurtz S, Ong K, Lau E, Mowat F, Halpern M. Projections of primary and revision hip and knee arthroplasty in the United States from 2005 to 2030. *J Bone Joint Surg Am.* 2007;89(4):780-785. doi:<https://doi.org/10.2106/JBJS.F.00222>
2. Pulido L, Rachala SR, Cabanela ME. Cementless acetabular revision: past, present, and future. Revision total hip arthroplasty: the acetabular side using cementless implants. *Int Orthop.* 2011;35(2):289-298. doi:<https://doi.org/10.1007/s00264-010-1198-y>
3. Baauw M, van Hooff ML, Spruit M. Current construct options for revision of large acetabular defects: a systematic review. *JBJS Rev* 2016;4(11):
4. Shon WY, Santhanam SS, Choi JW. Acetabular Reconstruction in Total Hip Arthroplasty. *Hip Pelvis.* 2016;28(1):1-14. doi:<https://doi.org/10.5371/hp.2016.28.1.1>
5. Meneghini RM, Meyer C, Buckley CA, Hanssen AD, Lewallen DG. Mechanical stability of novel highly porous metal acetabular components in revision total hip arthroplasty. *J Arthroplasty.* 2010;25(3):337-341. doi:<https://doi.org/10.1016/j.arth.2009.03.003>
6. Bobyn JD, Stackpool GJ, Hacking SA, Tanzer M, Krygier JJ. Characteristics of bone ingrowth and interface mechanics of a new porous tantalum biomaterial. *J Bone Joint Surg Br.* 1999;81(5):907-914. doi:<https://doi.org/10.1302/0301-620x.81b5.9283>
7. Cruz-Pardos A, Garcia-Rey E, Fernandez-Fernandez R, Ortega-Chamarro J. Do trabecular metal cups achieve better results when compared to hemispherical porous titanium cups in acetabular revision surgery? *Hip Int.* 2021;31(6):774-781. doi:<https://doi.org/10.1177/1120700020919943>
8. Moher D, Liberati A, Tetzlaff J, Altman DG, Group P. Preferred reporting items for systematic reviews and meta-analyses: the PRISMA statement. *PLoS Med.* 2009;6(7):e1000097. doi:<https://doi.org/10.1371/journal.pmed.1000097>
9. Russell SP, O’Neill CJ, Fahey EJ, Guerin S, Gul R, Harty JA. Trabecular Metal Augments for Severe Acetabular Defects in Revision Hip Arthroplasty: A Long-Term Follow-Up. *J Arthroplasty.* 2021;36(5):1740-1745. doi:<https://doi.org/10.1016/j.arth.2020.12.033>
10. Perticarini L, Rossi SMP, Medetti M, Benazzo F. Clinical and radiological outcomes of acetabular revision surgery with trabecular titanium cups in Paprosky type II and III bone defects. *J Orthop Traumatol.* 2021;22(1):9. doi:<https://doi.org/10.1186/s10195-021-00571-1>
11. De Meo F, Cacciola G, Bellotti V, Bruschetta A, Cavaliere P. Trabecular Titanium acetabular cups in hip revision surgery: mid-term clinical and radiological outcomes. *Hip Int.* 2018;28(2_suppl):61-65. doi:<https://doi.org/10.1177/1120700018812992>
12. Prieto HA, Kralovec ME, Berry DJ, Trousdale RT, Sierra RJ, Cabanela ME. Structural Allograft Supporting a Trabecular Metal Cup Provides Durable Results in Complex Revision Arthroplasty. *J Arthroplasty.* 2017;32(11):3488-3494. doi:<https://doi.org/10.1016/j.arth.2017.05.051>
13. Rowan FE, Gorenchtein M, Aslam S, Condon F, Masterson EL. A comparison of acetabular impaction grafting and trabecular metal for revision arthroplasty. *Hip Int.* 2016;26(4):350-354. doi:<https://doi.org/10.5301/hipint.5000362>
14. Zhang X, Li Z, Wang W, Liu T, Peng W. Mid-term results of revision surgery using double-trabecular metal cups alone or

- combined with impaction bone grafting for complex acetabular defects. *J Orthop Surg Res.* 2020;15(1):301. doi:<https://doi.org/10.1186/s13018-020-01828-x>
15. Konan S, Duncan CP, Masri BA, Garbuz DS. Porous Tantalum uncemented acetabular components in revision total hip arthroplasty: a minimum ten-year clinical, radiological and quality of life outcome study. *Bone Joint J.* 2016;98-B(6):767-771. doi:<https://doi.org/10.1302/0301-620X.98B6.37183>
 16. Goodman S, Saastamoinen H, Shasha N, Gross A. Complications of ilioischial reconstruction rings in revision total hip arthroplasty. *J Arthroplasty.* 2004;19(4):436-446. doi:<https://doi.org/10.1016/j.arth.2003.11.015>
 17. Issack PS, Nousiainen M, Beksac B, Helfet DL, Sculco TP, Buly RL. Acetabular component revision in total hip arthroplasty. Part I: cementless shells. *Am J Orthop (Belle Mead NJ).* 2009;38(10):509-514.
 18. Issack PS, Nousiainen M, Beksac B, Helfet DL, Sculco TP, Buly RL. Acetabular component revision in total hip arthroplasty. Part II: management of major bone loss and pelvic discontinuity. *Am J Orthop (Belle Mead NJ).* 2009;38(11):550-556.
 19. Bostrom MP, Lehman AP, Buly RL, Lyman S, Nestor BJ. Acetabular revision with the Contour antiprotrusion cage: 2- to 5-year follow-up. *Clin Orthop Relat Res.* 2006;453(188-194). doi:<https://doi.org/10.1097/01.blo.0000246533.37006.b0>
 20. Whaley AL, Berry DJ, Harmsen WS. Extra-large uncemented hemispherical acetabular components for revision total hip arthroplasty. *J Bone Joint Surg Am.* 2001;83(9):1352-1357. doi:<https://doi.org/10.2106/00004623-200109000-00010>
 21. Berry DJ, Sutherland CJ, Trousdale RT, et al. Bilobed oblong porous coated acetabular components in revision total hip arthroplasty. *Clin Orthop Relat Res.* 2000;371:154-160. doi:<https://doi.org/10.1097/00003086-200002000-00019>
 22. Pagnano W, Hanssen AD, Lewallen DG, Shaughnessy WJ. The effect of superior placement of the acetabular component on the rate of loosening after total hip arthroplasty. *J Bone Joint Surg Am.* 1996;78(7):1004-1014. doi:<https://doi.org/10.2106/00004623-199607000-00004>
 23. Dearborn JT, Harris WH. High placement of an acetabular component inserted without cement in a revision total hip arthroplasty. Results after a mean of ten years. *J Bone Joint Surg Am.* 1999;81(4):469-480. doi:<https://doi.org/10.2106/00004623-199904000-00004>
 24. DeBoer DK, Christie MJ, Brinson MF, Morrison JC. Revision total hip arthroplasty for pelvic discontinuity. *J Bone Joint Surg Am.* 2007;89(4):835-840. doi:<https://doi.org/10.2106/JBJS.F.00313>
 25. Holt GE, Dennis DA. Use of custom triflanged acetabular components in revision total hip arthroplasty. *Clin Orthop Relat Res.* 2004;429:209-214. doi:<https://doi.org/10.1097/01.blo.0000150252.19780.74>
 26. Beckmann NA, Weiss S, Klotz MC, Gondan M, Jaeger S, Bitsch RG. Loosening after acetabular revision: comparison of trabecular metal and reinforcement rings. A systematic review. *J Arthroplasty.* 2014;29(1):229-235. doi:<https://doi.org/10.1016/j.arth.2013.04.035>
 27. Goriainov V, Jones A, Briscoe A, New A, Dunlop D. Do the cup surface properties influence the initial stability? *J Arthroplasty.* 2014;29(4):757-762. doi:<https://doi.org/10.1016/j.arth.2013.07.007>
 28. Jauregui JJ, Banerjee S, Cherian JJ, Elmallah RK, Pierce TP, Mont MA. Early Outcomes of Titanium-Based Highly-Porous Acetabular Components in Revision Total Hip Arthroplasty. *J Arthroplasty.* 2015;30(7):1187-1190. doi:<https://doi.org/10.1016/j.arth.2015.02.013>
 29. Eachempati KK, Malhotra R, Pichai S, et al. Results of trabecular metal augments in Paprosky IIIA and IIIB defects: A multicentre study. *Bone Joint J.* 2018;100-B(7):903-908. doi:<https://doi.org/10.1302/0301-620X.100B7.BJJ-2017-1604.R1>
 30. Loppini M, Schiavi P, Rocca AD, et al. Double-trabecular metal cup technique for the management of Paprosky type III defects without pelvic discontinuity. *Hip Int.* 2018;28(2_suppl):66-72. doi:<https://doi.org/10.1177/1120700018813208>
 31. Jenkins DR, Odland AN, Sierra RJ, Hanssen AD, Lewallen DG. Minimum Five-Year Outcomes with Porous Tantalum Acetabular Cup and Augment Construct in Complex Revision Total Hip Arthroplasty. *J Bone Joint Surg Am.* 2017;99(10):e49. doi:<https://doi.org/10.2106/JBJS.16.00125>
 32. Ji B, Li G, Zhang X, Wang Y, Mu W, Cao L. Multicup reconstruction technique for the management of severe protrusion acetabular defects. *Arthroplasty.* 2021;3(1):26. doi:<https://doi.org/10.1186/s42836-021-00081-9>
 33. Webb JE, McGill RJ, Palumbo BT, Moschetti WE, Estok DM. The Double-Cup Construct: A Novel Treatment Strategy for the

- Management of Paprosky IIIA and IIIB Acetabular Defects. *J Arthroplasty*. 2017;32(9S):S225-S231. doi:<https://doi.org/10.1016/j.arth.2017.04.017>
34. Clement RG, Ray AG, MacDonald DJ, Wade FA, Burnett R, Moran M. Trabecular Metal Use in Paprosky Type 2 and 3 Acetabular Defects: 5-Year Follow-Up. *J Arthroplasty*. 2016;31(4):863-867. doi:<https://doi.org/10.1016/j.arth.2015.10.033>
 35. Grappiolo G, Loppini M, Longo UG, Traverso F, Mazzotta G, Denaro V. Trabecular Metal Augments for the Management of Paprosky Type III Defects Without Pelvic Discontinuity. *J Arthroplasty*. 2015;30(6):1024-1029. doi:<https://doi.org/10.1016/j.arth.2015.01.001>
 36. O'Neill CJ, Creedon SB, Brennan SA, et al. Acetabular Revision Using Trabecular Metal Augments for Paprosky Type 3 Defects. *J Arthroplasty*. 2018;33(3):823-828. doi:<https://doi.org/10.1016/j.arth.2017.10.031>
 37. Moore MS, McAuley JP, Young AM, Engh CA, Sr. Radiographic signs of osseointegration in porous-coated acetabular components. *Clin Orthop Relat Res*. 2006;444(176-183). doi:<https://doi.org/10.1097/01.blo.0000201149.14078.50>