



Case Report

REHABILITATION OF A SEVERELY ATROPHIC MAXILLA USING IMMEDIATELY LOADED ZYGOMATIC IMPLANTS PLACED WITH PIEZOELECTRIC PREPARATION OF THE IMPLANT TUNNEL

R. Pistilli¹, C. Barausse², L. Bonifazi², G. Pellegrino², S. Tayeb², C. Angelino² and P. Felice²

¹Oral and Maxillofacial Unit, San Camillo Hospital, Rome, Italy;

²Department of Biomedical and Neuromotor Sciences, University of Bologna, Bologna, Italy

Correspondence to:

Pietro Felice MD, DDS, PhD
Department of Biomedical and Neuromotor Sciences,
Unit of Oral Surgery,
Alma Mater Studiorum,
University of Bologna,
Via San Vitale, 59
40120 Bologna - Italy
e-mail: pietro.felice@unibo.it

ABSTRACT

A surgical approach to implant site preparation in the rehabilitation of an atrophic maxilla with immediately loaded zygomatic implants is described. A 60-year-old systemically healthy female with severe maxillary atrophy was treated with immediately loaded zygomatic implants, placed after preparing the implant site with a piezoelectric device. Two different types of piezoelectric inserts were used to make the procedure safer. Wound healing was uneventful. There was no paraesthesia or neurological damage, and postoperative edema was minimal. Clinical and radiographic examinations showed the success of prosthetic rehabilitation from both the functional and esthetic points of view.

KEYWORDS: *maxillary atrophy, immediate loading, zygomatic implants, piezoelectric*

INTRODUCTION

The rehabilitation of patients with severely atrophied maxillae is challenging because of the complexity of the situation for implant placement. The problem is due to the lack of height and width of the alveolar ridge as a result of insufficient bone due to resorption, trauma, infection, and resective oncological surgery. These people have more problems in adapting to conventional dentures because of the lack of retention, so several surgical techniques have been developed to increase bone volume: guided bone regeneration (GBR) procedures (1), onlay (2-6), Le Fort I with interpositional grafting (7, 8), and sinus augmentation (9-11). However, the number of complications and failures with these augmentation procedures is still too high (well over 20%) to recommend their widespread use (5).

One solution may be to accept the lack of direct bone availability within the maxilla and instead use tilted implants in the parasinus region (12, 13), implants in the pterygoid apophysis (14), short implants (15, 16), and zygomatic

Received: 29 April 2024
Accepted: 04 June 2024

ISSN 2975-1276 [online]

Copyright © by BIOLIFE 2024

This publication and/or article is for individual use only and may not be further reproduced without written permission from the copyright holder. Unauthorized reproduction may result in financial and other penalties. Disclosure: All authors report no conflicts of interest relevant to this article.

implants. Zygomatic implants, introduced by Brånemark in 1988 (17), can be inserted using five surgical approaches, depending on the anatomical configuration:

- 1) the 'classical' approach (18, 19);
- 2) the sinus slot technique (20, 21);
- 3) the exteriorized approach (22);
- 4) the minimally invasive approach, using custom-made drill guides (23);
- 5) the computer-aided surgical navigation system approach (24, 25).

Prospective studies have shown that zygomatic implants can be used successfully for the rehabilitation of patients with extreme maxillary atrophy, also with immediate loading, with survival rates from 71 to 100% (19, 21).

However, the placement of zygomatic implants requires experienced surgeons; it is not risk-free because delicate anatomical structures, such as the orbit and brain, may be involved, especially during implant site preparation with drills (26). Ultrasonic osteotomy allows precise and effective bone cutting without damaging adjacent soft tissues. Thus, piezoelectric devices, used widely in traditional oral implantology (27, 28), may also be useful in zygomatic implant surgery to reduce surgical risks, complications, and morbidity.

In this case report, we describe a surgical approach to rehabilitation in a case of severe maxillary atrophy with four immediately loaded zygomatic implants placed using a piezoelectric device for implant site preparation.

CASE REPORT

A 60-year-old systemically healthy female was referred for a fixed prosthetic rehabilitation of a totally edentulous maxilla.

Surgical planning

On clinical examination, there was an important loss of the "Vertical Dimension of Occlusion" (VDO) extra-orally and an upper jaw with a bony crest that was very thin, vertically resorbed, and irregular intra-orally (Fig. 1).

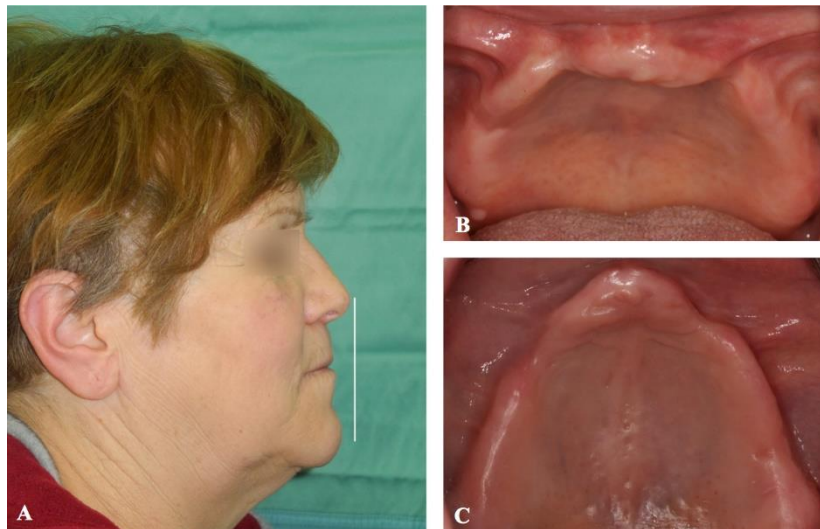


Fig. 1. (A) Pre-operative extra-oral clinical situation revealing an important loss of the "vertical dimension of occlusion" (VDO; white line); pre-operative intra-oral clinical photographs showing the upper jaw bone resorption. (B) Vestibular aspect. (C) Occlusal aspect.

A preliminary radiographic study [Orthopantomography (OPT) and Cone-Beam Computed Tomography (CBCT)] and a three-dimensional stereolithographic model revealed severe maxillary atrophy (class IV, according to Cawood and Howell (Fig. 2).

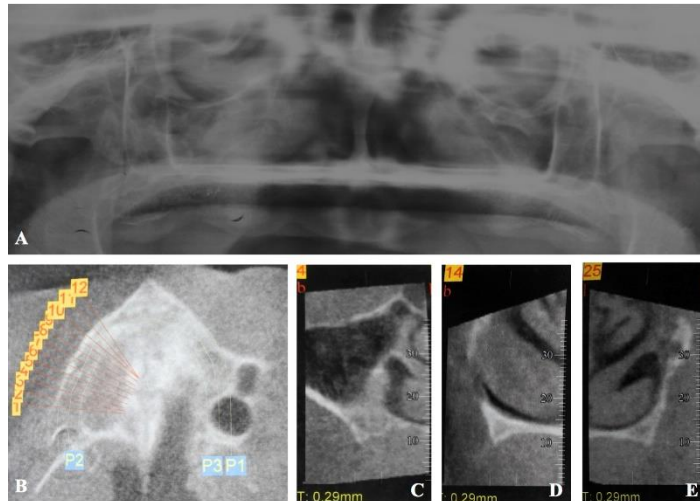


Fig. 2. Pre-operative Orthopantomography (OPG) (A) and CBCT series revealing bone atrophy (Cawood and Howell class IV). (B) axial section. (C) section 4 (right maxilla). (D) section 14 (pre-maxilla). (E) section 25 (left maxilla).

CBTC sections showed a mean residual bone height of 7 mm and a mean residual bone width of 1.5 mm. This major and irregular atrophy, due to the early loss of teeth due to periodontal disease (the patient had been wearing a complete removable denture for 15 years), did not allow conventional implant placement and made successful reconstructive and regenerative surgery difficult. Consequently, since the patient requested prosthetic rehabilitation in the shortest possible time without extraoral donor sites, placing implants anchored in the zygomatic bone was suggested.

The requirements of the Declaration of Helsinki were observed. The patient gave written informed consent for all surgical procedures.

Zygomatic implant placement

One hour before the beginning of the surgery, the patient performed rinses for 60 s with 15 mL of a solution of chlorhexidine gluconate 0.12% and was given amoxicillin plus clavulanic acid (2.2 g, intravenously; Augmentin, GSK Pharma, Brentford, UK). Surgery planned using the stereolithographic model was performed under general anesthesia with rhino-tracheal intubation. An incision in the soft tissue along the entire maxillary crest, from the right tuber maxillae to the left, was first drawn with a dermographic marker and then made with a scalpel; three relieving incisions, one central and two distal, were also made. Then, the soft tissue was reflected entirely from the maxillary crest to the zygomatic buttress along the infrazygomatic crest, and the suborbital nerve was identified. The exposure was extended around the base of the piriform rim; the nasal mucosa was dissected to increase visibility and provide a detailed picture of the local anatomy. Anterior fibers of the masseter muscle were dissected for ~1 cm, and the Bichat's fat pad was exposed (Fig. 3A).

Sinus windows were drawn bilaterally with a sterile pencil in relation to the axis of implant placement. Then, the windows were opened using a round bur in the uppermost lateral aspect of the sinus wall. The Schneiderian membranes were then reflected. The windows provided direct visibility of the roof of the sinus and enabled localization of the optimal point for implant entrance (Fig. 3B). The proper implant axis, drawn on the bone with a sterile pencil, was a path that extended from the premolar region through the maxillary sinus, entering the midportion of the zygomatic body.

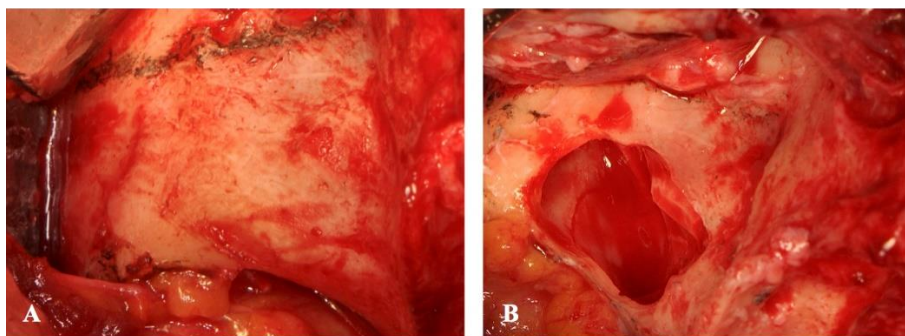


Fig. 3. Exposure extension to the right zygomatic buttress (A); right maxillary sinus window, opened in the uppermost lateral aspect of the sinus wall. The Schneiderian membrane has been reflected (B).

In this case, the implant tunnel was prepared with a piezoelectric device (Esacrom S.r.l., Imola, Bologna, Italy). It was used with two different piezoelectric inserts (Esacrom S.r.l.) with double internal irrigation, having a total length of 90 mm with a first angled part and a straight part (Fig. 4). The two inserts differ in terms of tip shape: conical (2.9-mm diameter) with micro-sharp blades (Fig. 4A) or diamond-shape (3.5-mm diameter) with blades (Fig. 4B). These zygomatic inserts were manufactured from medical stainless steel with T-black finishing, obtained with a double-coated nanostructure surface treatment that allows heating tissue reduction and has greater resistance to wear and corrosion.

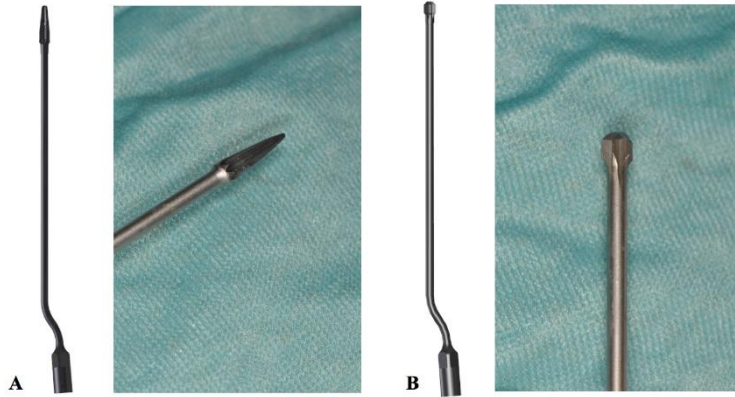


Fig. 4. Piezoelectric inserts, 90 mm long, manufactured from medical stainless steel with T-black finishing. (A) conical tip shape (2.9-mm diameter). (B) diamond tip shape (3.5-mm diameter).

The conical-shaped tip insert was used to prepare the implant tunnel. It was inserted in the residual alveolar bone and was then taken out at the base of the sinus window; in this way, the implant had an endosseous path also at the level of the atrophic crest, providing better primary stability (Fig. 5A). Subsequently, the tip of this insert, due to its length, passing through the maxillary sinus, entered the midportion of the zygomatic body and came out from the zygomatic malar face (Fig. 5B). During this critical phase, the piezoelectric device can be particularly useful in minimizing the risk of damage to the edge of the orbit, reducing the rate of periorbital hematomas and orbital injuries.

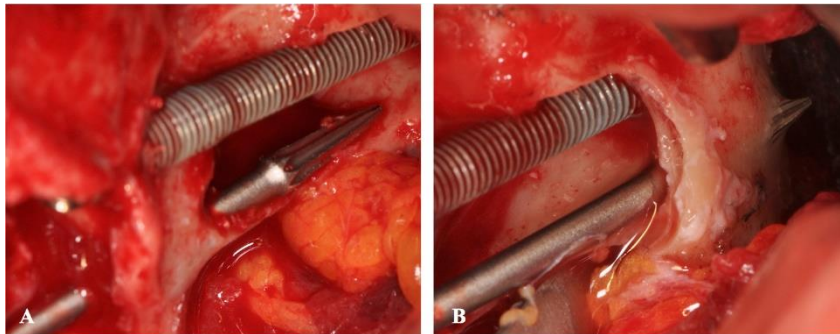


Fig. 5. Conical-shaped tip insertion in the left residual alveolar bone to improve implant stability (A), and the tip of the conical-shaped insert coming out from the left zygomatic malar face (B).

The diamond-shaped tip insert was then used to widen the tunnel to the desired size (3.5 mm) in relation to the implant diameter (4 mm) (Fig. 6). A depth indicator was then inserted into the site to determine the correct length of the zygoma fixture.

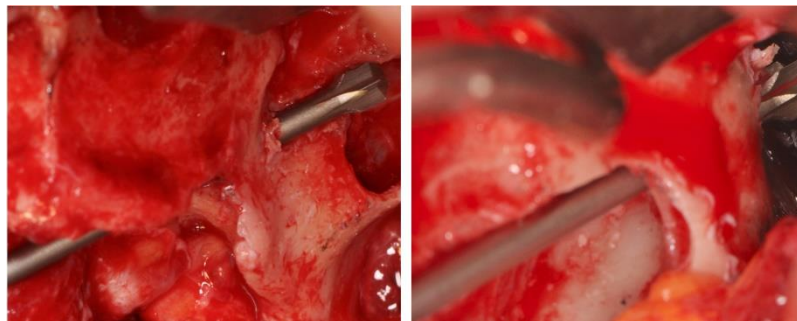


Fig. 6. Diamond-shaped tip insert used to widen the tunnel preparation.

Four zygomatic implants (Zygoma TiUnite Implant Brånemark System, Nobel Biocare AB, Goteborg, Sweden) with a 45° angulated head were used. Posteriorly, two implants (42.5 × 4 mm and 45 × 4 mm) were placed, one on each side, and two more implants (40 × 4 mm) were placed anteriorly, one on each side (Fig. 7).

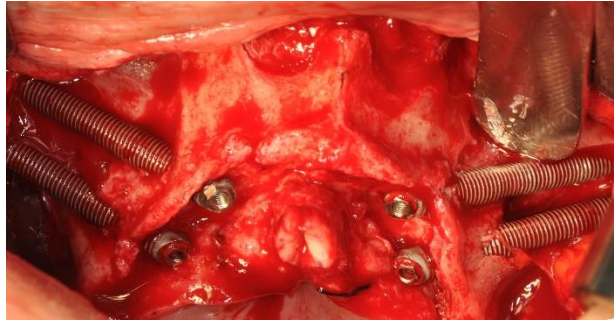


Fig. 7. Four zygomatic implants were placed. Posteriorly, two implants (42.5 × 4 mm and 45 × 4 mm) were placed, one on each side, and two more implants (40 × 4 mm) were placed anteriorly, one on each side.

Implants were inserted slowly until their apical portion was anchored in the alveolar crest and then manually inserted to an adequate depth; the insertion torque was 40 Ncm at 20 rpm. The apical portion of the implant was embedded in ~8-10 mm of the zygomatic bone; if necessary, some threads had emerged from the bone body for better stability. The zygomatic implants were positioned in the premolar and molar zones.

Prosthetic phases

We connected the 17° angled multi-unit abutments, 3 mm high (Zygoma 17° Multi-unit Abutment Brånemark System) to the implants. Because the implant insertion torque was greater than 35 Ncm, an immediate-loading protocol was initiated, and pick-up transfers were positioned. Bichat's fat pads, rich in pluripotent cells, were gently shifted medially to cover the exposed implant threads to ensure better healing. Tissues were then sutured with simple interrupted 4-0 resorbable sutures (Vicryl, Ethicon FS-2, Johnson & Johnson, New Brunswick, NJ) and self-curing acrylic resin (Pattern Resin, GC, Alsip, IL, USA), positioned on a brass wire, was used to secure abutment transfers in position (Fig. 8A). A pick-up impression was then completed using a polyester material (Impregum, 3M ESPE, Pioltello, Milan, Italy); the previous prosthesis, with a hole in the resin palate, was used as the tray and healing caps were then positioned (Fig. 8B). The postoperative pharmacological therapy was then established: 2.2 g of amoxicillin plus clavulanic acid (Augmentin) and 500 mg of metronidazole, twice per day for 5 days, intravenously, omeprazole once per day in the evening for 5 days, Bentelan (Biofutura Pharma S.p.A., Rome, Italy) 4 mg on the evening after surgery, 3 mg the day after, 2 mg 2 days after, and 1 mg 3 days after surgery. The patient was also recommended to perform gentle rinses for 60 s with 15 mL of chlorhexidine gluconate 0.12% twice daily. The provisional prosthesis, prepared in acrylic resin and reinforced with a titanium structure, was delivered 24 h after the surgery (Fig. 8C).

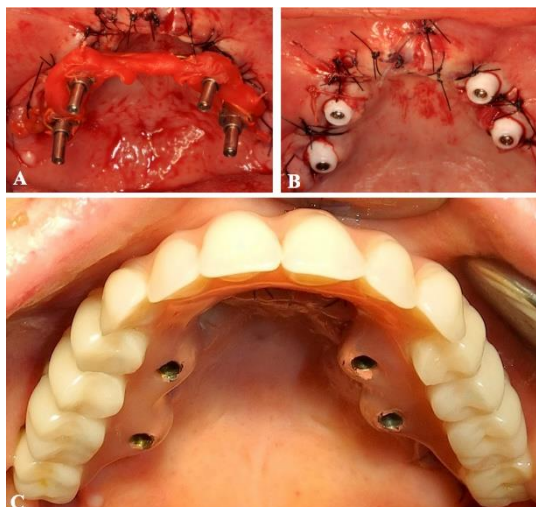


Fig. 8. Self-curing acrylic resin, positioned on a brass wire, used to secure the abutment transfer position for the pick-up impression (A) and healing cap positioning after the pick-up impression (B). Provisional prosthesis delivered 24 h after the surgery (C).

The patient was monitored clinically at 6, 12, 21, and 28 days after surgery and then up to 4 months. The radiographic control was performed 48 h after surgery (Fig. 9).

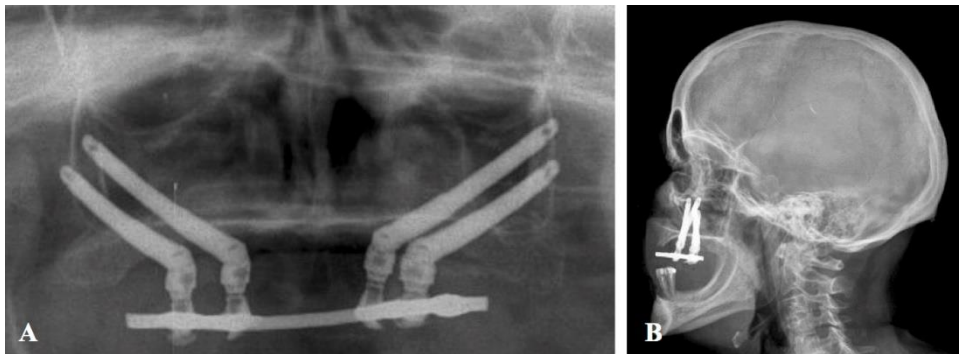


Fig. 9. Post-operative OPG (A) and latero-lateral telerradiography (B).

Sutures were removed after 12 days. The postoperative course and wound healing were uneventful. There was no paraesthesia or neurological damage, and postoperative edema was minimal (Fig. 10).

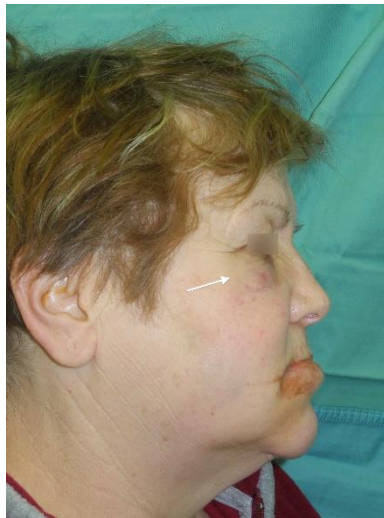

Fig. 10. Extra-oral clinical situation 24 h after surgery. Note minimal postoperative edema (*arrow*).

Clinical and radiographic controls showed the success of the prosthetic rehabilitation from both functional and esthetic perspectives.

DISCUSSION

The evolution of osseointegrated implant concepts has been enhanced significantly with implant support from osseous sites in remote locations, such as zygomatic bone (29). Zygomatic implants offer an interesting alternative solution to heavy bone grafting and to other surgical techniques in the severely resorbed maxilla (1-11). Their advantages include interventions for bone harvesting and placing grafts, which have high rates of complications and failures (19, 21), which are avoided. Moreover, patients are treated with a fixed denture much sooner. Zygomatic implants have been used for more than 10 years, with survival rates from 71 to 100% (19, 21), and give predictable outcomes in the rehabilitation of totally edentulous patients (30). In the literature, 12 studies have evaluated the use of these implants with immediate-function protocols (26). The high survival rates reported in these studies (95.8-100%) indicate that they can be used this way with initial implant stability. With immediate occlusal loading, the morbidity and treatment time can be decreased substantially, and patient acceptance can be increased (31).

However, some problems related to zygomatic implants have been reported, including infections in the maxillary sinus, intraoral soft tissue problems, oroantral fistula formation, periorbital hematoma, orbital injury, temporary sensory nerve deficits, moderate nasal bleeding for 1-3 days, and inadvertent intracranial penetration. Many of these problems occur during or as a consequence of using drills to prepare the implant tunnel. Drills are very aggressive and sometimes

difficult to control in cutting, leading to complications and a more disabling postoperative period. For these reasons, we considered using a piezoelectric device with dedicated inserts.

Ultrasonic osteotomy allows precise and effective bone cutting without damaging adjacent soft tissues. This approach is based on micro-vibrations (25-30 kHz) created by the piezoelectric effect (32). Histological and histomorphometric analyses of wound healing and bone formation have shown that hard tissue responses to ultrasound cutting are more favorable than conventional drills (33). The beneficial effect of a piezoelectric device on bone healing is well-established and has been used in maxillofacial and oral surgery (32).

Recently, ultrasound has been used in oral surgery for implant site preparation with excellent results in terms of complications and implant survival rate (97.7%, with follow-up of 1-3 years) (34). Based on these data, we used specific piezoelectric inserts to prepare the implant tunnel sites for placing zygomatic implants. This approach could have several advantages in relation to traditional surgery:

- 1) more precise and secure tunnel preparation;
- 2) better osseointegration (35) because of the micro-vibrations that increase the release of free bone morphogenetic proteins (BMP) and cause cell stimulation (36);
- 3) a lower risk of surgical complications, such as neurological damage, periorbital hematoma, orbital injury, and intracranial penetration;
- 4) better intraoperative visibility (micro-vibrations generate cavitation of liquids, increasing detergent action);
- 5) better control of the tool;
- 6) less pain and swelling after the surgery. In any case, the placement of zygomatic implants requires highly experienced surgeons. A potential disadvantage of this new method is the lengthening of the operative time, which we noted.

CONCLUSIONS

In conclusion, this approach could be safer and more accurate within the limits of a case report. However, further research is needed to confirm its potentially advantageous properties compared to the traditional method.

REFERENCES

1. Simion M, Jovanovic SA, Tinti C, Benfenati SP. Long-term evaluation of osseointegrated implants inserted at the time or after vertical ridge augmentation. A retrospective study on 123 implants with 1-5 year follow-up. *Clinical Oral Implants Research*. 2001;12(1):35-45. doi:https://doi.org/10.1034/j.1600-0501.2001.012001035.x
2. Chiapasco M, Zaniboni M, Rimondini L. Autogenous onlay bone grafts vs. alveolar distraction osteogenesis for the correction of vertically deficient edentulous ridges: a 2?4-year prospective study on humans. *Clinical Oral Implants Research*. 2007;18(4):432-440. doi:https://doi.org/10.1111/j.1600-0501.2007.01351.x
3. Chiapasco M, Casentini P, Zaniboni M. Bone augmentation procedures in implant dentistry. *The International Journal of Oral & Maxillofacial Implants*. 2009;24 Suppl:237-259.
4. Donos N, Mardas N, Chadha V. Clinical outcomes of implants following lateral bone augmentation: systematic assessment of available options (barrier membranes, bone grafts, split osteotomy). *Journal of Clinical Periodontology*. 2008;35:173-202. doi:https://doi.org/10.1111/j.1600-051x.2008.01269.x
5. Esposito M, Grusovin MG, Felice P, Karatzopoulos G, Worthington HV, Coulthard P. Interventions for replacing missing teeth: horizontal and vertical bone augmentation techniques for dental implant treatment. *Cochrane Database of Systematic Reviews*. 2009;7. doi:https://doi.org/10.1002/14651858.cd003607.pub4
6. Jacotti M, Barausse C, Felice P. Posterior Atrophic Mandible Rehabilitation With Onlay Allograft Created With CAD-CAM Procedure. *Implant Dentistry*. 2014;23(1):22-28. doi:https://doi.org/10.1097/id.0000000000000023
7. Chiapasco M, Brusati R, Ronchi P. Le Fort I osteotomy with interpositional bone grafts and delayed oral implants for the rehabilitation of extremely atrophied maxillae: a 1?9-year clinical follow-up study on humans. *Clinical Oral Implants Research*. 2007;18(1):74-85. doi:https://doi.org/10.1111/j.1600-0501.2006.01287.x
8. Marchetti C, Felice P, Lizio G, Rossi F. Le Fort I Osteotomy With Interpositional Graft and Immediate Loading of Delayed Modified SLActive Surface Dental Implants for Rehabilitation of Extremely Atrophied Maxilla: A Case Report. *Journal of Oral and Maxillofacial Surgery*. 2009;67(7):1486-1494. doi:https://doi.org/10.1016/j.joms.2009.03.020
9. Stern A, Green J. Sinus lift procedures: an overview of current techniques. *Dental Clinics of North America*. 2012;56(1):219-233, x. doi:https://doi.org/10.1016/j.cden.2011.09.003
10. Esposito M, Maria Gabriella Grusovin, Rees J, et al. Effectiveness of sinus lift procedures for dental implant rehabilitation: a Cochrane systematic review. *European Journal of Oral Implantology*. 2010;3(1):7-26.
11. Esposito M, Felice P, Worthington HV. Interventions for replacing missing teeth: augmentation procedures of the maxillary sinus. *Cochrane Database of Systematic Reviews*. 2014;17.

- doi:<https://doi.org/10.1002/14651858.cd008397.pub2>
12. Calandriello R, Tomatis M. Simplified Treatment of the Atrophic Posterior Maxilla via Immediate/Early Function and Tilted Implants: A Prospective 1-Year Clinical Study. *Clinical Implant Dentistry and Related Research*. 2005;7(s1):s1-s12. doi:<https://doi.org/10.1111/j.1708-8208.2005.tb00069.x>
 13. Maló P, Nobre, Lopes A. Immediate Loading of “All-on-4” Maxillary Prostheses Using Trans-Sinus Tilted Implants Without Sinus Bone Grafting: A Retrospective Study Reporting the 3-year Outcome. *Eur J Oral Implantol*. 2013;6(3):273-283.
 14. Balshi TJ, Wolfinger GJ, S F Balshi nd. Analysis of 356 pterygomaxillary implants in edentulous arches for fixed prosthesis anchorage. *The International journal of oral & maxillofacial implants*. 1999;14(3):398-406.
 15. Pistilli R, Felice P, Maurizio Piattelli, et al. Posterior atrophic jaws rehabilitated with prostheses supported by 5 x 5 mm implants with a novel nanostructured calcium-incorporated titanium surface or by longer implants in augmented bone. One-year results from a randomised controlled trial. *Eur J Oral Implantol*. 2013;6(4):343-357.
 16. Pistilli R, Felice P, Cannizzaro G, et al. Posterior atrophic jaws rehabilitated with prostheses supported by 6 mm long 4 mm wide implants or by longer implants in augmented bone. One-year post-loading results from a pilot randomised controlled trial. *European Journal of Oral Implantology*. 2013;6(4):359-372.
 17. Smalley WM, Shapiro PA, Hohl TH, Kokich VG, Brånemark PI. Osseointegrated titanium implants for maxillofacial protraction in monkeys. *American Journal of Orthodontics and Dentofacial Orthopedics*. 1988;94(4):285-295. doi:[https://doi.org/10.1016/0889-5406\(88\)90053-4](https://doi.org/10.1016/0889-5406(88)90053-4)
 18. Brånemark PI. *Surgery and Fixture Installation: Zygomaticus Fixture Clinical Procedures*. PART 1. Nobel Biocare AB; 1998.
 19. Malevez C, Abarca M, Durdu F, Daelemans P. Clinical outcome of 103 consecutive zygomatic implants: a 6-48 months follow-up study. *Clinical Oral Implants Research*. 2004;15(1):18-22. doi:<https://doi.org/10.1046/j.1600-0501.2003.00985.x>
 20. John Paul Stella, Warner MR. Sinus slot technique for simplification and improved orientation of zygomaticus dental implants: a technical note. *The International journal of oral & maxillofacial implants*. 2001;15(6):889-893.
 21. Davo R, Malevez C, Rojas J, Rodríguez J, Regolf J. Clinical outcome of 42 patients treated with 81 immediately loaded zygomatic implants: a 12- to 42-month retrospective study. *Eur J Oral Implantol*. 2008;1(2):141-150.
 22. Shihab Romeed, Malik R, Dunne S. Zygomatic Implants: The Impact of Zygoma Bone Support on Biomechanics. *Journal of Oral Implantology*. 2014;40(3):231-237. doi:<https://doi.org/10.1563/aaid-joi-d-11-00245>
 23. Van Steenberghe D, Malevez C, Van Cleynenbreugel J, et al. Accuracy of drilling guides for transfer from three-dimensional CT-based planning to placement of zygoma implants in human cadavers. *Clinical Oral Implants Research*. 2003;14(1):131-136. doi:<https://doi.org/10.1034/j.1600-0501.2003.140118.x>
 24. Ewers R, Schicho K, Undt G, et al. Basic research and 12 years of clinical experience in computer-assisted navigation technology: a review. *International Journal of Oral and Maxillofacial Surgery*. 2005;34(1):1-8. doi:<https://doi.org/10.1016/j.ijom.2004.03.018>
 25. Pellegrino G, Relics D, Tarsitano A, Basile F, Grande F, Marchetti C. Computer-assisted surgery in the rehabilitation of the upper jaw with zygomatic implants - a cohort study comparing atrophic and oncologic patients. Preliminary results at 4 years follow-up. *Clinical Oral Implants Research*. 2018;29:437-437. doi:https://doi.org/10.1111/clr.322_13358
 26. Chrcanovic BR, Abreu MHNG. Survival and complications of zygomatic implants: a systematic review. *Oral and Maxillofacial Surgery*. 2012;17(2):81-93. doi:<https://doi.org/10.1007/s10006-012-0331-z>
 27. Vercellotti T, Stacchi C, Russo C, et al. Ultrasonic Implant Site Preparation Using Piezosurgery: A Multicenter Case Series Study Analyzing 3,579 Implants with a 1- to 3-Year Follow-Up. *The International Journal of Periodontics & Restorative Dentistry*. 2014;34(1):11-18. doi:<https://doi.org/10.11607/prd.1860>
 28. Vercellotti T, De Paoli S, Nevins M. The piezoelectric bony window osteotomy and sinus membrane elevation: introduction of a new technique for simplification of the sinus augmentation procedure. *PubMed*. 2001;21(6):561-567.
 29. Parel SM, Brånemark PI, Ohnell LO, Svensson B. Remote implant anchorage for the rehabilitation of maxillary defects. *The Journal of Prosthetic Dentistry*. 2001;86(4):377-381. doi:<https://doi.org/10.1067/mp.2001.118874>
 30. Malevez C, Daelemans P, Adriaenssens P, Durdu F. Use of zygomatic implants to deal with resorbed posterior maxillae. *Periodontology 2000*. 2003;33(1):82-89. doi:<https://doi.org/10.1046/j.0906-6713.2002.03307.x>
 31. Davo R, Malevez C, Rojas J. Immediate function in the atrophic maxilla using zygoma implants: A preliminary study. *The Journal of Prosthetic Dentistry*. 2007;97(6):S44-S51. doi:[https://doi.org/10.1016/s0022-3913\(07\)60007-9](https://doi.org/10.1016/s0022-3913(07)60007-9)
 32. Eggers G, Klein J, Blank J, Hassfeld S. Piezosurgery®: an ultrasound device for cutting bone and its use and limitations in maxillofacial surgery. *British Journal of Oral and Maxillofacial Surgery*. 2004;42(5):451-453. doi:<https://doi.org/10.1016/j.bjoms.2004.04.006>
 33. Vercellotti T, Nevins ML, Kim DM, et al. Osseous response following resective therapy with piezosurgery. *Int J Periodontics Restorative Dent*. 2005;25(6):543-549.
 34. Stacchi C, Vercellotti T, Torelli L, Furlan F, Di Lenarda R. Changes in Implant Stability Using Different Site Preparation Techniques: Twist Drills versus Piezosurgery. A Single-Blinded, Randomized, Controlled Clinical Trial. *Clinical Implant Dentistry and Related Research*. 2011;15(2):188-197. doi:<https://doi.org/10.1111/j.1708-8208.2011.00341.x>

-
35. Preti G, Martinasso G, Peirone B, et al. Cytokines and growth factors involved in the osseointegration of oral titanium implants positioned using piezoelectric bone surgery versus a drill technique: a pilot study in minipigs. *Journal of Periodontology*. 2007;78(4):716-722. doi:<https://doi.org/10.1902/jop.2007.060285>
 36. Di Alberti L, Donnini F, Di Alberti C, Camerino M. A comparative study of bone densitometry during osseointegration: Piezoelectric surgery versus rotary protocols. *Quintessence International*. 2010;41(8):639-644.



INTRA-ORAL WELDING TECHNIQUE: THREE CASE REPORTS

L. Tomaselli

Correspondence to:

Luigi Tomaselli, DDS, MS

Private practice,

Via Azzurra 26,

40138 Bologna, Italy

e-mail: gigitomasellimail.com

ABSTRACT

In recent years, an intra-oral welding technique (IOWT) was introduced to allow immediate implant loading and transform a removable denture into a temporary full-arch rehabilitation. It is an evolutionary solution for implant-supported dentures in terms of function and cost. IOWT lets rigid connections among fixtures occur immediately after implant insertion by welding a titanium bar to connect abutments. The removable denture is adapted to the patient's oral cavity according to height, chewing, and speech. The titanium framework is immersed in the denture's inner part by resin. Finally, abutments are unscrewed, the denture removed, polished, and screwed again onto implants. This way, it is possible to immediately deliver a full arch rehabilitation after free-hand placing implants and transforming the patient's removable denture into a temporary full arch rehabilitation. Here, a case series is reported, and the literature is reviewed.

KEYWORDS: *intra-oral, welding, removable, denture, full-arch, rehabilitation, prosthesis*

INTRODUCTION

Implant-supported dentures are a modern and effective dental restoration option designed to provide enhanced stability and functionality compared to traditional removable dentures (1). This treatment involves securing a denture onto dental implants surgically placed in the jawbone. In this type of prosthetic rehabilitation, the denture is securely attached to the dental implants, preventing slippage and providing increased stability during activities such as chewing and speaking. Traditionally, there are two implant-supported dentures: bar-retained and ball-retained, also called locator dentures. The first type is a removable denture that attaches to a metal bar connected to the implants. In contrast, the second utilizes ball-shaped attachments on the implants that fit into corresponding sockets on the denture. Several are the benefits of implant-supported dentures. Among them are enhanced stability, improved chewing function, jawbone preservation, and natural feel. In fact, unlike traditional dentures, implant-supported dentures are securely anchored to implants, minimizing movement and slippage. The stability provided by dental implants allows for better chewing efficiency, enabling a more varied diet. Dental implants stimulate the jawbone, preventing bone loss and maintaining facial structure over time. In addition, implant-supported dentures closely mimic the feel and function of natural teeth, providing a more comfortable and confident experience for the wearer. Implant-supported dentures are an intermediate clinical and cost solution between removable dentures and full arch rehabilitation.

One critical point in implant osteointegration is micromovement (2, 3). Implant micromovement refers to the subtle, microscopic movements between the implant and the surrounding bone tissue. While some degree of

Received: 02 May 2024
Accepted: 31 May 2024

ISSN 2975-1276 [online]

Copyright © by BIOLIFE 2024

This publication and/or article is for individual use only and may not be further reproduced without written permission from the copyright holder. Unauthorized reproduction may result in financial and other penalties. Disclosure: All authors report no conflicts of interest relevant to this article.

micromovement is inevitable, excessive (around 80-100 micro-m) or continuous micromotion can hinder osseointegration (i.e., the biological process by which living bone tissue forms a bond with the surface of an implant). Excessive micromovement can lead to fibrous tissue formation instead of the desired direct bone-to-implant contact.

The relationship between implant micromovement and osteointegration is inverse - excessive micromovement can compromise or delay the osteointegration process. To promote optimal osteointegration, minimizing micromovement during the initial stages of implant healing is essential. Proper implant design, surgical techniques, patient-related factors, and overall loading conditions often achieve this. Immediate or early loading of implants (i.e., loading implant during peri-implant bone healing) can impact micromovement and must be carefully considered in the treatment plan.

A rigid connection between implants is a generally accepted solution to reduce implant micromovement, especially during the peri-implant bone healing period (i.e., 3 months). Welded titanium framework is a well-known solution produced in a laboratory to strengthen prosthetic rehabilitation (4-8).

In recent years, an intra-oral welding technique (IOWT) was introduced to let immediate implant loading (9-26) and transform a removable denture in a temporary full-arch rehabilitation. It is an evolutionary solution for implant-supported dentures in terms of function and cost. IOWT lets rigid connections occur immediately after implant insertion by welding a titanium bar to connect the abutments. The removable denture is adapted to the patient's oral cavity according to height, chewing, and speech habits. The titanium framework is immersed in the denture's inner part by resin. Finally, abutments are unscrewed, dentures removed, polished, and screwed again onto implants. In this way, it is possible to immediately deliver a full arch rehabilitation after free-hand placing implants and transforming the patient's removable denture into a temporary full arch rehabilitation. Here, a case series is reported, and the literature is reviewed.

CASE REPORT

Case 1

The patient presented to our clinic complaining about his smile in 2021. She was 58 years old and was a smoker. At the clinical and radiological evaluation, she had severe atrophy due to endo-perio infections that caused resorption and dehiscence of the vestibular bone and multi-focal fenestrations in the upper jaw (Fig. 1). The patient asked for a definitive fixed solution with a pleasant aesthetic.

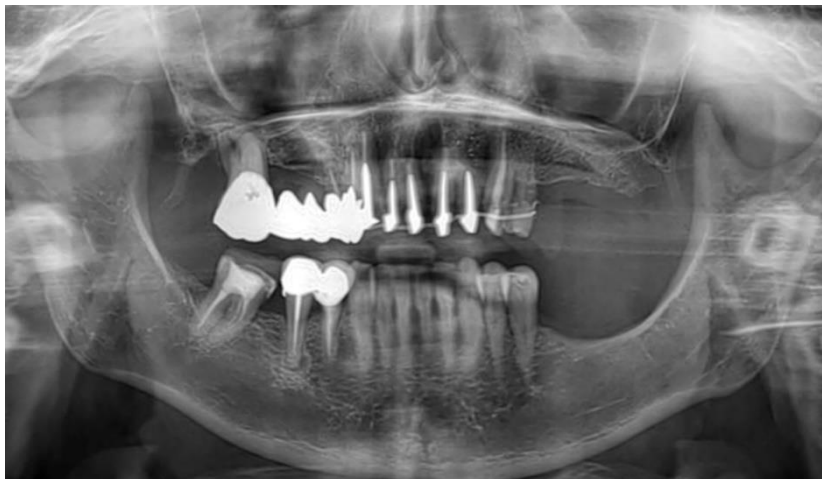

Fig. 1. *Orthopantomography.*

Multiple extractions and bone defects were cleaned using granulation tissue and granulomas. Thus, an alveolar ridge poor in hard tissue but free of infections was obtained (Fig. 2).

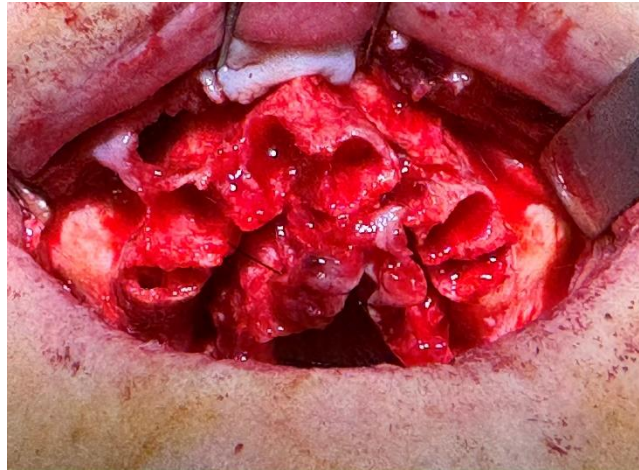


Fig. 2. *Surgical view of maxilla after teeth extraction.*

The two pterygoid implants were inserted, and thanks to the engagement of the laminae of the pyramidal process, a torque of 90N was obtained despite the alveolar bone's D4 quality.

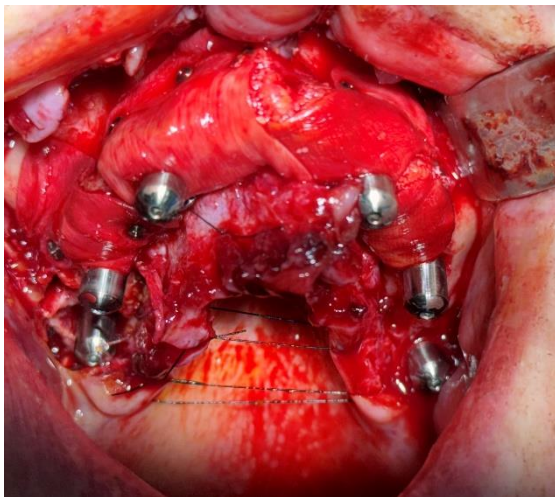


Fig. 3. *Implant insertion and bone regeneration.*

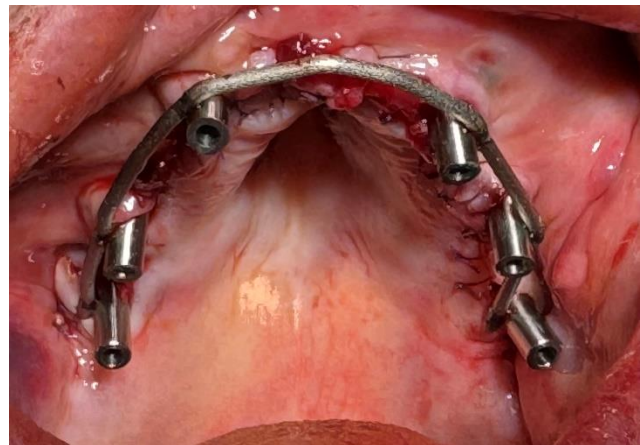


Fig. 4. *Titanium bar welded to abutments.*

Four implants were inserted in the premaxilla. After an abundant harvest of autologous bone, to create a 50/50 autologous/heterologous bone mix, GBRs were performed to repair bone defects, covering the exposed threads of the newly inserted implants. Titanium pins were positioned to create tension and stability of resorbable membranes that contain bone grafts. Mucosa was sutured by primary intention, and then intraoral welding was performed (Fig. 3, 4). An all-on-six in PMMA was delivered, with the structure welded inside (Fig. 5). At the end of the rehabilitation procedure, an X-ray check was performed (Fig. 6). The follow-up was uneventful; after 32 months, the patient had no complications.

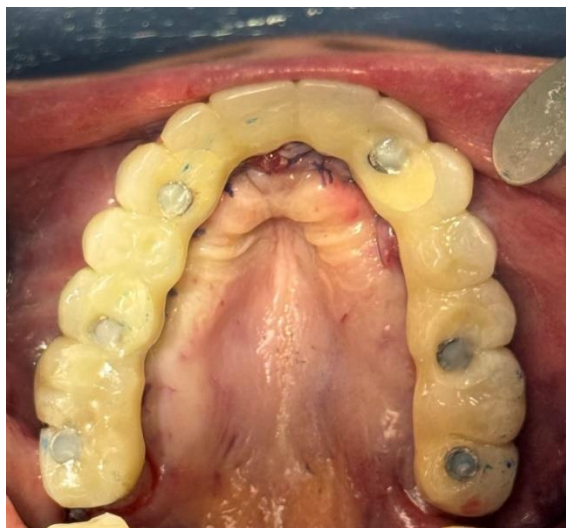

Fig. 5. *Provisional rehabilitation.*

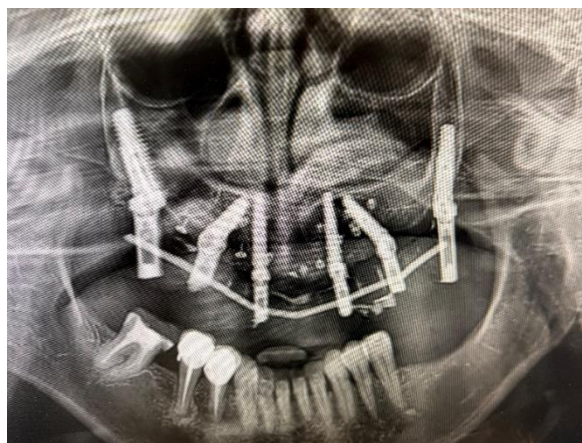

Fig. 6. *Post-surgical orthopantomography.*

Case 2

The patient presented to our clinic and complained about his chewing in 2021. He was 40 years old and was a smoker. At clinical and radiological evaluation, he has severe periodontitis and bone loss. He asked for an immediate prosthetic rehabilitation. A bi-max rehabilitation was planned by using 12 implants. Clinically, the transversal maxillary dimension was reduced due to bone defects, and a long cantilever would be necessary to give the patients 12 teeth per arch. The cantilever was avoided by planning two pterygoid implants, which reduced the stress of the distal implant in the premaxilla and gave the patient 14 teeth per arch. Primary stability was excellent. The heterologous graft was used just to fulfill post-extraction sockets. Immediate loading was done with no complications, and six months post-operative X-rays showed the bone defect correctly ossified around implants (Fig. 1-6). Definitive restoration was delivered after 6 months, and the 2-year follow-up X-rays showed good bone peak and corticalization of the inter-implant areas.

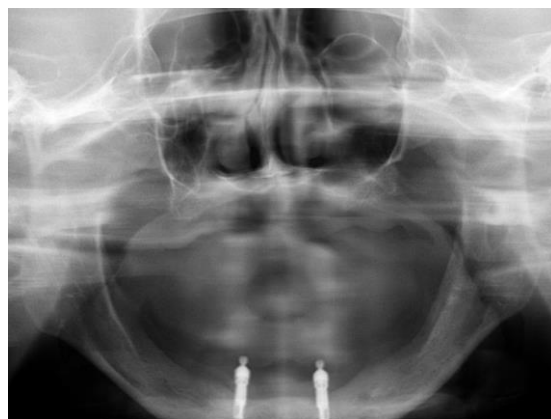


Fig. 1. *Pre-surgical orthopantomography.*

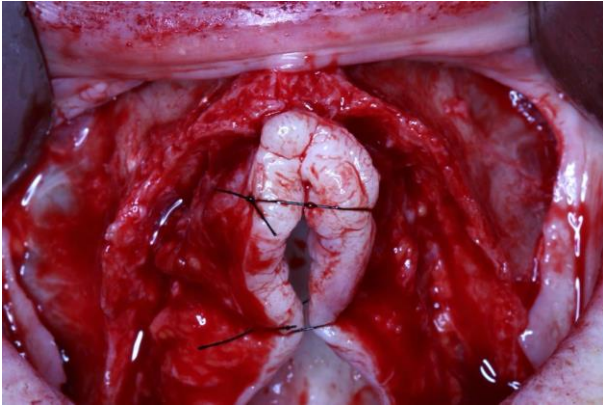


Fig. 2. *Surgical view of maxillary atrophy.*

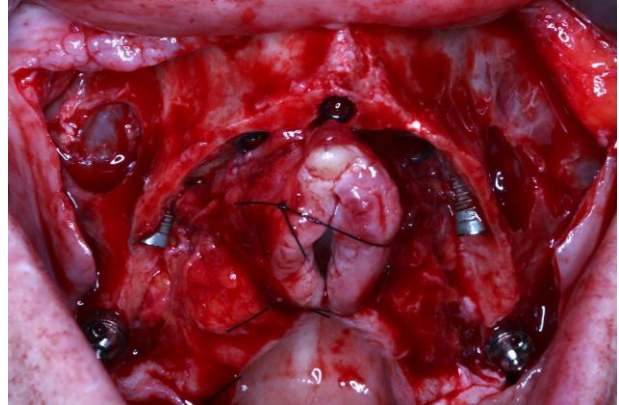


Fig. 3. *Implant inserted.*

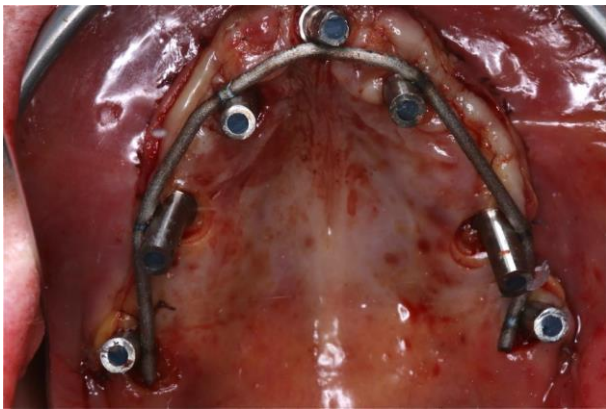


Fig. 4. *Titanium bar welded to abutments.*

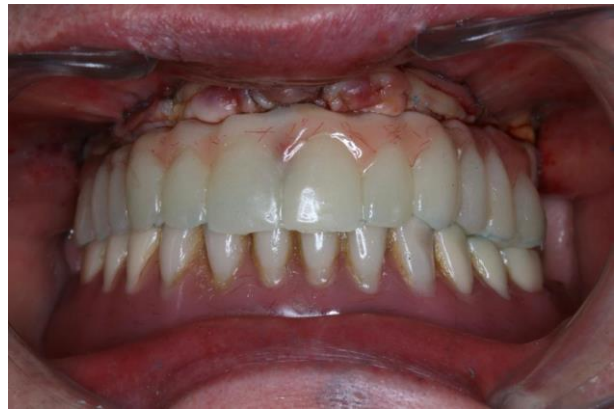

Fig. 5. *Provisional Restoration.*

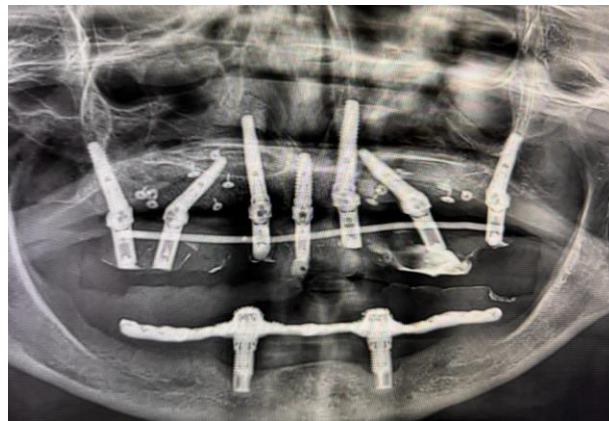

FIG. 6. *Post-surgical orthopantomography.*

Case 3

The patient, who was 75 years old and a nonsmoker, presented to our clinic in 2022 complaining about his chewing. At the clinical and radiological evaluation, he had severe bone ridge infections due to endo-perio diseases. In addition, radicular cysts and bilateral oro-antral communication were seen, as well as sinusitis of the right maxillary sinus (Fig. 1).

Surgically, after loco-regional anesthesia, extraction of teeth, and accurate cleaning of infected sockets and fenestrations, a full-thickness flap was elevated with two distal releases on the zygomatic pillar. Both sinuses were opened and cleaned from the infection, washed with Rifamicin 250mg, and the Schneiderian membrane was sutured with 6.0 resorbable stitches. Due to the reduced mouth opening of the patient, pterygoid implants were inserted as the first procedure. The right pterygoid implant was a trans-sinus fixture that engaged the tuberosity from the interior of the sinus

and then the pterygoid laminae. This implant was inserted 1 mm into the pterygoid bone crest, and it reached 70 N torque. No graft was placed in the right sinus due to the strong infection. Then, the left pterygoid fixture was inserted with no major difficulties. The left distal implant in the premaxilla was a trans-sinus. A vertical bone defect was fulfilled with a 50/50 heterologous/autogenous graft. Autologous bone and tuberosity were harvested from the zygomatic pillar. Here, there was an oro-antral communication without infection in the sinus. The remaining implants were inserted in the premaxilla, abutments were welded (Fig. 2), and an immediate loading was done (Fig. 3-5). The Toronto bridge did not have a ridge reconstruction to make the prostheses easily cleanable for the patient. A check done 3 weeks after surgery confirmed a good healing process. X-ray and clinical control after one year confirmed a follow-up without complications (Fig. 6, 7).

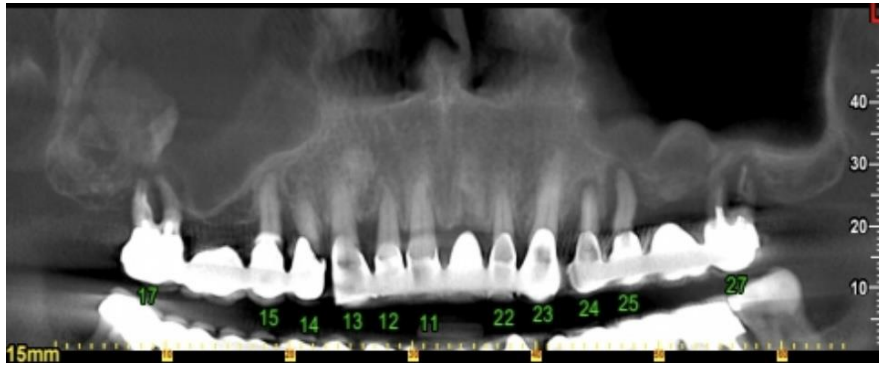

Fig. 1. Pre-operative X-ray.

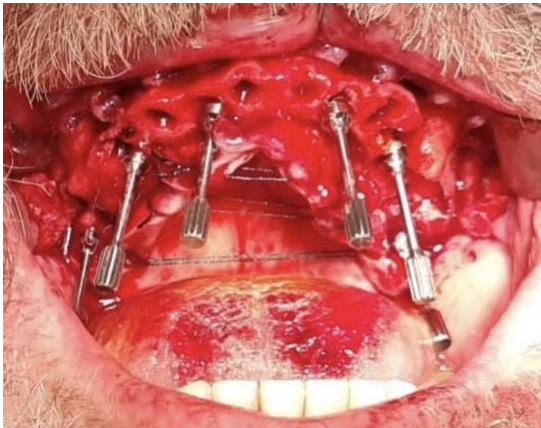


Fig. 2. Implants position.

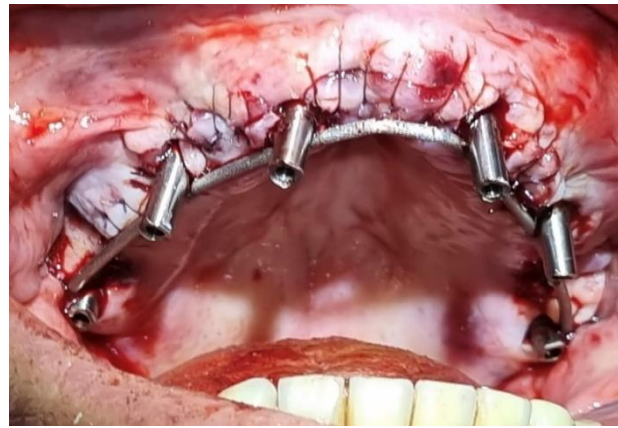

Fig. 3. Intraoral welding.

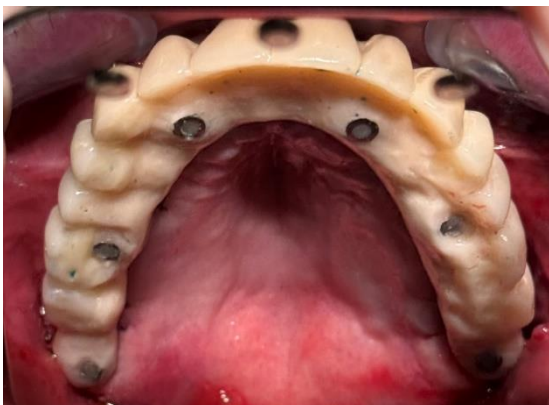

Fig. 4. Occlusal view of provisional denture.

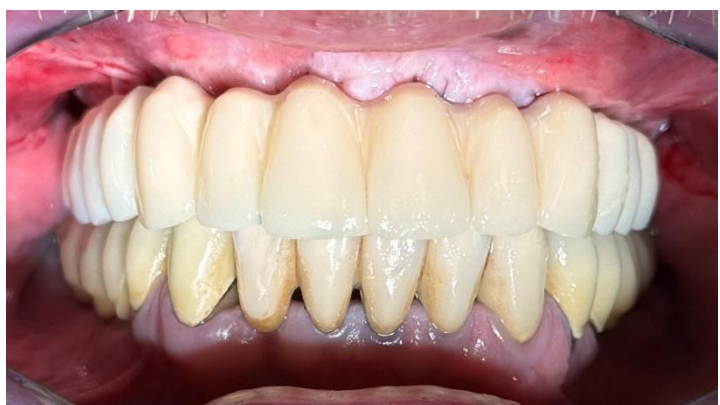

Fig. 5. Frontal view of the post-operative provisional denture.

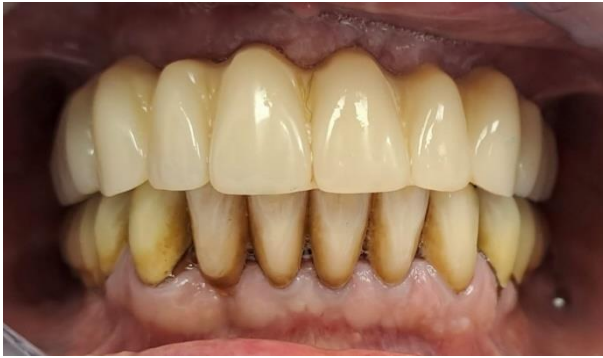

Fig. 6. *One-year follow-up.*

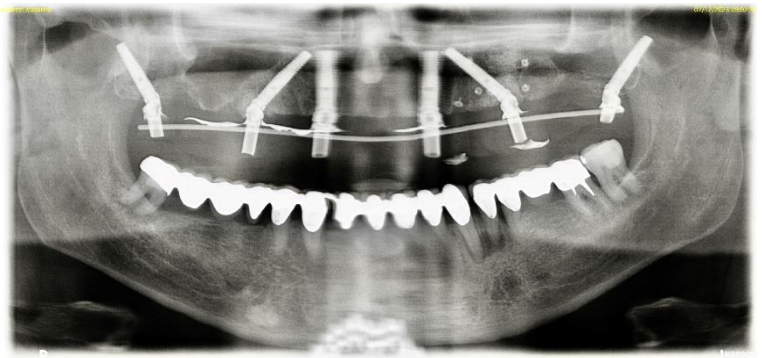


Fig. 7. *One-year X-ray.*

DISCUSSION

In the last decade of the 20th century, few articles have described the intra-oral welding technique (IOWT). Muratori (9) first reported an intra-oral welding technique. Then, Hruska et al. (10) reported using IOWT in more than 100 cases of non-submergible implants. The intra-oral welding was performed immediately after suture placement, with one or more connecting titanium wires as the splinting medium. This permits the patient to leave the office with a stable and retentive overdenture, resting securely on the newly created splint performed on the same day of surgery. This avoids the potentially troublesome problem of allowing the overdenture to be supported by the recently altered soft tissues. In addition, the patient otherwise would not use a denture during the bone-healing period, which creates an alteration in psychological and physiological status.

Several articles are available starting in 2010. Degidi et al. (11-15) did a series of reports on IOWT. In the first report (11), the authors evaluated thirty patients who received three axial and four tilted implants in the edentulous maxilla. Immediately after implant placement, definitive abutments were connected to the implants, and a titanium bar was welded to them using an intraoral welding unit. This framework was used to support the definitive restoration, which was attached on the day of implant placement. Since implant success rates of 97.8% for axial implants and 99.2% for tilted implants after 36 months of follow-up, they concluded that it is possible on the day of implant placement surgery to successfully rehabilitate the edentulous atrophic maxilla with a fixed, definitive restoration supported by an intraorally welded titanium framework attached to axial and tilted implants.

In the same year, Degidi et al (12), investigated rehabilitating edentulous mandibles using IOWT. Twenty patients with an edentulous mandible received four inter-foraminal, tapered connection implants. All implants were immediately loaded with a fixed restoration supported by an intra-orally welded titanium framework. Final abutments were connected to the implants, and a titanium bar was welded using an intra-oral welding unit. This framework was used to support the final restoration, fitted on the same day as the implant placement. All implants were osseointegrated, and a 100% implant survival rate was achieved during the 24-month follow-up.

In 2012, Degidi et al. (13) focused on osteointegration and crestal bone remodeling after 1 year around the implants for intraoral welded immediate full-arch prosthesis inserted with low insertion torque (i.e., ≤ 20 Ncm). Fifty-one implants presented an $IT \leq 20$ Ncm. The survival rate after 1 year was 98% for the test, so the authors suggested that rigid framework splinting can be a viable technique to improve the success rate of implants with low primary stability using immediate loading protocols for full-arch prosthesis.

In the same year, Degidi et al. (14) investigated if IOWT is a suitable technique for fabricating a fixed restoration for the edentulous maxilla on the day of surgery using standard and zygomatic implants. Ten consecutive patients were involved in this study, each with an edentulous atrophic maxilla and receiving two standard and two zygomatic implants. All implants were loaded immediately with a fixed prosthesis supported by an intraorally welded titanium framework. Definitive abutments were connected to the implants, and a titanium bar was welded using an intraoral welding unit. This framework was used to support the definitive prosthesis, which was fitted on the day of implant placement. A total of 20 immediately loaded standard and 20 zygomatic implants were used. The cases included in this study achieved a 100% prosthetic success rate at the 12-month follow-up. In 2013, Degidi and Coll (15) evaluated the 6-year effectiveness of maxillary and mandibular full-arch immediately loaded prostheses fabricated using IOWT. One hundred forty-four

implants were placed in maxillary cases, and 112 implants were placed in mandible cases, which completed the planned 6-year follow-up. Fracturing of the composite resin superstructure was the most common adverse event. The authors concluded that after a 6-year follow-up, the IOWT proved a predictable technique for successfully rehabilitating the fully edentulous patient with a fixed and immediate prosthesis.

The concepts mentioned above were further developed by adding digital support by Albiero et al. (16-18). In the first report, Albiero et al. (16) combined computer-assisted surgery with the IOWT to obtain a precise passive fit of the immediate loading prosthesis. They reported a case of an edentulous maxilla rehabilitated with four computer-assisted implants welded together intraorally and immediately loaded with a provisional restoration. No complications were observed at the 1-year follow-up. Subsequently (17), Albiero et al. described a case series to verify if IOWT increases the predictability of immediately loaded implants supporting a fixed full-arch prosthesis after computer-guided flapless implant placement. A total of 60 implants were placed consecutively in 10 patients. No mechanical or biological complications were registered at the 1-year follow-up. The authors concluded that despite the inaccuracy registered, this guided-welded approach allowed the achievement of a passive fit of the full-arch prosthesis on the inserted implants on the same day of the surgery and provided a high implant and prosthetic survival rate at the 1-year follow-up.

In 2020, Albiero et al. (18) focused on the clinical outcome of the 2-year follow-up of immediately loaded combined screw- and conometric-retained implant-supported full-arch restorations virtually planned using digital scanning technology. A total of 72 implants were inserted. All implants were immediately loaded with a complete-arch restoration supported by an intraorally welded framework. Digital scanning technology was used to virtually plan a combined screw and conometric retention of the frameworks. The survival rate after 2 years was 98.6%, as one implant failed during the osseointegration period. No major prosthetic complications were observed, such as issues with mobility, unscrewed abutments, disconnected conometric copings, and prosthetic fractures. Only one patient registered the chipping of a prosthesis. The authors concluded that the use of combined screw and conometric retention for fixed immediate restorations properly planned using digital scanning technology seems to be a viable treatment alternative to screw or conometric retention alone for immediately loaded rehabilitations.

In addition, manuscripts of independent Authors reporting single cases (19-22) and case series (23-26) add additional strength to the feasibility of the IOWT technique.

CONCLUSIONS

In conclusion, IOWT allows immediate implant loading and transforms a removable denture into a temporary full-arch rehabilitation. It is an evolutionary solution with respect to implant-supported dentures, both in terms of function and cost. The reported case series adds additional strength to this technique. It is applied in selected cases and when the dental team is well-trained since it needs not only an expert surgeon but also a prosthodontist familiar with welding techniques.

REFERENCES

1. Kerem K, Bahar S, Firuzan FO, Sibel A. Influence of Conventional Complete Dentures and Different Attachment Types in Implant-Supported Overdentures on Quality of Life and Nutritional Status in Edentulous Geriatric Patients. *Int J Prosthodont.* 2021 Jan-Feb;34(1):7-12. doi: 10.11607/ijp.6690.
2. Holst S, Geiselhoeringer H, Wichmann M, Holst AI. The effect of provisional restoration type on micromovement of implants. *J Prosthet Dent.* 2008 Sep;100(3):173-82.
3. Száva DT, Száva A, Száva J, Gálfi B, Vlase S. Dental Implant and Natural Tooth Micro-Movements during Mastication-In Vivo Study with 3D VIC Method. *J Pers Med.* 2022 Oct 10;12(10):1690. doi: 10.3390/jpm12101690.
4. Jemt T, Lindén B. Fixed implant-supported prostheses with welded titanium frameworks. *Int J Periodontics Restorative Dent.* 1992;12(3):177-84.
5. Jemt T. Three-dimensional distortion of gold alloy castings and welded titanium frameworks. Measurements of the precision of fit between completed implant prostheses and the master casts in routine edentulous situations. *J Oral Rehabil.* 1995 Aug;22(8):557-64.
6. Jemt T, Bergendal B, Arvidsson K, Bergendal T, Karlsson U, Linden B, Palmqvist S, Rundcrantz T, Bergström C. Laser-welded titanium frameworks supported by implants in the edentulous maxilla: a 2-year prospective multicenter study. *Int J Prosthodont.* 1998 Nov-Dec;11(6):551-7.
7. Ortorp A, Linden B, Jemt T. Clinical experiences with laser-welded titanium frameworks supported by implants in the edentulous mandible: a 5-year follow-up study. *Int J Prosthodont.* 1999 Jan-Feb;12(1):65-72.

8. Jemt T, Bergendal B, Arvidson K, Bergendal T, Karlsson LD, Linden B, Runderantz T, Wendelhag I. Implant-supported welded titanium frameworks in the edentulous maxilla: a 5-year prospective multicenter study. *Int J Prosthodont*. 2002 Nov-Dec;15(6):544-8.
9. Muratori G. Gimlet implant system and intra-oral welding. *J Oral Implantol*. 1989;15(3):194-7.
10. Hruska AR, Borelli P. Intra-oral welding of implants for an immediate load with overdentures. *J Oral Implantol*. 1993;19(1):34-8.
11. Degidi M, Nardi D, Piattelli A. Immediate loading of the edentulous maxilla with a definitive restoration supported by an intraorally welded titanium bar and tilted implants. *Int J Oral Maxillofac Implants*. 2010 Nov-Dec;25(6):1175-82.
12. Degidi M, Nardi D, Piattelli A. Prospective study with a 2-year follow-up on immediate implant loading in the edentulous mandible with a definitive restoration using intra-oral welding. *Clin Oral Implants Res*. 2010 Apr 1;21(4):379-85. doi: 10.1111/j.1600-0501.2009.01865.x.
13. Degidi M, Daprile G, Piattelli A. Implants inserted with low insertion torque values for intraoral welded full-arch prosthesis: 1-year follow-up. *Clin Implant Dent Relat Res*. 2012 May;14 Suppl 1:e39-45. doi: 10.1111/j.1708-8208.2011.00345.x.
14. Degidi M, Nardi D, Piattelli A, Malevez C. Immediate loading of zygomatic implants using the intraoral welding technique: a 12-month case series. *Int J Periodontics Restorative Dent*. 2012 Oct;32(5):e154-61.
15. Degidi M, Nardi D, Piattelli A. A six-year follow-up of full-arch immediate restorations fabricated with an intraoral welding technique. *Implant Dent*. 2013 Jun;22(3):224-31. doi: 10.1097/ID.0b013e31829261ed.
16. Albiero AM, Benato R. Computer-assisted surgery and intraoral welding technique for immediate implant-supported rehabilitation of the edentulous maxilla: case report and technical description. *Int J Med Robot*. 2016 Sep;12(3):453-60. doi: 10.1002/rcs.1715.
17. Albiero AM, Benato R, Benato A, Degidi M. Use of Intraoral Welding to Increase the Predictability of Immediately Loaded Computer-Guided Implants. *Int J Periodontics Restorative Dent*. 2017 Jul/Aug;37(4):591-598. doi: 10.11607/prd.3027.
18. Albiero AM, Benato R, Benato A, Degidi M. Guided-welded approach planning using digital scanning technology for combined screw- and conometric-retained implant-supported maxillary prosthesis. *Int J Comput Dent*. 2020;23(4):325-333.
19. Fornaini C, Merigo E, Cernavin I, López de Castro G, Vescovi P. Intraoral Laser Welding (ILW) in Implant Prosthetic Dentistry: Case Report. *Case Rep Dent*. 2012;2012:839141.
20. Fogli V, Camerini M, Lauritano D, Carinci F. Success and high predictability of intraorally welded titanium bar in the immediate loading implants. *Case Rep Dent*. 2014;2014:215378.
21. Rossi F, Pasqualini ME, Dal Carlo L, Shulman M, Nardone M, Winkler S. Immediate Loading of Maxillary One-Piece Screw Implants Utilizing Intraoral Welding: A Case Report. *J Oral Implantol*. 2015 Aug;41(4):473-5.
22. Celletti R, Fanali S, Laici CU, Santori C, Pignatelli P, Sinjari B. Instant loading with intraoral welding technique and PRAMA implants: a new prosthetic approach. *J Biol Regul Homeost Agents*. 2017 Oct-Dec;31(4):1127-1131.
23. Avvanzo P, Fabrocini LA, Ciavarella D, Avvanzo A, Lo Muzio L, De Maio RA. Use of intraoral welding to stabilize dental implants in augmented sites for immediate provisionalization: a case report. *J Oral Implantol*. 2012 Feb;38(1):33-41. doi: 10.1563/AAID-JOI-D-10-00047.
24. Marchesi M, Ferrari C, Superbi S, Jimbo R, Galli S. Modified protocol of the intraoral welding technique for immediate implant-supported rehabilitation of the edentulous maxilla. *Implant Dent*. 2015 Feb;24(1):110-6. doi: 10.1097/ID.0000000000000189.
25. Pasqualini ME, Lauritano D, Rossi F, Dal Carlo L, Shulman M, Meynardi F, Colombo D, Manenti P, Comola G, Zampetti P. Rehabilitations with immediate loading of one-piece implants stabilized with intraoral welding. *J Biol Regul Homeost Agents*. 2018 Jan-Feb;32(2 Suppl. 1):19-26.
26. Pasqualini M, Rossi F, Carlo LD, Comola G. Rehabilitations of a single element with one-piece implants with electrowelded needles: A different approach. *Dent Res J (Isfahan)*. 2018 Nov-Dec;15(6):447-452.



Review

ORAL MUCOSAE MANIFESTATION IN PATIENTS WITH EATING DISORDERS: AN OVERVIEW

G. Giannini¹, S. A. Gehrke², S.R. Tari¹, F. Lorusso¹ and A. Scarano^{1,3*}

¹Department of Innovative Technologies in Medicine & Dentistry, University of Chieti-Pescara, Italy;

²Universidad Católica de Murcia (UCAM), Murcia, Spain;

³Department of Oral Implantology, Dental Research Division, Colégio Ingá, UNINGÁ, Cachoeiro de Itapemirim, Espírito Santo, Brazil

*Correspondence to:

Antonio Scarano, DDS, MD

Department of Innovative Technologies in Medicine & Dentistry,

University of Chieti-Pescara,

Via Dei Vestini 31,

66100 Chieti Italy

e-mail. ascarano@unich.it

ABSTRACT

Eating disorders (EDs) are a group of complex disorders characterized by persistent disturbances in eating or eating-related behaviors, resulting in altered food consumption or absorption and significantly impacting physical health and psychosocial functioning. The dentist plays a significant role in these clinical issues. Through a properly conducted interview and a detailed extraoral and intraoral examination, the dentist can be the first healthcare professional to recognize the symptoms of an ED. The oral symptoms of eating disorders can manifest at any stage of the illness and serve as an essential indicator to assess its course, prognosis, and treatment. In the literature, there are many studies available on the effects of eating disorders on oral health and perioral tissues. Still, there are few studies on the relationship between oral surgery and eating disorders. This review aims to describe the oral mucosae manifestation in patients with eating disorders and their leading causes. EDs are highly prevalent conditions, and the likelihood of a dentist encountering such patients is substantial. When encountering a patient with a history of EDs, currently undergoing treatment for EDs, or suspected of having EDs, it is advisable, before proceeding with oral surgery, to assess the risk/benefit ratio of oral therapy.

KEYWORDS: *eating disorders, EDs, oral mucosae, food consumption/absorption, oral symptoms, oral surgery*

INTRODUCTION

Eating disorders (EDs) are a group of complex disorders characterized by persistent disturbances in eating or eating-related behaviors, resulting in altered food consumption or absorption and significantly impacting physical health and psychosocial functioning (1).

In Italy, EDs affect up to 5% of the population, meaning that currently, almost 3 million people in Italy have one of these disorders. From 2019 to 2022, there was a 40% increase in new cases, from 680,000 cases in 2019 to nearly 1.5 million in 2022. The recent pandemic likely contributed to the increased prevalence of these disorders, as the post-traumatic origin of eating disorders is recognized and well-documented. Eating disorders predominantly affect females (90%), but in recent years, there has been a higher incidence among males. These disorders often onset at a young age, with 58% of the population affected being between 13 and 25 years old. Furthermore, recent data indicate a further

Received: 20 April 2024

Accepted: 22 May 2024

ISSN 2975-1276 [online]

Copyright © by BIOLIFE 2024

This publication and/or article is for individual use only and may not be further reproduced without written permission from the copyright holder. Unauthorized reproduction may result in financial and other penalties. Disclosure: All authors report no conflicts of interest relevant to this article.

decrease in the age of onset, as 30% of the affected population is under 14 years old. The most common forms are Anorexia Nervosa (36.2%), Bulimia Nervosa (17.9%), and Binge Eating Disorder (12.4%) (2).

Nutrition and eating disorders have been included in the fifth edition of the Diagnostic and Statistical Manual of Mental Disorders (DSM-5), published in 2013 by the American Psychiatric Association (APA). The DSM-5 contains diagnostic criteria for mental disorders to assist clinicians in evaluating patients and making accurate diagnoses (1). Table I lists the diagnostic criteria for the most common eating disorders (Fig. 1-3).

Table I. Diagnostic criteria DSM-5 for major eating disorders.

Anorexia Nervosa	<ul style="list-style-type: none"> ● Restriction of calorie intake necessary for maintaining a healthy body weight, with significantly low body weight in the context of age, sex, developmental trajectory, and physical health. Significantly low body weight is defined as a weight below the normal minimum or, for children and adolescents, less than expected minimum weight. ● Intense fear of gaining weight or becoming fat, or persistent behavior that interferes with weight gain, even when significantly underweight. ● Disturbance in how one's body weight or shape is experienced, excessive influence of body weight or shape on self-esteem levels, or persistent lack of recognition of the seriousness of the current underweight condition. <p>Restricting type: Over the past 3 months, the individual has not engaged in recurrent episodes of binge eating or purging behaviors (e.g., self-induced vomiting or misuse of laxatives, diuretics, or enemas). In this subtype, weight loss is primarily achieved through dieting, fasting, and/or excessive physical activity.</p> <p>Binge-eating/purging type: Over the past 3 months, the individual has engaged in recurrent episodes of binge eating or purging behaviors (i.e., self-induced vomiting or misuse of laxatives, diuretics, or enemas).</p>
Bulimia Nervosa	<ul style="list-style-type: none"> ● Recurrent episodes of binge eating. An episode of binge eating is characterized by both of the following aspects: <ul style="list-style-type: none"> ○ Eating, within a discrete period of time (e.g., within a two-hour period), an amount of food that is significantly larger than what most individuals would eat in a similar period of time and under similar circumstances. ○ Feeling a loss of control during the episode (e.g., feeling unable to stop eating or control what or how much one is eating). ● Recurrent and inappropriate compensatory behaviors to prevent weight gain, such as self-induced vomiting, misuse of laxatives, diuretics, or other medications, fasting, or excessive physical activity. ● Binge eating and inappropriate compensatory behaviors both occur on average at least once a week for 3 months. ● Self-esteem levels are unduly influenced by body shape and weight. ● The disturbance is not exclusively manifested during episodes of anorexia nervosa.
Binge eating disorder	<ul style="list-style-type: none"> ● Recurrent episodes of binge eating. An episode of binge eating is characterized by both of the following aspects: <ul style="list-style-type: none"> ○ Eating, within a discrete period of time (e.g., within a two-hour period), an amount of food that is significantly larger than what most individuals would eat in a similar period of time and under similar circumstances. ○ Feeling a loss of control during the episode (e.g., feeling unable to stop eating or control what or how much one is eating). ● Episodes of binge eating are associated with three (or more) of the following aspects: <ul style="list-style-type: none"> ○ Eating much more rapidly than normal. ○ Eating until feeling uncomfortably full. ○ Eating large amounts of food even when not feeling physically hungry. ○ Eating alone because of embarrassment over how much one is eating. ○ Feeling disgusted with oneself, depressed, or very guilty after the episode. ● There is marked distress regarding the binge eating. ● The binge eating occurs, on average, at least once a week for 3 months. ● The binge eating is not associated with the systematic use of inappropriate compensatory behaviors as in bulimia nervosa, and it does not occur exclusively during episodes of bulimia nervosa or anorexia nervosa.

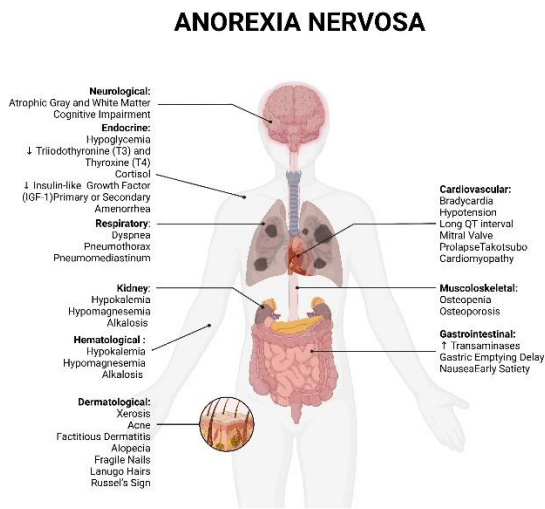


Fig. 1. Systemic involvement of anorexia.

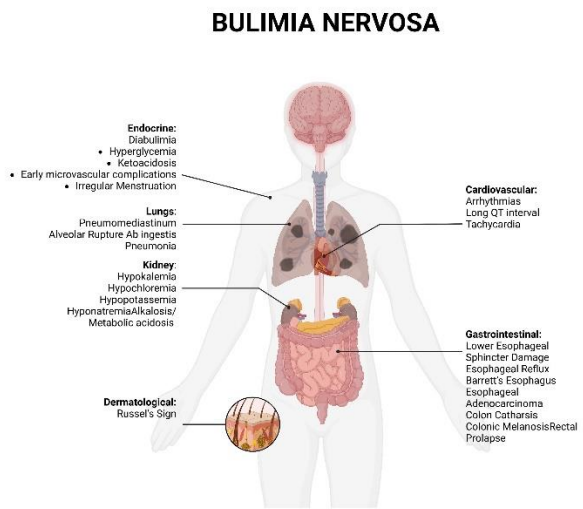


Fig. 2. Systemic complications of bulimia.

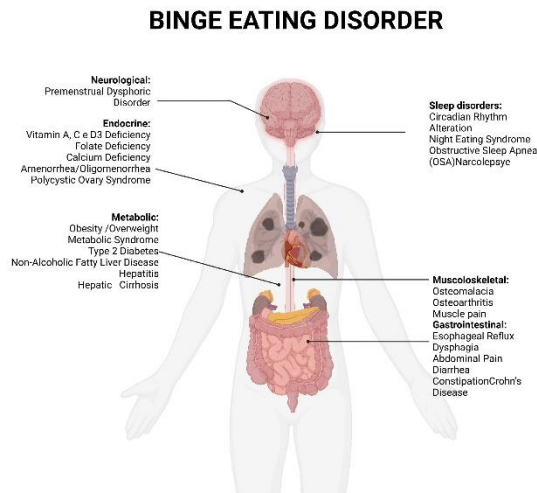


Fig. 3. Systemic complications of binge-eating disorder.

Over time, various systemic complications can develop, affecting different systems and organs of the human body (Table II). This highlights the importance of multidisciplinary treatment (3-7).

Table II. Systemic complications of anorexia, bulimia, and binge-eating disorder.

Systemic complications of major eating disorders			
	Anorexia Nervosa	Bulimia Nervosa	Binge Eating Disorder
Cardiovascular	Bradycardia Hypotension Long QT interval Mitral Valve Prolapse Takotsubo Cardiomyopathy	Arrhythmias Long QT interval Tachycardia	
Respiratory	Dyspnea Pneumothorax Pneumomediastinum	Pneumomediastinum Alveolar Rupture Ab ingestis Pneumonia	
Renal	Hypokalemia Hypomagnesemia Alkalosis	Hypokalemia Hypochloremia Hypopotassemia Hyponatremia	

		Alkalosis/Metabolic acidosis	
Endocrine	Hypoglycemia ↓ Triiodothyronine (T3) and Thyroxine (T4) Cortisol ↓ Insulin-like Growth Factor (IGF-1) Primary or Secondary Amenorrhea	Diabulimia <ul style="list-style-type: none"> • Hyperglycemia • Ketoacidosis • Early microvascular complications Irregular Menstruation	Vitamin A, C e D3 Deficiency Folate Deficiency Calcium Deficiency Amenorrhea/Oligomenorrhea Polycystic Ovary Syndrome
Musculoskeletal	Osteopenia Osteoporosis		Osteomalacia Osteoarthritis Muscle pain
Gastrointestinal	↑ Transaminases Gastric Emptying Delay Nausea Early Satiety	Lower Esophageal Sphincter Damage Esophageal Reflux Barrett's Esophagus Esophageal Adenocarcinoma Colon Catharsis Colonic Melanosis Rectal Prolapse	Esophageal Reflux Dysphagia Abdominal Pain Diarrhea Constipation Crohn's Disease
Hematological	Anemia Neutropenia Thrombocytopenia		
Dermatological	Xerosis Acne Factitious Dermatitis Alopecia Fragile Nails Lanugo Hairs Russel's Sign	Russel's Sign	
Neurological	Atrophic Gray and White Matter Cognitive Impairment Leg and Arm Neuropaxia		Premenstrual Dysphoric Disorder
Metabolic			Obesity /Overweight Metabolic Syndrome Type 2 Diabetes Non-Alcoholic Fatty Liver Disease Hepatitis Hepatic Cirrhosis
Sleep Disorders			Circadian Rhythm Alteration Night Eating Syndrome Obstructive Sleep Apnea (OSA) Narcolepsy

Eating disorders in dentistry

Patients with eating disorders require a thorough diagnosis and multidisciplinary treatment. However, the dentist plays a very important role in these clinical issues. The dentist can be the first healthcare professional to recognize symptoms of an ongoing systemic disease through an adequately conducted interview and a detailed extraoral and intraoral examination. Additionally, the dentist often precedes other healthcare professionals and can direct patients to competent specialists (8). Therefore, the dentist needs to recognize the signs and symptoms of oral cavity involvement in eating disorders to implement secondary prevention methods, allow appropriate diagnosis, and improve prognosis (9, 10).

The oral symptoms of eating disorders can manifest at any stage of the illness and serve as an important indicator to assess its course, prognosis, and treatment. The impact of eating disorders on the soft and hard tissues of the mouth depends on the diet and the duration and intensity of the illness (11, 12). Oral manifestations occurring in eating disorders are mainly caused by nutritional deficiencies and subsequent metabolic alterations. Still, they can also be related to the low priority given to personal hygiene care, underlying psychological disorders, altered nutritional habits (tendency to eat certain foods), or the intake of certain medications and bone healing (13-15).

Signs and symptoms of the oral cavity

Patients with eating disorders require a thorough diagnosis and multidisciplinary treatment. However, the dentist plays a very important role in these clinical issues. Through a properly conducted interview and a detailed extraoral and intraoral examination, the dentist can be the first healthcare professional to recognize symptoms of an ongoing systemic disease (16).

The oral symptoms of eating disorders can manifest at any stage of the illness and serve as an important indicator to assess its course, prognosis, and treatment. The impact of eating disorders on the soft and hard tissues of the mouth depends on the diet and the duration and intensity of the illness (11).

The oral manifestations of eating disorders are mainly caused by nutritional deficiencies and subsequent metabolic alterations. Still, they can also be related to the low priority given to personal hygiene care, underlying psychological disorders, altered nutritional habits (e.g., the tendency to eat certain foods), or the intake of certain medications (13).

Dental lesions

Dental erosion, also known as perimolysis, is the most common oral manifestation in individuals with eating disorders. Perimolysis is the dissolution of enamel and dentin, without bacterial involvement, caused by frequent exposure to internal or external acids. This leads to functional and aesthetic compromise of the dental elements (17). In the case of bulimia and anorexia nervosa, this wear is due to chronic vomiting and regurgitation, and these eating disorders are considered intrinsic causes of dental erosion. These lesions primarily appear on the incisal and lingual surfaces of the anterior teeth, which are thin and fractured. In severe cases, the patient's vertical dimension may decrease due to tooth wear. Dental erosions and their complications can cause oral symptoms ranging from tooth sensitivity to episodes of pain (13).

Dental caries typically have a multifactorial etiology; therefore, its occurrence cannot be solely attributed to the patient's eating disorder. Personal oral hygiene, genetic tendency, malnutrition, cariogenicity of the diet, fluoride exposure during odontogenesis, and the intake of specific medications are usually responsible for differences in caries prevalence in patients with eating disorders.

Chronic self-induced vomiting, excessive intake of laxatives, diuretics, and/or appetite suppressants, and strenuous workouts usually result in incessant dehydration. This, in turn, negatively affects the volume of saliva production and secretion. The intake of antidepressants as a therapeutic regimen for eating disorders can further induce a xerostomic effect, worsening the scenario. Increased salivary viscosity and decreased buffering capacity can thus lead to a decrease in salivary pH, contributing to demineralization and dental caries (18).

Periodontal diseases

Eating disorders have a peak incidence in children and young adults when the onset of advanced periodontal disease is less frequent. However, patients with eating disorders may have poor oral hygiene, which can lead to gingival inflammation and potentially predispose to periodontitis. Furthermore, nutritional deficiencies, especially vitamin C, can also affect the marginal periodontium predisposing to gingivitis. In particular, vitamin C deficiency, known as scurvy, causes defective collagen synthesis, which may be associated with generalized gingival swelling, spontaneous gingival bleeding, ulcerations, tooth mobility, and increased severity of periodontal infections (13).

Salivary gland manifestations

Patients with eating disorders often present with enlargement of the parotid glands. The onset of swelling usually follows a binge-eating episode. In the early stages of the eating disorder, glandular enlargement may appear and disappear, but it later becomes more persistent. This is caused by sialadenosis, a non-inflammatory enlargement of the salivary glands, caused by peripheral autonomic neuropathy, which is responsible for a disorder of metabolism and secretion, resulting in acinar enlargement and functional compromise (13). Sialadenosis can also involve the minor salivary glands (19). Another important aspect is the decrease in salivary flow. Xerostomia is caused by various factors, such as:

- structural alterations of the glands;
- the psychotropic medications prescribed to treat patients with eating disorders;
- the fluid imbalance caused by excessive use of diuretics and laxatives to prevent weight gain, as well as persistent vomiting.

Finally, reduced saliva production is responsible for lowering the pH of the mucosal surfaces in the hard palate region, which may be the reason for the pathologies of the minor salivary glands in the hard palate. A pathology observed very frequently is necrotizing sialometaplasia, mainly observed in association with bulimia. This is a self-limiting disorder with uncertain etiopathogenesis, probably caused by ischemic necrosis of the salivary gland lobules (5). Necrotizing sialometaplasia can mimic invasive carcinoma, and recognizing this pathology is essential to avoid misdiagnosis and unnecessary surgical therapies (13).

Lesions of the oral mucosa and perioral tissues

In patients with bulimia, erythematous lesions of the palate and ulcerations induced by trauma to the soft palate and pharynx are often observed due to chronic acid contact and repeated digital trauma (18).

Mucosal atrophy is often observed, mainly caused by reduced intake of vitamins, especially B group vitamins (B1, B6, and B12), which are associated with cellular turnover, and other nutrients, such as iron deficiency, which can lead to anemia. Mucosal atrophy is associated with a burning sensation, particularly intense on the tongue (glossodynia) (13). The burning sensation may be secondary to underlying psychological (anxiety, depression, and stress) and neurological disorders (20).

Furthermore, a yellow-orange discoloration of the mucosa can be observed at the level of the soft palate. This particular coloration is caused by an increase in the serum level of carotene: this can be provoked in patients with anorexia, by a diet rich in carotenoids, by the abuse of vitamin A analog supplements, and by hypothyroidism (21).

The increased incidence of exfoliative cheilitis in patients with eating disorders may be correlated with dehydration and decreased salivary secretion, lack of nutritional micronutrients (including vitamins A and B groups) due to periodic fasting, and parafunctions such as lip biting due to stress and emotional factors (22). In patients with bulimia, lip erythema is frequently observed, caused by the irritating chemical action of self-induced vomiting. It is mainly observed on the vermilion border of the lips and more commonly affects the lower lip (21).

Furthermore, oral mucosal hemorrhagic lesions (petechiae, ecchymosis, hematoma) can be observed, caused by a coagulopathy disorder or soft tissue injury, leading to vascular damage with extravasation of red blood cells (23). Patients with eating disorders are often affected by candidiasis. Fungal proliferation can be caused partly by the acidic environment and high carbohydrate intake in bulimic patients and, in part, by nutritional deficiencies (24,25). Chronic candidiasis has also been associated with the onset of angular cheilitis, although the latter can also be caused by superinfection by *Staphylococcus* (26).

DISCUSSION

EDs are highly prevalent conditions, and the likelihood of a dentist encountering such patients is substantial. While the dentist is not tasked with treating the eating disorder itself, they can undoubtedly contribute significantly to the multidisciplinary treatment of EDs.

When encountering a patient with a history of ED, who is currently undergoing treatment for ED, or who is suspected of having ED, it is advisable to assess the risk/benefit ratio of oral surgery before proceeding with it (27, 28). Oral surgery should be avoided during active phases of ED and postponed until stabilization phases.

In the absence of treatment guidelines for patients with ED, it is recommended to gather comprehensive patient history data, including information on the type of disorder, duration, presence of systemic sequelae, substance use, or medication for ED treatment. Additionally, laboratory and instrumental examinations are useful to assess the patient's health status. An anesthesiological evaluation of the patient is also beneficial to determine the need for sedation or pre-anesthesia anxiolysis, taking into account potential pharmacological interactions that may cause excessive sedation.

Before the procedure, it is advisable to consult other specialists involved in the patient's care, such as a psychiatrist or psychologist and a nutritionist, for postoperative dietary guidance. All members of the multidisciplinary team should closely monitor the patient in the postoperative phase to prevent relapses or exacerbations of ED (29, 30).

CONCLUSIONS

In conclusion, the dentist can collaborate with the patient's eating disorder treatment team to maximize oral success and reduce complications by being aware of the issues this patient presents.

REFERENCES

1. Association, A.P. Diagnostic and Statistical Manual of Mental Disorders. *Text revision 2000*.
2. Keski-Rahkonen, A.; Mustelin, L. Epidemiology of Eating Disorders in Europe: Prevalence, Incidence, Comorbidity, Course, Consequences, and Risk Factors. *Curr Opin Psychiatry* 2016, 29, 340-345, doi:10.1097/YCO.0000000000000278.
3. Shuttleworth, E.; Sharma, S.; Lal, S.; Allan, P. Medical Complications of Anorexia Nervosa. *Br J Hosp Med* 2016, 77, 287-293, doi:10.12968/hmed.2016.77.5.287.
4. Cass, K.; McGuire, C.; Bjork, I.; Sobotka, N.; Walsh, K.; Mehler, P.S. Medical Complications of Anorexia Nervosa. *Psychosomatics* 2020, 61, 625-631.

5. Nitsch, A.; Dlugosz, H.; Gibson, D.; Mehler, P.S. Medical Complications of Bulimia Nervosa. *CCJM* 2021, *88*, 333-343, doi:10.3949/ccjm.88a.20168.
6. Wassenaar, E.; Friedman, J.; Mehler, P.S. Medical Complications of Binge Eating Disorder. *Psychiatric Clinics of North America* 2019, *42*, 275-286, doi:10.1016/j.psc.2019.01.010.
7. Lanza Di Scalea, T.; Pearlstein, T. Premenstrual Dysphoric Disorder. *Medical Clinics of North America* 2019, *103*, 613-628, doi:10.1016/j.mcna.2019.02.007.
8. Faine, M.P. Recognition and Management of Eating Disorders in the Dental Office. *Dental Clinics of North America* 2003, *47*, 395-410, doi:10.1016/S0011-8532(02)00108-8.
9. DeBate, R.D.; Vogel, E.; Tedesco, L.A.; Neff, J.A. Sex Differences among Dentists Regarding Eating Disorders and Secondary Prevention Practices. *The Journal of the American Dental Association* 2006, *137*, 773-781, doi:10.14219/jada.archive.2006.0289.
10. Schmidt, U.; Treasure, J. Eating Disorders and the Dental Practitioner. *The European journal of prosthodontics and restorative dentistry* 1997, *5*, 161-167.
11. Frydrych, A.; Davies, G.; McDermott, B. Eating Disorders and Oral Health: A Review of the Literature. *Aust Dental J* 2005, *50*, 6-15, doi:10.1111/j.1834-7819.2005.tb00079.x.
12. Piattelli, A.; Scarano, A.; Piattelli, M. Detection of Alkaline and Acid Phosphatases around Titanium Implants: A Light Microscopical and Histochemical Study in Rabbits. *Biomaterials* 1995, *16*, 1333-1338.
13. Lo Russo, L.; Campisi, G.; Di Fede, O.; Di Liberto, C.; Panzarella, V.; Lo Muzio, L. Oral Manifestations of Eating Disorders: A Critical Review. *Oral Diseases* 2008, *14*, 479-484, doi:10.1111/j.1601-0825.2007.01422.x.
14. Borges, F.L.; Dias, R.O.; Piattelli, A.; Onuma, T.; Gouveia Cardoso, L.A.; Salomão, M.; Scarano, A.; Ayub, E.; Shibli, J.A. Simultaneous Sinus Membrane Elevation and Dental Implant Placement without Bone Graft: A 6-Month Follow-up Study. *J. Periodontol.* 2011, *82*, 403-412, doi:10.1902/jop.2010.100343.
15. Scarano, A.; Pecora, G.; Piattelli, M.; Piattelli, A. Osseointegration in a Sinus Augmented with Bovine Porous Bone Mineral: Histological Results in an Implant Retrieved 4 Years after Insertion. A Case Report. *J. Periodontol.* 2004, *75*, 1161-1166, doi:10.1902/jop.2004.75.8.1161.
16. Anderson, S.; Gopi-Firth, S. Eating Disorders and the Role of the Dental Team. *Br Dent J* 2023, *234*, 445-449, doi:10.1038/s41415-023-5619-x.
17. Daniel, C.P.; Ricci, H.A.; Boeck, E.M.; Bevilacqua, F.M.; Cerqueira-Leite, J.B.B. Perimolysis: Case Report. *RGO, Rev. Gaúch. Odontol.* 2015, *63*, 213-218, doi:10.1590/1981-863720150002000122397.
18. Hasan, S.; Ahmed, S.; Panigrahi, R.; Chaudhary, P.; Vyas, V.; Saeed, S. Oral Cavity and Eating Disorders: An Insight to Holistic Health. *J Family Med Prim Care* 2020, *9*, 3890, doi:10.4103/jfmpc.jfmpc_608_20.
19. Mignogna, M.D.; Fedele, S.; Lo Russo, L. Anorexia/Bulimia-related Sialadenosis of Palatal Minor Salivary Glands. *J Oral Pathology Medicine* 2004, *33*, 441-442, doi:10.1111/j.1600-0714.2004.00208.x.
20. Lourenço, M.; Azevedo, Á.; Brandão, I.; Gomes, P.S. Orofacial Manifestations in Outpatients with Anorexia Nervosa and Bulimia Nervosa Focusing on the Vomiting Behavior. *Clin Oral Invest* 2018, *22*, 1915-1922, doi:10.1007/s00784-017-2284-y.
21. Panico, R.; Piemonte, E.; Lazos, J.; Gilligan, G.; Zampini, A.; Lanfranchi, H. Oral Mucosal Lesions in Anorexia Nervosa, Bulimia Nervosa and EDNOS. *Journal of Psychiatric Research* 2018, *96*, 178-182, doi:10.1016/j.jpsychires.2017.09.022.
22. Monda, M.; Costacurta, M.; Maffei, L.; Docimo, R. Oral Manifestations of Eating Disorders in Adolescent Patients. A Review. *European Journal of Paediatric Dentistry* 2021, *22*, 155-158.
23. Silverman, S.; Lewis, E.; Edmond, L. *Essential of Oral Medicine*; Truelove BC Decker Incorporated, 2001;
24. Back-Brito, G.N.; Da Mota, A.J.; De Souza Bernardes, L.Á.; Takamune, S.S.; Prado, E.D.F.G.B.; Cordás, T.A.; Balducci, I.; Da Nobrega, F.G.; Koga-Ito, C.Y. Effects of Eating Disorders on Oral Fungal Diversity. *Oral Surgery, Oral Medicine, Oral Pathology and Oral Radiology* 2012, *113*, 512-517, doi:10.1016/j.oooo.2011.10.007.
25. Tolkachjov, S.N.; Bruce, A.J. Oral Manifestations of Nutritional Disorders. *Clinics in Dermatology* 2017, *35*, 441-452, doi:10.1016/j.clindermatol.2017.06.009.
26. Neville, B.W.; Damm, D.D.; Allen, C.M.; Chi, A.C. *Oral and Maxillofacial Pathology-E-Book*; Elsevier Health Sciences, 2023;
27. Blitz, M.; Rosen, D.S. Eating Disorders and the Oral and Maxillofacial Surgeon. *Oral and Maxillofacial Surgery Clinics of North America* 2010, *22*, 511-517, doi:10.1016/j.coms.2010.07.008.
28. Malchiodi, L.; Scarano, A.; Quaranta, M.; Piattelli, A. Rigid Fixation by Means of Titanium Mesh in Edentulous Ridge Expansion for Horizontal Ridge Augmentation in the Maxilla. *Int J Oral Maxillofac Implants* 1998, *13*, 701-705.
29. Giridhar, Vu. Role of Nutrition in Oral and Maxillofacial Surgery Patients. *Natl J Maxillofac Surg* 2016, *7*, 3, doi:10.4103/0975-5950.196146.
30. Maine, M.; Goldberg, M.H. The Role of Third Molar Surgery in the Exacerbation of Eating Disorders. *Journal of Oral and Maxillofacial Surgery* 2001, *59*, 1297-1300, doi:10.1053/joms.2001.27518.



Review

ALVEOLAR DISTRACTION OSTEOGENESIS FOR ALVEOLAR RIDGE DEFICIENCY: AN UPDATE AND NEW PERSPECTIVES

F. Gaudelli¹, C. Annicchiarico², S.R. Tari³, S.A. Gehrke⁴, A. Maltagnati⁵, A. Scarano³ and F. Mastrangelo¹

¹Department of Clinical and Experimental Medicine, University of Foggia, Foggia, Italy;

²Private Practice, Bari, Italy;

³Department of Innovative Technologies in Medicine & Dentistry, University of Chieti-Pescara, Italy;

⁴Department of Research, Bioface/PgO/UCAM, Montevideo, Uruguay, Department of Biotechnology, Universidad Católica de Murcia (UCAM), Murcia, Spain;

⁵Department of Surgical Sciences and Integrated Diagnostics, University of Genoa, Genoa, Italy

Correspondence to:

Antonio Scarano, DDS

University of Chieti-Pescara,

Via Dei Vestini 31,

66100 Chieti Italy

e-mail: ascarano@unich.it

ABSTRACT

Alveolar osteogenic distraction is a bone regeneration technique used in implantology to prepare implant sites, which, through the slow and constant distraction of a bone segment, allows the simultaneous regeneration of hard and soft tissues. The purpose of this review is to analyze the most recent articles in the literature and evaluate the role of modern piezoelectric surgery techniques, guided surgery, and invisible orthodontics. A search was conducted on the Pubmed platform. The initial selection was based on the title and abstract. Subsequently, the articles included in the study were chosen by reading the full text. The mean latency period was 7.26 ± 2.31 days. The mean distraction rate was 0.71 ± 0.27 mm, with one, two, or four daily activations. The mean distraction distance reported was 6.88 ± 2.52 mm. The mean consolidation period was 12.22 ± 5.58 weeks. The average period of osseointegration was 4.59 ± 1.34 months. The overall survival rate of the implants was 97%. Alveolar osteogenic distraction represents a predictable technique for bone regeneration. With the support of guided surgery, piezoelectric instruments, and new invisible bone traction devices, this technique can become even more predictable, minimally invasive, and increasingly aesthetic.

KEYWORDS: *distraction osteogenesis, alveolar ridge augmentation, piezoelectric surgery, guided surgery, aligners*

INTRODUCTION

In recent years, dental implants have significantly rehabilitated edentulous people, partially or totally. However, they require adequate bone volume for the correct positioning of the implants. Today, in the case of insufficient bone volume, the possible solutions are the use of short implants or bone regeneration. In regards to bone regeneration, various methodologies are available: GBR, autologous or heterologous bone grafts, ridge splitting, and alveolar osteogenic distraction (ADO).

ADO is a technique by which it is possible to regenerate bone through the distraction of two bone fragments following an osteotomy. The method is based on the tension-stress principle described for the first time by Dr Ilizarov (1,

Received: 19 April 2024
Accepted: 10 May 2024

ISSN 2975-1276 [online]

Copyright © by BIOLIFE 2024

This publication and/or article is for individual use only and may not be further reproduced without written permission from the copyright holder. Unauthorized reproduction may result in financial and other penalties. Disclosure: All authors report no conflicts of interest relevant to this article.

2), who conducted a series of experiments on the canine tibia to evaluate the optimal conditions for osteogenesis during limb lengthening, changes in the soft tissues subjected to lengthening and assess the influence of both speed and frequency of distraction. Ilizarov established two principles: the tension-stress principle, according to which when two bone segments are moved apart, there is pressure acting on one side and tension on the other, stimulating the action of osteoblasts, resulting in the generation of new bone; the influence of mechanical load and blood supply.

Following Ilizarov's principles, osteogenic distraction was applied in the human mandible and maxilla. The method was first clinically performed in 1992 by McCarthy and colleagues on hypoplastic mandibles of syndromic children (3).

The gradual distraction of the bone segment is followed simultaneously by osteogenesis (hard tissue formation) and histogenesis (soft tissue formation), as it determines stem cell differentiation, angiogenesis, and mineralization (4-6). This leads to a reduction in the treatment time and a more rapid placement of the implants, which show success rates similar to those inserted in native bone (7, 8).

ADO devices are divided into extraosseous, intraosseous, and distraction by implants. Extraosseous devices are the most used devices. Intraosseous distraction and distraction by implants require abundant basal bone for support (9).

MATERIALS AND METHODS

A search was conducted on the Pubmed platform. The search strategy was as follows: (“osteogenesis distraction” OR “distraction osteogenesis” OR “alveolar distraction osteogenesis” OR “alveolar distraction” AND “alveolar bone loss” OR “jaw atrophy” OR “atrophic jaw” OR “alveolar ridge deficiency”). An initial selection was based on the title and abstract. Subsequently, the articles included in the study were chosen by reading the full text.

RESULTS

After selecting studies by title and abstract, all articles were read in their entirety, and only 25 studies were considered for the current study.

The mean latency period is 7.26 ± 2.31 days (range 4-21 days). The mean distraction rate is 0.71 ± 0.27 mm (range 0.25-1 mm). The distraction rate varies between one, two, and four daily activations. The mean distraction distance reported was 6.88 ± 2.52 mm (range 3-15 mm). The mean consolidation period was 12.22 ± 5.58 weeks (range 4-24 weeks). The mean osseointegration period was 4.59 ± 1.34 months (range 3-8 months). The overall survival rate of the implants was 97% (10).

DISCUSSION

Alveolar osteogenic distraction consists of the following steps:

1. *Osteotomy and distractor placement*: surgical separation of the bone into two segments following the preparation of a flap (Fig. 1-3). It occurs by making two vertical incisions and one horizontal, creating a trapezoidal bone segment capable of moving. In the past, it was made with an oscillating saw, rotary instruments, or osteotomes. Today, the piezoelectric device is preferred, which uses ultrasonic vibrations to perform precision osteotomies (11-16). This results in a discontinuity in the integrity of the bone, which will trigger a healing process for the fracture, leading to a new bone callus. After the osteotomy, the bone distraction device is positioned, and the flap is closed and sutured.

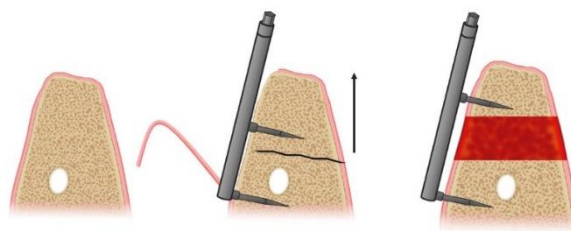


Fig. 1. Example of a distraction device used.

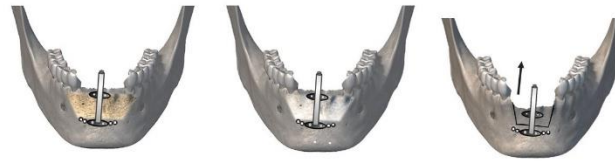

Fig. 2. The alveolar distraction procedure in the anterior mandible.

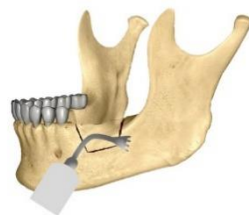


Fig. 3. The alveolar distraction procedure in the posterior mandible.

2. *Latency period*: the period between the osteotomy and the activation of the distractor. It represents the time required for the repair callus to form. Ilizarov's experiments showed that the latency period must be at least 5 days. The average latency period is 7 days to allow healing of the mucoperiosteum and reduce the risk of dehiscence. Prolonged latency periods exceeding 15 days have been applied to ensure complete revascularization of the transport segment in cases where the mucoperiosteal pedicle is small or endangered (10).
3. *Distraction*: the process of separating the two bone segments using a mechanical device that applies a pulling force. The normal healing process of the fracture is interrupted, and the biological processes of angiogenesis, fibroblast proliferation, and intensification of biosynthetic activity are stimulated (17). The quantity of bone to be distracted depends on the amount of bone necessary for implant rehabilitation (18). In addition to the amount of bone to be distracted, two fundamental parameters are:
 - a. *Distraction rate*: the amount of bone distracted per day. The mean distraction rate is 0.71 mm (10). A distraction rate of 0.5 mm per day results in faster osteogenesis than a distraction rate of 1 mm in elderly patients (19).
 - b. *Distraction rhythm*: the number of distractor activations per day. This parameter has tended to be chosen empirically, partly due to the lack of data in the literature. The rate of distraction varies between one, two, and four activations per day (10).

Distraction continues until the desired bone volume is achieved, and the total amount of distraction varies from 10 to 15 mm (17).

4. *Consolidation period*: the period following the distraction in which the complete mineralization of the new bone callus occurs. The mean consolidation period is 12 weeks (10). At least 10 weeks are required for the new bone to fill a 10 mm distraction gap (20).
5. *Distractor removal and implant placement*: Implants are placed 4 weeks after the distraction device is removed, with a 12-week osseointegration period (10).

It should be added that there is a phase of callus remodeling that begins upon completion of distraction, continues during the consolidation phase, and may extend up to 1 year after completion of distraction. In this phase, the initially formed bone scaffold is reinforced by parallel fibers of lamellar bone (18).

The main advantages of ADO are predictability, simultaneous regeneration of hard and soft tissues, and reduction of treatment times. On the other hand, the disadvantages are the need for greater collaboration with the patient, a greater number of visits, and higher costs (21). Furthermore, it is not a technique free from possible complications, the most frequent of which are malposition of the distracted segment, resorption of the distracted segment, fracture of the distractor or basal bone, local infection, and loss of the vestibule (22-25). However, this method could be too invasive for the patient, leading him to opt for different alternatives for aesthetic reasons, mainly due to the discomfort caused by unaesthetic obsolete devices.

Today, the new technologies at our disposal can represent a new frontier for alveolar osteogenic distraction, making it less invasive, shortening intervention times, and making the dentist's work easier. To carry out corticotomy, the piezoelectric device is preferred, thus reducing the aggressiveness of the operation, improving the visibility of the operating field, and reducing the risks of damage to the anatomical structures. Furthermore, the piezoelectric device reduces complications such as incomplete lingual osteotomy, laceration of the lingual periosteum, and injury to the inferior alveolar nerve (12).

A new frontier is also represented by guided surgery. In fact, after carrying out a CBCT, it is possible to design the case digitally. This will lead to the creation of surgical guides that can be used to carry out guided corticotomies and insertion according to the correct axis of the distraction device (26, 27). Moreover, using a surgical guide and corticotomies allows one to perform a flap-less operation, further improving patient compliance. Furthermore, this makes the latency period no longer necessary since waiting for the soft tissues to heal is unnecessary.

Concerning distraction devices, to meet the aesthetic requests of patients, it is imaginable to create a customized mini-device to obtain vertical growth on the model of palate expanders, with palatal or lingual anchoring for aesthetic needs. Since the device is entirely external, it significantly reduces the invasiveness of the operation.

Furthermore, possible support could be represented by invisible masks on the model of transparent removable aligners, which could guide the direction of the bone segment's distraction with precision and allow distraction with well-defined timing. Alternatively, invisible aligners could be used once distraction has ended during consolidation to stabilize the bone callus during the mineralization and remodeling processes.

CONCLUSIONS

Alveolar osteogenic distraction represents a predictable technique for bone regeneration. ADO results in a more stable outcome than GBR and block graft, but relapse is observed in 3% to 20% of cases. Therefore, an overcorrection of a few millimeters should be considered. This overcorrection can be easily reduced when removing the device and positioning the implant (9). With the support of guided surgery, piezoelectric instruments, and new invisible bone traction devices, this technique can become even more predictable, minimally invasive, and increasingly less aesthetic. The next step of this study will be patient testing to validate a new operating protocol that is effective and aesthetically accepted by the patient.

REFERENCES

1. Ilizarov GA. The tension-stress effect on the genesis and growth of tissues. Part I. The influence of stability of fixation and soft-tissue preservation. *Clinical Orthopaedics and Related Research*. 1989;238(238):249-281.
2. Ilizarov GA. The tension-stress effect on the genesis and growth of tissues: Part II. The influence of the rate and frequency of distraction. *Clinical Orthopaedics and Related Research*. 1989;239(239):263-285.
3. McCarthy JG, Schreiber J, Karp N, Thorne CH, Grayson BH. Lengthening the human mandible by gradual distraction. *Plastic and Reconstructive Surgery*. 1992;89(1):1-8; discussion 9-10.
4. Rachmiel A, Laufer D, Jackson IT, Lewinson D. Midface Membranous Bone Lengthening: A One-Year Histological and Morphological Follow-Up of Distraction Osteogenesis. *Calcified Tissue International*. 1998;62(4):370-376. doi:<https://doi.org/10.1007/s002239900447>
5. Rachmiel A, Leiser Y. The Molecular and Cellular Events That Take Place during Craniofacial Distraction Osteogenesis. *Plastic and Reconstructive Surgery Global Open*. 2014;2(1):e98. doi:<https://doi.org/10.1097/gox.0000000000000043>
6. Rachmiel A, Rozen N, Peled M, Lewinson D. Characterization of midface maxillary membranous bone formation during distraction osteogenesis. *Plastic and Reconstructive Surgery*. 2002;109(5):1611-1620. doi:<https://doi.org/10.1097/00006534-200204150-00019>
7. Chiapasco M, Consolo U, Bianchi A, Ronchi P. Alveolar distraction osteogenesis for the correction of vertically deficient edentulous ridges: a multicenter prospective study on humans. *The International Journal of Oral & Maxillofacial Implants*. 2004;19(3):399-407.
8. Chiapasco M, Lang NP, Bosshardt DD. Quality and quantity of bone following alveolar distraction osteogenesis in the

- human mandible. *Clinical Oral Implants Research*. 2006;17(4):394-402. doi:<https://doi.org/10.1111/j.1600-0501.2005.01247.x>
9. Tolstunov L, Hamrick JFE, Broumand V, Shilo D, Rachmiel A. Bone Augmentation Techniques for Horizontal and Vertical Alveolar Ridge Deficiency in Oral Implantology. *Oral and Maxillofacial Surgery Clinics of North America*. 2019;31(2):163-191. doi:<https://doi.org/10.1016/j.coms.2019.01.005>
 10. Saulacic N, Iizuka T, Martin MS, Garcia AG. Alveolar distraction osteogenesis: a systematic review. *International Journal of Oral and Maxillofacial Surgery*. 2008;37(1):1-7. doi:<https://doi.org/10.1016/j.ijom.2007.07.020>
 11. Robiony M, Toro C, Stucki-McCormick SU, Zerman N, Costa F, Politi M. The “FAD” (Floating Alveolar Device): A bidirectional distraction system for the alveolar process distraction osteogenesis. *Journal of Oral and Maxillofacial Surgery*. 2004;62(9 SUPPL 2):136-142. doi:<https://doi.org/10.1016/j.joms.2004.06.039>
 12. Robiony M, Zorzan E, Polini F, Sembronio S, Toro C, Politi M. Osteogenesis distraction and platelet-rich plasma: combined use in the restoration of severe atrophic mandible. Long-term results. *Clinical Oral Implants Research*. 2008;19(11):1202-1210. doi:<https://doi.org/10.1111/j.1600-0501.2008.01568.x>
 13. González-García A, Márcio Diniz-Freitas, Somoza-Martín M, García-García A. Piezoelectric bone surgery applied in alveolar distraction osteogenesis: a technical note. *PubMed*. 2007;22(6):1012-1016.
 14. González-García A, Márcio Diniz-Freitas, Somoza-Martín M, García-García A. Piezoelectric and conventional osteotomy in alveolar distraction osteogenesis in a series of 17 patients. *PubMed*. 2008;23(5):891-896.
 15. Scarano A, Carinci F, Assenza B, Piattelli M, Murmura G, Piattelli A. Vertical ridge augmentation of the atrophic posterior mandible using an inlay technique with a xenograft without mini-screws and mini plates: case series. *Clinical Oral Implants Research*. 2011;22(10):1125-1130. doi:<https://doi.org/10.1111/j.1600-0501.2010.02083.x>
 16. Maglione M, Bevilacqua L, Dotto F, Costantinides F, Lorusso F, Scarano A. Observational Study on the Preparation of the Implant Site with Piezosurgery vs. Drill: Comparison between the Two Methods in terms of Postoperative Pain, Surgical Times, and Operational Advantages. *BioMed Research International*. 2019;2019:1-6. doi:<https://doi.org/10.1155/2019/8483658>
 17. Sant S, Jagtap A. Alveolar Distraction Osteogenesis: Revive and Restore the Native Bone. *Journal of Prosthodontics*. 2009;18(8):694-697. doi:<https://doi.org/10.1111/j.1532-849x.2009.00512.x>
 18. Vega LG, Bilbao A. Alveolar Distraction Osteogenesis for Dental Implant Preparation: An Update. *Oral and Maxillofacial Surgery Clinics of North America*. 2010;22(3):369-385. doi:<https://doi.org/10.1016/j.coms.2010.04.004>
 19. Amir LR, Becking AG, Jovanovic A, Perdijk FBT, Everts V, Bronckers ALJJ. Vertical distraction osteogenesis in the human mandible: a prospective morphometric study. *Clinical Oral Implants Research*. 2006;17(4):417-425. doi:<https://doi.org/10.1111/j.1600-0501.2005.01231.x>
 20. Amir LR, Becking AG, Jovanovic A, Frits, Everts V, Antonius L. J. J. Bronckers. The formation of new bone during vertical distraction osteogenesis of the human mandible is related to the presence of blood vessels. *Clinical oral implants research*. 2006;17(4):410-416. doi:<https://doi.org/10.1111/j.1600-0501.2006.01258.x>
 21. Toledano-Serrabona J, Sanchez-Garces M, Sanchez-Torres A, Gay-Escoda C. Alveolar distraction osteogenesis for dental implant treatments of the vertical bone atrophy: A systematic review. *Medicina Oral Patología Oral y Cirugía Bucal*. 2018;24(1). doi:<https://doi.org/10.4317/medoral.22750>
 22. Saulačić N, Somosa Martín M, de los Angeles Leon Camacho M, García García A. Complications in Alveolar Distraction Osteogenesis: A Clinical Investigation. *Journal of Oral and Maxillofacial Surgery*. 2007;65(2):267-274. doi:<https://doi.org/10.1016/j.joms.2006.03.049>
 23. Ettl T, Gerlach T, Schüsselbauer T, Gosau M, Reichert TE, Driemel O. Bone resorption and complications in alveolar distraction osteogenesis. *Clinical Oral Investigations*. 2009;14(5):481-489. doi:<https://doi.org/10.1007/s00784-009-0340-y>
 24. Aizenbud D, Hazan-Molina H, Cohen M, Rachmiel A. 3D vector control during alveolar ridge augmentation using distraction osteogenesis and temporary anchorage devices: a new technique. *International Journal of Oral and Maxillofacial Surgery*. 2012;41(2):168-170. doi:<https://doi.org/10.1016/j.ijom.2011.08.003>
 25. Ismail Doruk Kocyigit, Hakan Hifzi Tuz, Ozkan Ozgul, Fatih Mehmet Coskunes, Reha Sukru Kisnisci. A Simple Solution for Vector Control in Vertical Alveolar Distraction Osteogenesis. *The Journal of Oral Implantology*. 2014;40(5):557-560. doi:<https://doi.org/10.1563/aaid-joi-d-12-00018>
 26. Hossam El-Dien Hany, El N, Sleem H, Taha M, Marwa El Kassaby. Novel Technique and Step-by-Step Construction of a Computer-Guided Stent for Mandibular Distraction Osteogenesis. *The Journal of craniofacial surgery*. 2019;30(7):2271-2274. doi:<https://doi.org/10.1097/scs.00000000000005614>
 27. Yu H, Wang B, Wang M, Wang X, Shen SG. Computer-Assisted Distraction Osteogenesis in the Treatment of Hemifacial Microsomia. *Journal of Craniofacial Surgery*. 2016;27(6):1539-1542. doi:<https://doi.org/10.1097/scs.00000000000002838>



Review

DENTAL IMPLANTS DISPLACED INTO THE MANDIBULAR CORPUS: A MINI-REVIEW

F. Tricca^{1†*}, S.R. Tari^{1‡}, S. Benedicenti², S.A. Gehrke^{3‡}, F. Inchingolo^{4†} and A. Scarano¹

¹Department of Innovative Technologies in Medicine and Dentistry, University of Chieti-Pescara, Chieti, Italy;

²Department of Surgical Sciences and Integrated Diagnostics, University of Genoa, Genoa, Italy;

³Department of Research, Bioface/PgO/UCAM, Montevideo, Uruguay, Department of Biotechnology, Universidad Católica de Murcia (UCAM), Murcia, Spain;

⁴Department of Interdisciplinary Medicine, Section of Dental Medicine, University of Bari “Aldo Moro”, Bari, Italy

†These authors contributed equally to this work as co-first Authors

‡These authors contributed equally to this work as co-last Authors

Correspondence to:

Antonio Scarano, DDS

Department of Innovative Technologies in Medicine and Dentistry,

University of Chieti-Pescara,

66100 Chieti, Italy

e-mail: ascarano@unich.it

ABSTRACT

Although dental implant surgery is considered a somewhat predictable procedure, unforeseen accidents can occur, particularly in the posterior areas where the trabecular density is lower than the anterior. In the posterior mandible, poor bone density, loss of cortical engagement, and differences in bone quality between alveolar and basal bone could undermine the success of the treatment, resulting in a subsequent implant migration to the medullary bone marrow. Inadequate surgical technique/planning, overworking of the implant bed, improper management of implant procedures along with systemic disease (osteopenia or osteoporosis), as well as the presence of lesions or cysts, can contribute to the development of the complication. To maximize bone engagement avoiding implant displacement, several precautions have been proposed. Treatment varies according to the depth of the displaced implant. In the case of superficial displacement above the inferior alveolar nerve, the crestal approach is the treatment of choice. When encountering deep displacement, a lateral approach is recommended as it provides better visibility and an improved operation field for implant retrieval.

KEYWORDS: *displaced implant, mandibular corpus, complication, focal osteoporotic, bone marrow defect*

INTRODUCTION

Nowadays, implant rehabilitation is a relatively highly predictable procedure. However, especially in severe horizontal or vertical bone resorptions, the success of such a treatment can be jeopardized by several complications, such as bleeding, nerve damage, mandibular fractures, damage to adjacent teeth, lack of primary stability, displacement or migration of implants (1-3).

Received: 25 April 2024
Accepted: 29 May 2024

ISSN 2975-1276 [online]

Copyright © by BIOLIFE 2024

This publication and/or article is for individual use only and may not be further reproduced without written permission from the copyright holder. Unauthorized reproduction may result in financial and other penalties. Disclosure: All authors report no conflicts of interest relevant to this article.

Implant displacement is a rare complication in implantology. It may arise either during the surgical procedure or shortly after that. Maxillary sinus (4) and sublingual (5) spaces are the main locations interested in migration, and acute symptomatology is generally accompanied by chronic infection derived from an immune response to the contaminated implant migrated in such areas. The medullary component of the mandibular corpus seems to be hardly involved, and compared to other locations, milder symptoms are reported when such a complication occurs. However, the inferior alveolar nerve can be severely compromised by both the displacement itself and by the subsequent implant retrieval surgery.

The objective of this mini-review was to highlight the clinical characteristics of patients who reported implant displacement into the marrow space, define potential risk factors, and provide insight into preventive measures and treatment strategies.

MATERIALS AND METHODS

To conduct this literature review, PubMed database was searched using the string ("Dental implants displace and mandibular corpus " OR " Dental implants" OR " mandibular corpus ") AND "osteoporotic focal".

The titles and abstracts of each paper obtained from the results were listed, and full-text manuscripts were retrieved using online resources.

RESULTS

The Keyword “dental implant displaced” shows 907 results, “mandibular corpus” shows 585 results papers twenty-three papers were detected when using Dental implants and mandibular corpus as keywords, then focal osteoporotic shows 10 papers.

DISCUSSION

Implant migration due to inadequate surgical technique, inexperienced operator or anatomical variations can occur intraoperatively or be delayed in a short time.

In the edentulous maxilla, the limited amount and/or poor quality of bone available, along with pneumatization processes of the maxillary sinus, play a key role in the genesis of the complication (6). In the case of maxillary implant displacement, functional endoscopic sinus surgery (FESS), intraoral approach, or a combination of both are planned for the implant retrieval (7).

When mandibular posterior areas are considered, several authors reported lower volume and fewer trabeculae patterns of the basal bone compared to the alveolar bone (8). The presence of such a loose structure with lower volume and thin trabeculae, accompanied by local resorption of crestal bone, could greatly facilitate implant displacement into the medullary component.

Operator-dependent procedures such as inadequate surgical technique/planning and overworking the implant bed are recognized as other main causes of implant displacement. Several case reports suggested that improper management of implant procedures, such as tightening of the healing screw (9), the use of the hand wrench (10), or placement of a driver to the healing screw (6), could lead to the loss of cortical bone engagement and a resulting implant displacement towards the zone of lesser resistance. Even attempting to remove the implant may result in a worsening of the condition with further displacement (9), along with nerve damage. Other not operator-dependent features such as systemic diseases (osteopenia or osteoporosis) and the presence of lesions or cysts can contribute to the development of the complication.

Although osteoporosis does not seem to be a risk factor for osteointegrated dental implants (11), alterations of the trabecular pattern observed in patients' jaws with osteoporosis (12) may represent a potential obstacle to the primary stability (13). Furthermore, using resonance frequency analysis (RFA), lower primary stability was recorded in patients with skeletal osteoporosis and osteopenia, suggesting a plausible impact of such conditions on alveolar bone density and implant stability (14).

Also, focal osteoporotic bone marrow defects (FOBMD), reported as radiolucent areas in edentulous jaws, often found in the posterior mandible of middle-aged women, seem to be correlated to the risk of implant migration. The pathogenesis of this condition remains unclear; nevertheless, certain factors, such as abnormalities in bone regeneration after tooth extraction or dental implant placement (15, 16), as well as the persistence of fetal marrow or marrow hyperplasia in response to increased demand for erythrocytes (17) are hypothesized to be relevant. Clinically, FOBMDs

often appear as an isolated or multifocal radiolucency from several millimeters up to centimeters in diameter with ill-defined borders (18) and fine central trabeculation.

Based only on clinical and radiographic findings, three cases of implant displacement into FOBMD have been reported by SC Lee et al. (17). However, histological analysis is mandatory to differentiate this condition from other similar radiolucent lesions of the jaws, such as traumatic bone cyst or fibrous dysplasia. Garcia et al. (16), reporting a case of FOBMD associated with a dental implant, showed the presence of monocytic, erythroid, granulocytic, and lymphocytic series as well as megakaryocytes and fatty cells in hematopoietic marrow a typical feature and histopathological analysis must be integrated with clinic and radiographic signs for the final diagnosis.

Preoperative panoramic radiographs could not efficiently diagnose radiolucent appearances derived from traumatic bone cysts (19) or FOBMD (6). Analysing the removal of cancellous bone from posterior areas of mandibles, Bender and Seltzer (20) hardly found alterations of the radiographic appearance of the trabeculae. Therefore, in most cases, these lesions remain undetected (21), and only preoperative CBCT can be a reliable approach.

Surgical procedures such as countersinking, especially in type III and IV bone, decrease the cortical bone thickness, undermining the primary stability (22). Thus, avoiding countersinking may be fundamental in cases of low-density bone. Choosing wide diameters (22), undersized preparations (23), or securing the healing screw in the implant body before the placement (17) could be other effective proposals to avoid implant displacement. Regarding treatment, an accurate radiological analysis should be carried out to select the best removal approach due to the potential damage to the inferior alveolar nerve.

A crestal approach (9, 10, 17) offers a limited vision and smaller operation field, so hole enlargement is often required to engage the fixture. Moreover, further displacement could occur (with a higher risk for the nerve), and the additional bone removal could invalidate the future new implant fixation. Even with important limitations, this technique is recommended when the implant is not deeply displaced above the inferior alveolar nerve. A wider operation field is required in deeper implant migration, and a lateral approach to create a bony window is indicated (Fig. 1) (24). Osteotomy with piezoelectric devices was shown to be more effective than the rotary instruments, with minimal injury to the local alveolar bone so that fixation of the bony lid is often unnecessary after implant retrieval (13).

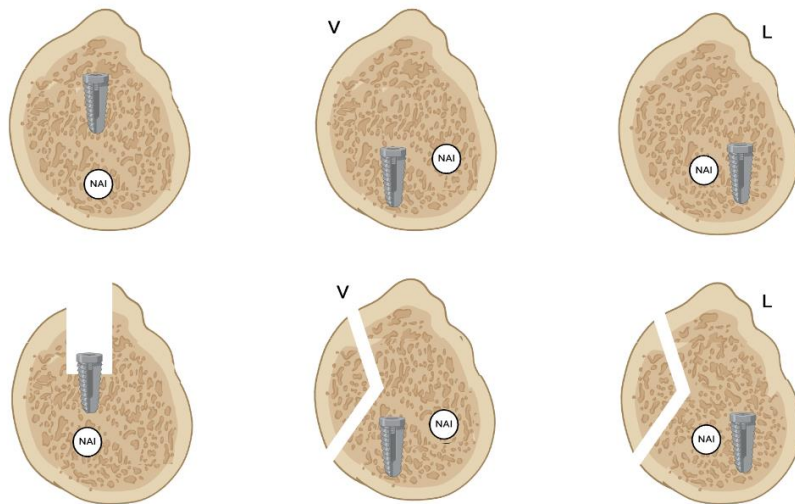


Fig. 1. Approaches for implant retrieval into mandibular bony marrow. For superficial implant displacement above the inferior alveolar nerve (NAI), a crestal approach through enlargement of the implant hole is recommended. For deep displacement (vestibular or lingual to NAI), creating a bony lid enables a wider operation field and better visibility.

Clinicians should be aware of preoperative radiographic limitations. As Theisen et al. (9) reported, large medullary components should be suspected when the location of the inferior alveolar nerve cannot be detected on a panoramic radiograph. Especially when treating patients with a history of osteoporosis/osteopenia or for patients whose molar teeth were extracted much earlier in their life (particularly among postmenopausal women), a careful evaluation

through CT imaging is highly recommended (10) to avoid the risk of implant migration into the medullary component of the mandibular ramus.

CONCLUSIONS

Even if implant displacement into the mandibular might not be a serious complication, without all the sequelae reported by the dislocation in the maxillary sinus or in the sublingual space, immediate removal is mandatory to avoid possible complications derived from bone healing (21). Particular care must be taken when retrieval surgery is performed.

Preventive measures such as avoiding countersinking, selecting wider diameters, undersizing preparations, or securing the healing screw in the implant body before the placement can be effective in cases of low-density bone to avoid implant migration and should be considered.

REFERENCES

- Piattelli A, Scarano A, Piattelli M. Detection of alkaline and acid phosphatases around titanium implants: a light microscopical and histochemical study in rabbits. *Biomaterials*. 1995;16(17):1333-1338. doi:[https://doi.org/10.1016/0142-9612\(95\)91049-5](https://doi.org/10.1016/0142-9612(95)91049-5)
- Borges FL, Dias RO, Piattelli A, et al. Simultaneous Sinus Membrane Elevation and Dental Implant Placement Without Bone Graft: A 6-Month Follow-Up Study. *Journal of Periodontology*. 2011;82(3):403-412. doi:<https://doi.org/10.1902/jop.2010.100343>
- Scarano A, Cholakis A, Piattelli A. Histologic Evaluation of Sinus Grafting Materials After Peri-implantitis-Induced Failure: A Case Series. *The International Journal of Oral & Maxillofacial Implants*. 2017;32(2):e36-e75. doi:<https://doi.org/10.11607/jomi.5303>
- Scarano A, Perrotti V, Carinci F, Shibli JA. Removal of a migrated dental implant from the maxillary sinus after 7 years: a case report. *Oral and Maxillofacial Surgery*. 2010;15(4):239-243. doi:<https://doi.org/10.1007/s10006-010-0243-8>
- Cariati P, Fernandez-Solis J, Marin-Fernandez A, Valencia-Laseca A, Monsalve-Iglesias F. Accidental displacement of a dental implant into the sublingual space: A Case report. *Journal of Clinical and Experimental Dentistry*. 2016;8(4). doi:<https://doi.org/10.4317/jced.52994>
- Bayram B, Alaaddinoglu E. Implant-Box Mandible: Dislocation of an Implant into the Mandible. *Journal of Oral and Maxillofacial Surgery*. 2011;69(2):498-501. doi:<https://doi.org/10.1016/j.joms.2010.10.027>
- Chiapasco M, Felisati G, Maccari A, Borloni R, Gatti F, Di Leo F. The management of complications following displacement of oral implants in the paranasal sinuses: a multicenter clinical report and proposed treatment protocols. *International Journal of Oral and Maxillofacial Surgery*. 2009;38(12):1273-1278. doi:<https://doi.org/10.1016/j.ijom.2009.09.001>
- Moon HS ., Won YY ., Kim KD ., et al. The three-dimensional microstructure of the trabecular bone in the mandible. *Surgical and Radiologic Anatomy*. 2004;26(6):466-473. doi:<https://doi.org/10.1007/s00276-004-0247-x>
- Theisen FC, Shultz RE, Elledge DA. Displacement of a root form implant into the mandibular canal. *Oral Surgery, Oral Medicine, Oral Pathology*. 1990;70(1):24-28. doi:[https://doi.org/10.1016/0030-4220\(90\)90172-o](https://doi.org/10.1016/0030-4220(90)90172-o)
- Doh RM, Pang NS, Kim KD, Park W. Implant Displacement into the Mandible: An Unusual Complication During Implant Surgery. *Implant Dentistry*. 2011;20(5):345-348. doi:<https://doi.org/10.1097/id.0b013e3182326813>
- Grant BT, Amenedo C, Freeman K, Kraut RA. Outcomes of Placing Dental Implants in Patients Taking Oral Bisphosphonates: A Review of 115 Cases. *Journal of Oral and Maxillofacial Surgery*. 2008;66(2):223-230. doi:<https://doi.org/10.1016/j.joms.2007.09.019>
- White SC, Rudolph DJ. Alterations of the trabecular pattern of the jaws in patients with osteoporosis. *Oral Surgery, Oral Medicine, Oral Pathology, Oral Radiology, and Endodontics*. 1999;88(5):628-635. doi:[https://doi.org/10.1016/s1079-2104\(99\)70097-1](https://doi.org/10.1016/s1079-2104(99)70097-1)
- Kwon YD, Pae A. Piezoelectric Trapezoidal Osteotomy for the Retrieval of a Displaced Dental Implant in the Osteoporotic Mandibular Body. *Implant dentistry*. 2016;25(5):703-706. doi:<https://doi.org/10.1097/id.0000000000000464>
- Merheb J, Temmerman A, Rasmusson L, Kübler A, Thor A, Quirynen M. Influence of Skeletal and Local Bone Density on Dental Implant Stability in Patients with Osteoporosis. *Clinical Implant Dentistry and Related Research*. 2016;18(2):253-260. doi:<https://doi.org/10.1111/cid.12290>
- Sencimen M, Delilbasi C, Gulses A, Murat Okcu K, Gunhan O, Varol A. Focal osteoporotic hematopoietic bone marrow defect formation around a dental implant: a case report. *Int J Oral Maxillofac Implants*. 2011;26(1).
- Garcia NG, Barros FBA, Carvalho MMD, Oliveira DT. Focal osteoporotic bone marrow defect involving dental implant: a case report. *International Journal of Implant Dentistry*. 2015;1(1). doi:<https://doi.org/10.1186/s40729-015-0020-4>

17. Lee SC, Jeong CH, Im HY, et al. Displacement of dental implants into the focal osteoporotic bone marrow defect: a report of three cases. *Journal of the Korean Association of Oral and Maxillofacial Surgeons*. 2013;39(2):94-99. doi:<https://doi.org/10.5125/jkaoms.2013.39.2.94>
18. Bravo-Calderón DM, Oliveira DT, Martins dos Santos WH. Bilateral osteoporotic bone marrow defects of the mandible: a case report. *Head & Face Medicine*. 2012;8(1). doi:<https://doi.org/10.1186/1746-160x-8-22>
19. Xanthinaki AA, Choupis KI, Tosios K, Pagkalos VA, Papanikolaou SI. Traumatic bone cyst of the mandible of possible iatrogenic origin: a case report and brief review of the literature. *Head & Face Medicine*. 2006;2(1). doi:<https://doi.org/10.1186/1746-160x-2-40>
20. Bender I, Seltzer S. Roentgenographic and Direct Observation of Experimental Lesions in Bone: I†. *Journal of Endodontics*. 2003;29(11):702-706. doi:<https://doi.org/10.1097/00004770-200311000-00005>
21. Scarano A, Lorusso F, Santos P, Murmura G. Dental implants displaced into the mandibular corpus: clinical note. *Journal of dentistry and oral care*. 2018;4(1):8-12. doi:<https://doi.org/10.15436/2379-1705.18.1804>
22. Martinez H, Davarpanah M, Missika P, Celletti R, Lazzara R. Optimal implant stabilization in low density bone. *Clinical Oral Implants Research*. 2001;12(5):423-432. doi:<https://doi.org/10.1034/j.1600-0501.2001.120501.x>
23. Coelho PG, Marin C, Teixeira HS, et al. Biomechanical Evaluation of Undersized Drilling on Implant Biomechanical Stability at Early Implantation Times. *Journal of Oral and Maxillofacial Surgery*. 2013;71(2):e69-e75. doi:<https://doi.org/10.1016/j.joms.2012.10.008>
24. Kim JW, Jun-Young Paeng, Choi SY, Kwon TG. Displacement of Dental Implants Into the Mandibular Bone Marrow Space: Cause and Treatment. A Case Study and Literature Review. *Journal of Oral Implantology*. 2017;43(2):151-157. doi:<https://doi.org/10.1563/aaid-joi-d-16-00205>



Review

ZEKRYA BUR FRACTURE DURING EXTRACTION: HOW CAN THIS TYPE OF COMPLICATION BE AVOIDED? A LITERATURE REVIEW

L. Gonçalves Ferreira¹, F. Britto de Melo Silva¹, A. Scarano², S.A. Gehrke³, G.V. de Oliveira Fernandes⁴ and R.F. De Brito Resende^{1,5}

¹Faculty of Dentistry, Universidad Federal Fluminense, Niterói, RJ, Brazil;

²Department of Innovative Technologies in Medicine & Dentistry, University of Chieti-Pescara, Chieti, Italy;

³Bioengineering department, Universidad Miguel Hernandez de Elche, Alicante, Spain;

⁴A.T. Still University – Missouri School of Dentistry & Oral Health, St. Louis, MO, U.S.A.;

⁵Faculty of Dentistry, Universidade Iguaçú, Nova Iguaçú, RJ, Brazil

Corresponding author:

Rodrigo Figueiredo de Brito Resende, DDS

Faculty of Dentistry,

Universidad Federal Fluminense,

R. Mario Santos Braga 28,

Centro, Niterói,

24020-140, Rio de Janeiro, Brazil

e-mail: resende.r@hotmail.com

ABSTRACT

Extractions are a recurrent dental surgical procedure. Occasionally, tooth extraction is not easy, and there is the possibility of several complications, including the fracture and migration of instruments, especially during surgery of third molars. Such conditions can be triggered by several factors, such as defective manufacturing, stress, fatigue, rust, poor handling, and the use of worn burs or inadequate irrigation. The aim of the present review is to discuss the fracture of the surgical bur Zekrya, mainly associated with the lower third molar section. Sometimes, fragments of burs not seen during the surgery can cause complications, such as discomfort and infection after the procedure. Metal fragments left in situ can also be encapsulated by fibrous tissue and gain access to adjacent spaces when recognized by the host as a foreign body. Breakage of any instrument implies searching for the fractured fragment and removing it since the trapped foreign body material is also capable of affecting the nerve and causing paroxysmal pain, continuous pain, or paresthesia, which can be felt in the nerve distribution area. According to the ethical code, if an unexpected accident occurs during the surgical procedure, such as the fracture of the instruments mentioned above, the patient must be informed, and the necessary measures must be taken to solve the problem.

KEYWORDS: *foreign bodies, tooth extraction, intraoperative complications, iatrogenic disease*

INTRODUCTION

Extraction is a standard dental surgical procedure. However, during the extraction of the dental element, various types of complications associated with local anesthesia, damage to nearby structures, and fracture and migration of instruments, a frequent condition, especially during third molar surgery (1), are possible.

Received: 05 May 2024

Accepted: 28 May 2024

ISSN 2975-1276 [online]

Copyright © by BIOLIFE 2024

This publication and/or article is for individual use only and may not be further reproduced without written permission from the copyright holder. Unauthorized reproduction may result in financial and other penalties. Disclosure: All authors report no conflicts of interest relevant to this article.

Dental instruments, mainly surgical burs, tend to break during the surgical procedure for various reasons, including faulty manufacturing, stress, fatigue, rust, and poor handling (Table I, II). Metal fragments left *in situ* can be encapsulated by fibrous tissue when recognized by the host as a foreign body. They can be swallowed after insertion into a body cavity due to trauma or iatrogenic injury (2-4).

Table I. *Zekrya bur features.*

Long	28mm
Type of material	hard steel
Format type	Trunk-conical
Type of motor	High rotation
Clinical indication	Dental Section

Table II. *Causes of bur fractures.*

Instruments used	Intraoperative complications	Iatrogenic
<ul style="list-style-type: none"> • Faulty manufacturing; • Stress; • Fatigue; • Oxide; • Low quality; • Use time. 	<ul style="list-style-type: none"> • Bad driving; • Wrong movement; • Lack of adequate irrigation; • Difficulty looking; • Traumatic applications. 	<ul style="list-style-type: none"> • Operator technique; • Evaluation errors; • Inappropriate application of force.

High-speed handpiece drills have high cutting efficiency, and dentists should always be aware of the possibility of causing overheating, subcutaneous emphysema, or breakage. Using worn burs without performing the correct movement and/or associated lack of adequate irrigation can lead to fracture during surgery. Occasionally, bur fragments not observed during surgery can cause complications, such as discomfort and infection after the procedure (Table III; Fig. 1, 2) (5).

Table III. *Potential complications due to bur fragments.*

Intraoperative complications	<ul style="list-style-type: none"> • swallow the fragment; • fragment aspiration.
Postoperative complications	<ul style="list-style-type: none"> • access to adjacent spaces; • discomfort; • local inflammation; • infection; • edema; • pain; • granuloma formation due to foreign body; • destruction of adjacent tissues; • paroxysmal pain; • continuous pain; • paresthesia.

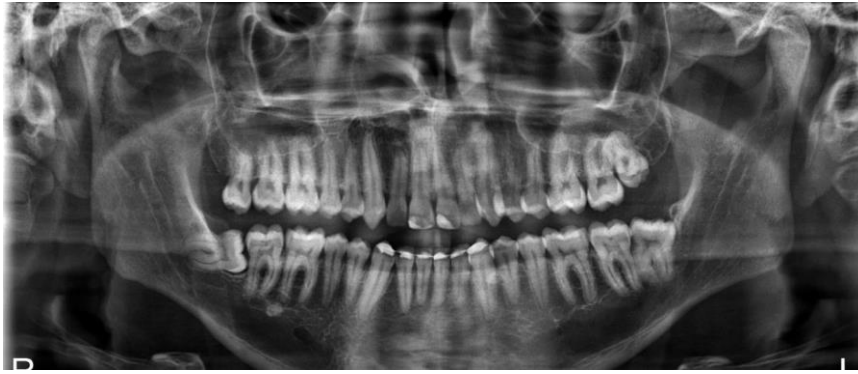

Fig. 1. Preoperative panoramic radiograph for lower and upper right third molar surgery.

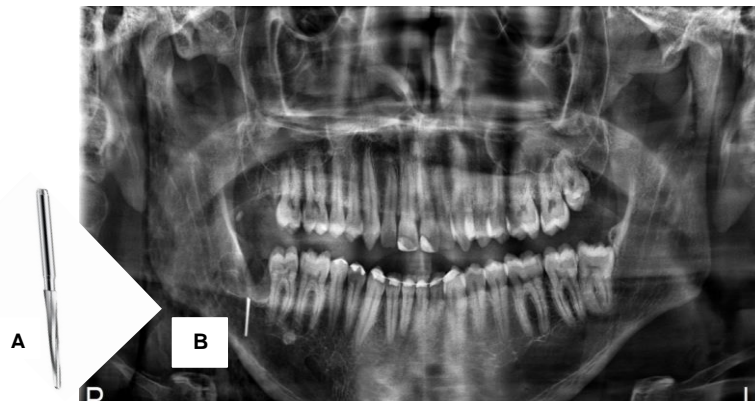


Fig. 2. A): Zekrya bur; B): Post-tooth extraction overview showing fracture of the surgical bur.

The breakage of any instrument involves searching for the fractured fragment and extracting it to avoid possible infection and prevent complications due to swallowing or aspiration of the fragment (3). Foreign body material left in hard or soft tissues can cause inflammation and local infection, a process related to pain and destruction of adjacent tissues (4). Trapped foreign bodies are also capable of affecting the nerve and causing paroxysmal pain, continuous pain, or paresthesia, which can be felt in the area of distribution of the nerve affected (6).

According to the ethical code, if an unexpected accident occurs during the surgical procedure, the patient must be informed, and necessary measures must be taken to solve the problem (3). Cone-Beam Computed Tomography (CBCT) is an excellent tool for identifying metallic objects. It has been proven to be a versatile technique for identifying foreign objects in their almost original structure and orientation (2). However, if CBCT is not available, panoramic radiography is a possibility to view and search for the fragment.

The objective of the present review was to discuss the Zekrya surgical bur fracture, which is mainly associated with the tooth section of the lower third molar.

MATERIALS AND METHODS

For the present study, even though it is not a systematic review, a search was carried out in PubMed/MEDLINE and VHL databases to guide the authors in identifying potential and relevant studies on the fracture of a truncated conical bur during the extraction procedure. The keywords used were “foreign body”, “broken instrument”, “Zekrya”, and “tooth extraction,” obeying the inclusion and exclusion criteria. The inclusion criteria were articles published in English in the last ten years (2010-2020); the exclusion criteria were articles that did not present an abstract, did not use Zekrya, and were published in a language other than English.

RESULTS

Initially, 217 articles were found in the databases. After applying the filters according to the eligibility criteria, 74 articles passed for the following phase. Five articles were wholly evaluated after careful reading and analysis (Fig. 3).

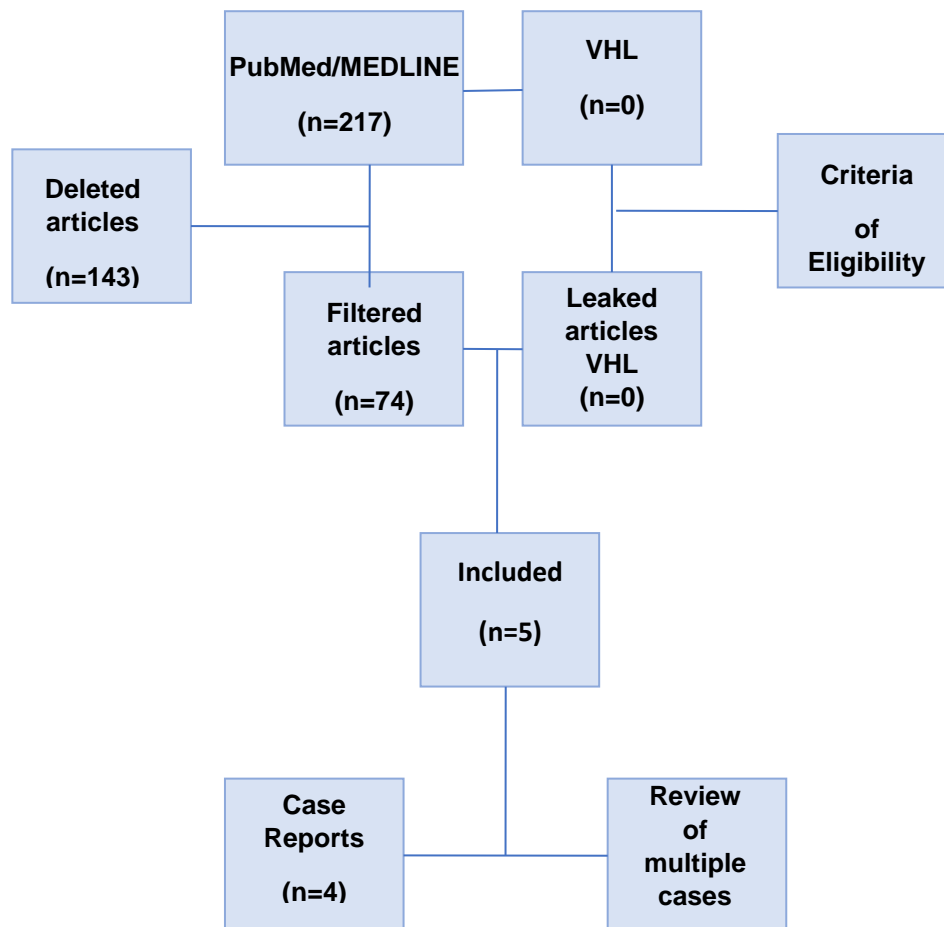


Fig. 3. The screening process was performed to include articles.

Accidents and complications can occur during surgery of impacted teeth due to several factors, including operator technique, aged or low-quality instruments, errors in evaluation, inappropriate application of force, and difficulty in visualization (3-5). One of the possible causes of instrument breakage during tooth extraction is metal fatigue due to excessive or incorrect sterilization, in addition to inappropriate applications (3).

The instruments are essential for the success of the extraction of an impacted tooth, considering the dependence of the osteotomy on the spherical surgical burs used for the exposure of the element, and the conical torso made of 702 steel and 28 mm Zekrya useful in tooth section. The surgical removal of impacted third molars is associated with a moderate incidence of complications, around 10%, a condition that includes fractures of the drill bit due to insufficient use or irrigation time and excessive use of force during the dislocation process with levers, which can culminate in breakage of the instrument. If a fracture occurs, it is in the patient's interest that the fragment be recovered since it can become surrounded by granulation tissue if left in place (3, 4).

DISCUSSION

Medical or dental materials that must be removed, such as gauze and pieces of broken instruments, are usually detected during surgery, and surgeons must attempt to remove them. When left in place, the patient may complain of symptoms such as swelling and pain associated with the infection (1-3). Neuropathic pain, as defined by the International Association for the Study of Pain (IASP), is initiated, or caused by a primary lesion or dysfunction in the nervous system; its continuous type can be caused by the imprisonment of foreign bodies in the mandibular and submandibular region,

which are quite common. These intraosseous entrapments can cause inflammation and granuloma formation due to a foreign body (5, 6).

Professionals are expected to be cautious, always using reliable and quality products and performing pre- and post-operative checks of the instruments (2). However, there is no end to the cases associated with iatrogenic foreign body migration, so when established in such a situation, oral and maxillofacial surgeons must perform extraction operations considering the degree of emergency based on the results of imaging tests. In this sense, some tools derived from technological progress, such as cone beam computed tomography, three-dimensional (3D) navigation, and image processing methods, have contributed to innovation in surgical procedures, thus leading to better visualization.

CONCLUSIONS

To avoid this complication in daily clinical practice, the professional must use quality and reliable products, always respecting their correct movement. Additionally, pre- and post-operative periods of surgical instruments should always be checked.

Conflict of interest statement

The authors declare no conflict of interest concerning this scientific article.

Financing

This study was not funded by any institution or company.

REFERENCES

1. Matsuda S, Yoshimura H, Yoshida H, Sano K. Breakage and migration of a high-speed dental hand-piece bur during mandibular third molar extraction. *Medicine*. 2020;99(7):e19177. doi:<https://doi.org/10.1097/md.00000000000019177>
2. Balaji S. Burried broken extraction instrument fragment. *Annals of Maxillofacial Surgery*. 2013;3(1):93. doi:<https://doi.org/10.4103/2231-0746.110076>
3. Miranda-Rius J, Brunet-Llobet L, Lahor-Soler E, Mrina O, Ramírez-Rámiz A. Dental root elevator embedded into a subgingival caries: a case report. *BMC Research Notes*. 2015;8(1):60. doi:<https://doi.org/10.1186/s13104-015-1011-5>
4. Kariya P, Elhammali N, Vorse K, Singh A. Management of iatrogenically exposed maxillary sinus with a broken periosteal elevator trapped inside. *Advances in Human Biology*. 2017;7(2):92. doi:https://doi.org/10.4103/aihb.aihb_44_16
5. De D, Neto A, Farias J. Artigo Clínico Técnicas cirúrgicas de extração em terceiros molares inclusos. *Brazilian Journal of Oral and Maxillofacial Surgery -BrJOMSS*. 2022;22(2):32-38. <https://www.revistacirurgiabmf.com/2022/02/Artigos/06ArtClinico.pdf>
6. Padmashree S, Ramprakash CH, Jayalekshmy R. Foreign Body Induced Neuralgia: A Diagnostic Challenge. *Case Reports in Dentistry*. 2013;2013:1-4. doi:<https://doi.org/10.1155/2013/352671>



Letter to the Editor

MEDICATION-RELATED OSTEONECROSIS OF JAW

K. Chatterjee¹, A. Banerjee^{1*}, S. Khan², R. Franco³, H. Uzunçibuk⁴, G. Cervino⁵ and G. Minervini^{6,7}

¹Department of Oral and Maxillofacial Pathology, Awadh Dental College and Hospital, Jamshedpur;

²Department of Oral Pathology, KGF College Of Dental Sciences And Hospital, Karnataka, India;

³Department of Biomedicine and Prevention, the University of Rome "Tor Vergata", Rome, Italy;

⁴Department of Orthodontics, Faculty of Dentistry, Trakya University, Edirne, Turkey;

⁵Dental Sciences and Morphofunctional Imaging, University of Messina, Policlinico "Gaetano Martino", Messina, Italy;

⁶Saveetha Dental College and Hospitals, Saveetha Institute of Medical and Technical Sciences (SIMATS), Saveetha University, Chennai, Tamil Nadu, India;

⁷Multidisciplinary Department of Medical-Surgical and Dental Specialties, University of Campania Luigi Vanvitelli, Naples, Italy

Correspondence to:

Abhishek Banerjee, MD

Department of Oral and maxillofacial pathology,

Awadh Dental College and Hospital,

NH-33, Danga, P.O. Bhilaipahar, Jamshedpur,

Jharkhand 831012, India

e-mail: abhishek.banerjee376@gmail.com

KEYWORDS: *bisphosphonates, medication-related osteonecrosis of jaw, antiresorptive, denosumab*

INTRODUCTION

Medication-related osteonecrosis of the jaws (MRONJ) primarily occurs as a complication of bone antiresorptive treatment in specific bone treatment modalities. It was first identified in 2003 as a bisphosphonate (BP) treatment complication. Denosumab is a molecule with a particular mode of action. This molecule inhibits bone resorption by suppressing osteoclast function. BPs have a strong affinity for hydroxyapatite crystals and remain in bone for years. The pathogenesis of MRONJ is not fully explained and appears multifactorial.

Hypotheses include impaired jaw bone vascularization due to antiangiogenic effects, altered bone remodeling, direct toxicity of BPs for soft tissue, specific infections, vitamin D deficiency, reduced salivation, constant jaw micro-traumas, and genetic factors. Patient education about oral cleanliness and maintenance becomes essential. Diagnosing and resolving any dental infection during antiresorptive treatment is essential to avoid harmful effects. Histological analysis of the resected bone is mandatory to rule out degenerative transformation.

When discussing antibiotics as a treatment form in this situation, the amoxicillin group of drugs may be considered for a brief interval. Oxygen in the hyperbaric mode has also been found to be a supportive therapy.

Osteonecrosis of the jaws is often known by historical names like "phossy jaw" due to its whitish appearance, which resembles phosphorus. It has been a subject of interest in oral and maxillofacial pathology since the 19th century (1-5).

Medication-related osteonecrosis of the jaws (MRONJ) primarily occurs as a complication of bone antiresorptive treatments. It was first identified in 2003 as a bisphosphonate (BP) treatment complication. MRONJ is not exclusive to bisphosphonate. Other enzyme inhibitors have been reported in this context. Many terminologies depicting this clinical

Received: 13 April 2024

Accepted: 16 May 2024

ISSN 2975-1276 [online]

Copyright © by BIOLIFE 2024

This publication and/or article is for individual use only and may not be further reproduced without written permission from the copyright holder. Unauthorized reproduction may result in financial and other penalties. Disclosure: All authors report no conflicts of interest relevant to this article.

condition have been mentioned in previous literature. Higher risk in MRONJ is identified as a significant adverse event associated with bisphosphonates (BP) and denosumab, primarily occurring in an oncological context (6-8).

Risk

The risk of developing MRONJ is significantly higher in cancer patients compared to osteoporosis patients. The prevalence of MRONJ in cancer patients receiving high doses of intravenous (IV) BP is noted to be less than 1%. The overall risk for MRONJ among cancer patients exposed to these categories of drugs is less than 7%. Patients with multiple myeloma receiving IV ZA (intravenous zoledronic acid) treatment are highlighted as having the highest risk, but there is a low risk in osteoporotic patients (9,10).

Medication and its mechanism of action

The medication works by blocking the enzymatic pathway for bone resorption, which affects bone metabolism. BPs exhibit both in vitro and in vivo antiangiogenic effects. This property is used in osteoporosis and cancer-related conditions such as bone metastases, multiple myeloma, and hypercalcemia of malignancy to reduce osteoporosis-related fractures and improve the quality of life in advanced cancers involving bones. All these groups of medications have a specific effect on the bone metabolic pathway (11-13).

Pathogenesis

The pathogenesis of MRONJ is not fully explained and appears multifactorial. Hypotheses include impaired jaw bone vascularization due to antiangiogenic effects, altered bone remodeling (14), direct toxicity of BPs for soft tissue, specific infections, vitamin D deficiency, reduced salivation, constant jaw micro-traumas, and genetic factors. In vivo, antiangiogenic effects of BPs may contribute to MRONJ by impairing post-interventional healing due to reduced blood vessel formation. Tooth extraction is a common triggering factor. However, MRONJ can also appear spontaneously (15).

Clinical features

The American Association of Oral and Maxillofacial Surgeons (AAOMS) criteria are often used for diagnosis. Characteristics include exposed bones persisting for more than two months with no other significant medical history in addition to these treatment methods. It is essential to differentiate this status from conditions like osteoradionecrosis, osteitis, malignancies, osteomyelitis, and fibro-osseous disease. There are a few other signs, like pain, altered neurosensory function, loosening of teeth, local swelling, infections, or halitosis.

Radiographic appearance

Radiographic findings include subperiosteal bone deposition, osteolysis, changes in trabecular pattern and densely woven bone. Histological examination is not mandatory for MRONJ diagnosis but is typically performed after surgical resection. Necrotic non-viable bone, necrosis, fibrosis of marrow spaces, hypocellularity, hypovascularity, fibrotic mucosa, and periosteum are present. Potential complications include repeated infections, fistulae, and pathologic fractures. In a few cases, spontaneous healing is seen, often after eliminating the bony sequestra (16).

It has been reported that panoramic radiography can provide an immediate view of the lesion. However, this method is not advantageous in detecting early bony changes and other features of MRONJ, such as fragmentation of bone and sinus communication (17).

Prevention protocol

Doctors should delay antiresorptive therapy until dental treatment is completed, including replacing or modifying ill-fitting dentures. Routinely checking oral hygiene is necessary to assess the risk. Diagnosing and resolving any dental infection during antiresorptive treatment is also a requirement.

Tooth extraction must be performed. Individual risk estimation for tooth extraction, considering parameters related to the patient, has to be well evaluated in advance, and the planned procedure can then be executed. Temporary discontinuation of therapy has been previously recommended for osteoporosis patients before and after invasive dental surgery, but current evidence on altering MRONJ risk is inconclusive.

If root fragments or crowns are present in the oral cavity, they should be addressed to curb the risk after the therapy is underway. The placement of dental implants is contraindicated. No evidence supports discontinuing IV BP therapy before invasive dental treatment (18).

Denosumab is associated with a faster reversal of antiresorptive effects compared to BPs. The potential for a six-month drug holiday before invasive dental procedures is suggested, but evidence is lacking in the literature.

Surgical procedures should be performed with caution, associated with antibacterial mouthwash before and after surgery, along with prophylactic oral antibiotics. Quadrant-by-quadrant procedures with a two-month delay between them, minimizing trauma, achieving primary closure, and minimizing vasoconstrictor use are recommended (19).

Treatment

Conservative therapy is the primary approach, aiming to control pain and infection and minimize the progression of bone osteonecrosis. While conservative therapy may not completely resolve the lesion, it can provide long-term relief from symptoms. The objectives include controlling pain and infection. Efforts are made to minimize the progression of bone osteonecrosis.

Discontinuation of antiresorptive treatment is mandatory in the development of MRONJ. Regardless of the disease stage, improving oral hygiene and patient education are mandatory. The initial stage is related to symptoms like unexplained pain, altered neurosensory function, and unexplained tooth loosening. Features of radiography vary and need to be appropriately evaluated (6).

Establishing clinical diagnosis and stage with instrumentation of advised protocol for lesions standing on for over two months is of paramount importance. Surgical removal of necrotic bone sequestrum should be considered, preferably without exposing uninvolved bone. With the advancements in the surgical field, surgery is now possible at any disease stage.

When conservative methods fail, surgery becomes the only option to preserve the important bony structure for subsequent structural and functional rehabilitation. Histological analysis of the resected bone is mandatory to rule out malignant transformation.

Antibiotic therapy of the penicillin group, such as amoxicillin and clavulanic acid, is the first-line treatment for infections (20). Oxygen in the hyperbaric form has been tried along with several other methods.

CONCLUSIONS

Osteonecrosis of the jaws depicts fatality and leads to a poor quality of life. The medications and the pathways associated with MRONJ must be studied in depth. Retrospective analysis of the cases and histopathological correlation may contribute to a better treatment outcome. The topic of osteonecrosis is explored by dental surgeons and oral specialists.

REFERENCES

1. Minervini G, Franco R, Marrapodi MM, Fiorillo L, Cervino G, Cicciù M. The association between parent education level, oral health, and oral-related sleep disturbance. An observational cross-sectional study. *European Journal of Paediatric Dentistry*. 2023;24(3):218-223. doi:<https://doi.org/10.23804/ejpd.2023.1910>
2. Inchingolo F, Tatullo M, Marrelli M, et al. Clinical trial with bromelain in third molar exodontia. *European Review for Medical and Pharmacological Sciences*. 2010;14(9):771-774.
3. Inchingolo F, Tatullo M, Pacifici A, et al. Use of dermal-fat grafts in the post-oncological reconstructive surgery of atrophies in the zygomatic region: clinical evaluations in the patients undergone to previous radiation therapy. *Head & face medicine*. 2012;8(1). doi:<https://doi.org/10.1186/1746-160x-8-33>
4. Kün-Darbois JD., Fauvel F. Medication-related osteonecrosis and osteoradionecrosis of the jaws: Update and current management. *Morphologie*. 2020;105(349). doi:<https://doi.org/10.1016/j.morpho.2020.11.008>
5. Minervini G, Franco R, Marrapodi MM, Almeida LE, Ronsivalle V, Cicciù M. Prevalence of temporomandibular disorders (TMD) in obesity patients: A systematic review and meta-analysis. *Journal of oral rehabilitation*. 2023;50(12):1544-1553. doi:<https://doi.org/10.1111/joor.13573>
6. Ghidini G, Manfredi M, Giovannacci I, et al. Medication-related osteonecrosis of the jaw: risk factors in patients under biphosphonate versus patients under antiresorptive-antiangiogenic drugs. *Minerva Dental and Oral Science*. 2017;66(4). doi:<https://doi.org/10.23736/s0026-4970.17.04056-0>
7. Lund T, Gundesen MT, Vangsted AJ, et al. In multiple myeloma, monthly treatment with zoledronic acid beyond two years offers sustained protection against progressive bone disease. *Blood cancer journal*. 2024;14(1). doi:<https://doi.org/10.1038/s41408-024-01046-2>
8. Qi C, Sun Q, Xiao D, et al. Tetrahedral framework nucleic acids/hyaluronic acid-methacrylic anhydride hybrid hydrogel with antimicrobial and anti-inflammatory properties for infected wound healing. *International Journal of Oral Science/International journal of oral science*. 2024;16(1). doi:<https://doi.org/10.1038/s41368-024-00290-3>
9. Lončar Brzak B, Horvat Aleksijević L, Vindiš E, et al. Osteonecrosis of the Jaw. *Dentistry Journal*. 2023;11(1):23. doi:<https://doi.org/10.3390/dj11010023>
10. Zhao L, Lai Y, Jiao H, Huang J. Nerve growth factor receptor limits inflammation to promote remodeling and repair of

- osteoarthritic joints. *Nature communications*. 2024;15(1). doi:<https://doi.org/10.1038/s41467-024-47633-6>
11. Huang N, Wang P, Gong P, Huang B. The Progress in Reconstruction of Mandibular Defect Caused by Osteoradionecrosis. *Journal of Oncology*. 2023;2023:1-12. doi:<https://doi.org/10.1155/2023/1440889>
 12. Rasteniene R, Simenaite G, Zaleckas L, Aleksejuniene J. Non-odontogenic maxillofacial infections – a 17-years retrospective cohort study. *Oral and maxillofacial surgery*. 2023;28(1). doi:<https://doi.org/10.1007/s10006-023-01162-6>
 13. Shin JW, Kim JE, Huh KH, et al. Radiological manifestations and clinical findings of patients with oncologic and osteoporotic medication-related osteonecrosis of the jaw. *Scientific reports*. 2024;14(1). doi:<https://doi.org/10.1038/s41598-024-59500-x>
 14. Piattelli A, Scarano A, Piattelli M. Detection of alkaline and acid phosphatases around titanium implants: a light microscopical and histochemical study in rabbits. *Biomaterials*. 1995;16(17):1333-1338. doi:[https://doi.org/10.1016/0142-9612\(95\)91049-5](https://doi.org/10.1016/0142-9612(95)91049-5)
 15. Ciobanu GA, Camen A, Ionescu M, et al. Risk Factors for Medication-Related Osteonecrosis of the Jaw—A Binomial Analysis of Data of Cancer Patients from Craiova and Constanta Treated with Zoledronic Acid. *Journal of Clinical Medicine*. 2023;12(11):3747. doi:<https://doi.org/10.3390/jcm12113747>
 16. Polyane Mazucatto Queiroz, Karolina Castilho Fardim, Luiz A, Ricardo Alves Matheus, Pereira L. Texture analysis in cone-beam computed tomographic images of medication-related osteonecrosis of the jaw. *Imaging science in dentistry*. 2023;53(2):109-109. doi:<https://doi.org/10.5624/isd.20220202>
 17. Christoph Klingelhöffer, Manja Klingelhöffer, Steffen Müller, Ettl T, Ulrich Wahlmann. Can dental panoramic radiographic findings serve as indicators for the development of medication-related osteonecrosis of the jaw? *Dentomaxillofac Radiol*. 2016;45(5):20160065-20160065. doi:<https://doi.org/10.1259/dmfr.20160065>
 18. Pan J, Liu JY. Mechanism, prevention, and treatment for medication-related osteonecrosis of the jaws. *Hua Xi Kou Qiang Yi Xue Za Zhi = Huaxi Kouqiang Yixue Zazhi = West China Journal of Stomatology*. 2021;39(3):245-254. doi:<https://doi.org/10.7518/hxkq.2021.03.001>
 19. Akashi M, Wanifuchi S, Iwata E, et al. Differences between osteoradionecrosis and medication-related osteonecrosis of the jaw. *Oral and Maxillofacial Surgery*. 2017;22(1):59-63. doi:<https://doi.org/10.1007/s10006-017-0667-5>
 20. Wang Z, Xu J, Wan J, Zhang W, Wang Y, Du Y. Vascular Analysis of Soft Tissues Around the Bone Lesion in Osteoradionecrosis, Medication-Related Osteonecrosis, and Infectious Osteomyelitis of the Jaw. *The Journal of craniofacial surgery*. 2022;33(7):e750-e754. doi:<https://doi.org/10.1097/scs.00000000000008697>