



Review

ZEKRYA BUR FRACTURE DURING EXTRACTION: HOW CAN THIS TYPE OF COMPLICATION BE AVOIDED? A LITERATURE REVIEW

L. Gonçalves Ferreira¹, F. Britto de Melo Silva¹, A. Scarano², S.A. Gehrke³, G.V. de Oliveira Fernandes⁴ and R.F. De Brito Resende^{1,5}

¹Faculty of Dentistry, Universidad Federal Fluminense, Niterói, RJ, Brazil;

²Department of Innovative Technologies in Medicine & Dentistry, University of Chieti-Pescara, Chieti, Italy;

³Bioengineering department, Universidad Miguel Hernandez de Elche, Alicante, Spain;

⁴A.T. Still University – Missouri School of Dentistry & Oral Health, St. Louis, MO, U.S.A.;

⁵Faculty of Dentistry, Universidade Iguaçú, Nova Iguaçú, RJ, Brazil

Correspondence to:

Rodrigo Figueiredo de Brito Resende, DDS

Faculty of Dentistry,

Universidad Federal Fluminense,

R. Mario Santos Braga 28,

Centro, Niterói,

24020-140, Rio de Janeiro, Brazil

e-mail: resende.r@hotmail.com

ABSTRACT

Extractions are a recurrent dental surgical procedure. Occasionally, tooth extraction is not easy, and there is the possibility of several complications, including the fracture and migration of instruments, especially during surgery of third molars. Such conditions can be triggered by several factors, such as defective manufacturing, stress, fatigue, rust, poor handling, and the use of worn burs or inadequate irrigation. The aim of the present review is to discuss the fracture of the surgical bur Zekrya, mainly associated with the lower third molar section. Sometimes, fragments of burs not seen during the surgery can cause complications, such as discomfort and infection after the procedure. Metal fragments left in situ can also be encapsulated by fibrous tissue and gain access to adjacent spaces when recognized by the host as a foreign body. Breakage of any instrument implies searching for the fractured fragment and removing it since the trapped foreign body material is also capable of affecting the nerve and causing paroxysmal pain, continuous pain, or paresthesia, which can be felt in the nerve distribution area. According to the ethical code, if an unexpected accident occurs during the surgical procedure, such as the fracture of the instruments mentioned above, the patient must be informed, and the necessary measures must be taken to solve the problem.

KEYWORDS: *foreign bodies, tooth extraction, intraoperative complications, iatrogenic disease*

INTRODUCTION

Extraction is a standard dental surgical procedure. However, during the extraction of the dental element, various types of complications associated with local anesthesia, damage to nearby structures, and fracture and migration of instruments, a frequent condition, especially during third molar surgery (1), are possible.

Received: 05 May 2024

Accepted: 28 May 2024

ISSN 2975-1276 [online]

Copyright © by BIOLIFE 2024

This publication and/or article is for individual use only and may not be further reproduced without written permission from the copyright holder. Unauthorized reproduction may result in financial and other penalties. Disclosure: All authors report no conflicts of interest relevant to this article.

Dental instruments, mainly surgical burs, tend to break during the surgical procedure for various reasons, including faulty manufacturing, stress, fatigue, rust, and poor handling (Table I, II). Metal fragments left *in situ* can be encapsulated by fibrous tissue when recognized by the host as a foreign body. They can be swallowed after insertion into a body cavity due to trauma or iatrogenic injury (2-4).

Table I. *Zekrya bur features.*

Long	28mm
Type of material	hard steel
Format type	Trunk-conical
Type of motor	High rotation
Clinical indication	Dental Section

Table II. *Causes of bur fractures.*

Instruments used	Intraoperative complications	Iatrogenic
<ul style="list-style-type: none"> • Faulty manufacturing; • Stress; • Fatigue; • Oxide; • Low quality; • Use time. 	<ul style="list-style-type: none"> • Bad driving; • Wrong movement; • Lack of adequate irrigation; • Difficulty looking; • Traumatic applications. 	<ul style="list-style-type: none"> • Operator technique; • Evaluation errors; • Inappropriate application of force.

High-speed handpiece drills have high cutting efficiency, and dentists should always be aware of the possibility of causing overheating, subcutaneous emphysema, or breakage. Using worn burs without performing the correct movement and/or associated lack of adequate irrigation can lead to fracture during surgery. Occasionally, bur fragments not observed during surgery can cause complications, such as discomfort and infection after the procedure (Table III; Fig. 1, 2) (5).

Table III. *Potential complications due to bur fragments.*

Intraoperative complications	<ul style="list-style-type: none"> • swallow the fragment; • fragment aspiration.
Postoperative complications	<ul style="list-style-type: none"> • access to adjacent spaces; • discomfort; • local inflammation; • infection; • edema; • pain; • granuloma formation due to foreign body; • destruction of adjacent tissues; • paroxysmal pain; • continuous pain; • paresthesia.

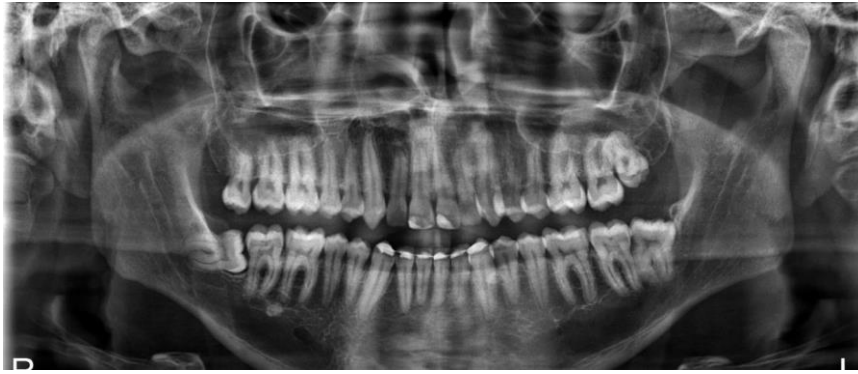


Fig. 1. Preoperative panoramic radiograph for lower and upper right third molar surgery.

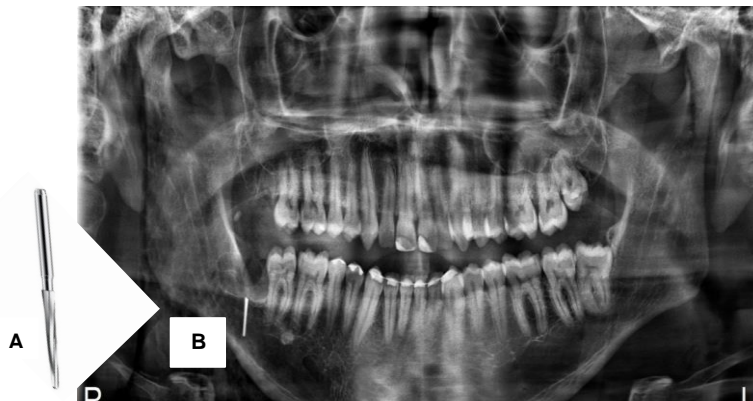


Fig. 2. A): Zekrya bur; B): Post-tooth extraction overview showing fracture of the surgical bur.

The breakage of any instrument involves searching for the fractured fragment and extracting it to avoid possible infection and prevent complications due to swallowing or aspiration of the fragment (3). Foreign body material left in hard or soft tissues can cause inflammation and local infection, a process related to pain and destruction of adjacent tissues (4). Trapped foreign bodies are also capable of affecting the nerve and causing paroxysmal pain, continuous pain, or paresthesia, which can be felt in the area of distribution of the nerve affected (6).

According to the ethical code, if an unexpected accident occurs during the surgical procedure, the patient must be informed, and necessary measures must be taken to solve the problem (3). Cone-Beam Computed Tomography (CBCT) is an excellent tool for identifying metallic objects. It has been proven to be a versatile technique for identifying foreign objects in their almost original structure and orientation (2). However, if CBCT is not available, panoramic radiography is a possibility to view and search for the fragment.

The objective of the present review was to discuss the Zekrya surgical bur fracture, which is mainly associated with the tooth section of the lower third molar.

MATERIALS AND METHODS

For the present study, even though it is not a systematic review, a search was carried out in PubMed/MEDLINE and VHL databases to guide the authors in identifying potential and relevant studies on the fracture of a truncated conical bur during the extraction procedure. The keywords used were “foreign body”, “broken instrument”, “Zekrya”, and “tooth extraction,” obeying the inclusion and exclusion criteria. The inclusion criteria were articles published in English in the last ten years (2010-2020); the exclusion criteria were articles that did not present an abstract, did not use Zekrya, and were published in a language other than English.

RESULTS

Initially, 217 articles were found in the databases. After applying the filters according to the eligibility criteria, 74 articles passed for the following phase. Five articles were wholly evaluated after careful reading and analysis (Fig. 3).

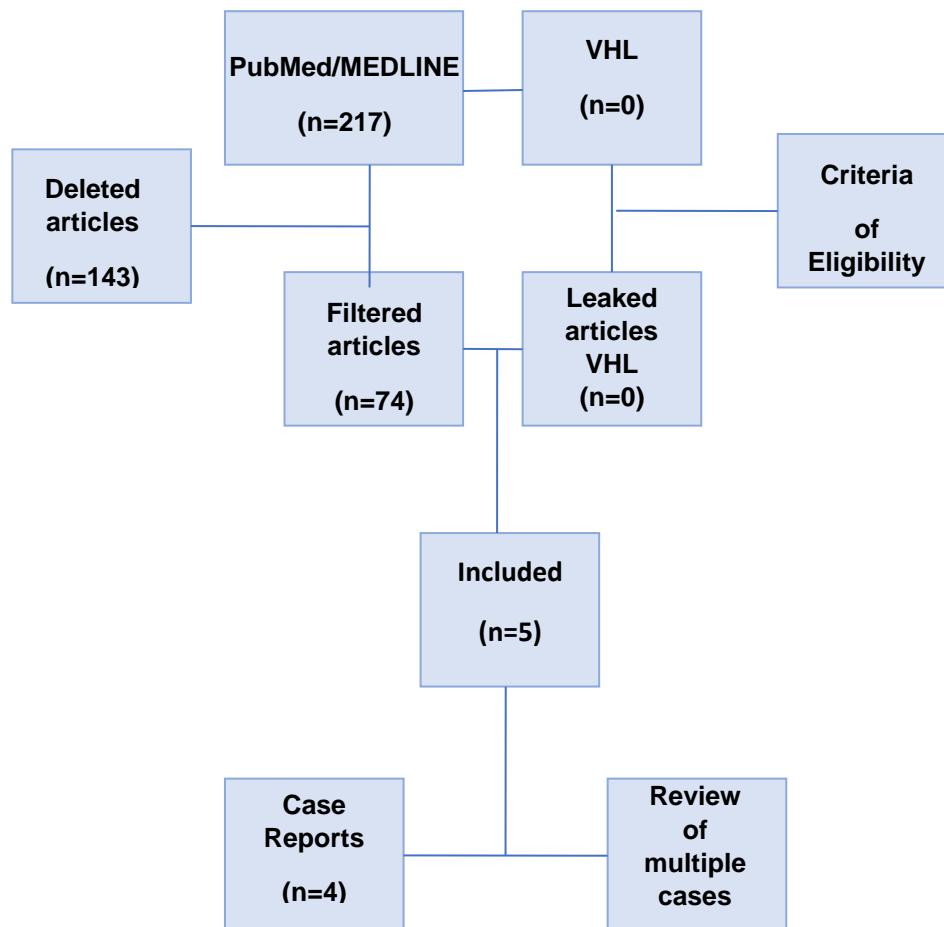


Fig. 3. The screening process was performed to include articles.

Accidents and complications can occur during surgery of impacted teeth due to several factors, including operator technique, aged or low-quality instruments, errors in evaluation, inappropriate application of force, and difficulty in visualization (3-5). One of the possible causes of instrument breakage during tooth extraction is metal fatigue due to excessive or incorrect sterilization, in addition to inappropriate applications (3).

The instruments are essential for the success of the extraction of an impacted tooth, considering the dependence of the osteotomy on the spherical surgical burs used for the exposure of the element, and the conical torso made of 702 steel and 28 mm Zekrya useful in tooth section. The surgical removal of impacted third molars is associated with a moderate incidence of complications, around 10%, a condition that includes fractures of the drill bit due to insufficient use or irrigation time and excessive use of force during the dislocation process with levers, which can culminate in breakage of the instrument. If a fracture occurs, it is in the patient's interest that the fragment be recovered since it can become surrounded by granulation tissue if left in place (3, 4).

DISCUSSION

Medical or dental materials that must be removed, such as gauze and pieces of broken instruments, are usually detected during surgery, and surgeons must attempt to remove them. When left in place, the patient may complain of symptoms such as swelling and pain associated with the infection (1-3). Neuropathic pain, as defined by the International Association for the Study of Pain (IASP), is initiated, or caused by a primary lesion or dysfunction in the nervous system; its continuous type can be caused by the imprisonment of foreign bodies in the mandibular and submandibular region,

which are quite common. These intraosseous entrapments can cause inflammation and granuloma formation due to a foreign body (5, 6).

Professionals are expected to be cautious, always using reliable and quality products and performing pre- and post-operative checks of the instruments (2). However, there is no end to the cases associated with iatrogenic foreign body migration, so when established in such a situation, oral and maxillofacial surgeons must perform extraction operations considering the degree of emergency based on the results of imaging tests. In this sense, some tools derived from technological progress, such as cone beam computed tomography, three-dimensional (3D) navigation, and image processing methods, have contributed to innovation in surgical procedures, thus leading to better visualization.

CONCLUSIONS

To avoid this complication in daily clinical practice, the professional must use quality and reliable products, always respecting their correct movement. Additionally, pre- and post-operative periods of surgical instruments should always be checked.

Conflict of interest statement

The authors declare no conflict of interest concerning this scientific article.

Financing

This study was not funded by any institution or company.

REFERENCES

1. Matsuda S, Yoshimura H, Yoshida H, Sano K. Breakage and migration of a high-speed dental hand-piece bur during mandibular third molar extraction. *Medicine*. 2020;99(7):e19177. doi:<https://doi.org/10.1097/md.00000000000019177>
2. Balaji S. Buried broken extraction instrument fragment. *Annals of Maxillofacial Surgery*. 2013;3(1):93. doi:<https://doi.org/10.4103/2231-0746.110076>
3. Miranda-Rius J, Brunet-Llobet L, Lahor-Soler E, Mrina O, Ramírez-Rámiz A. Dental root elevator embedded into a subgingival caries: a case report. *BMC Research Notes*. 2015;8(1):60. doi:<https://doi.org/10.1186/s13104-015-1011-5>
4. Kariya P, Elhammali N, Vorse K, Singh A. Management of iatrogenically exposed maxillary sinus with a broken periosteal elevator trapped inside. *Advances in Human Biology*. 2017;7(2):92. doi:https://doi.org/10.4103/aihb.aihb_44_16
5. De D, Neto A, Farias J. Artigo Clínico Técnicas cirúrgicas de extração em terceiros molares inclusos. *Brazilian Journal of Oral and Maxillofacial Surgery -BrJOMSS*. 2022;22(2):32-38. <https://www.revistacirurgiabmf.com/2022/02/Artigos/06ArtClinico.pdf>
6. Padmashree S, Ramprakash CH, Jayalekshmy R. Foreign Body Induced Neuralgia: A Diagnostic Challenge. *Case Reports in Dentistry*. 2013;2013:1-4. doi:<https://doi.org/10.1155/2013/352671>