



Clinical Trial

IMMEDIATELY LOADED MINI DENTAL IMPLANTS AS OVERDENTURE RETAINERS: HISTOMORPHOMETRIC ANALYSIS OF IMPLANT RETRIEVED FROM MAN

S.R. Tari¹, S.A. Gehrke², A. Scarano^{1*}, G. Di Palma³ and P. Scarano¹

¹ Department of Innovative Technologies in Medicine & Dentistry, University of Chieti-Pescara, Italy;

²Department of Research, Bioface/PgO/UCAM, Montevideo, Uruguay, Department of Biotechnology, Universidad Católica de Murcia (UCAM), 30107 Murcia, Spain;

³University of Bari Italy

**Correspondence to:*

Antonio Scarano, DDS

University of Chieti-Pescara,

Via Dei Vestini 31,

66100 Chieti Italy

e-mail: ascarano@unich.it

ABSTRACT

The primary function of the dental implant is to transmit occlusal load to the bone with a non-submerged surgical procedure that provides the patient with a provisional restoration. Immediate loading is a clinical procedure in which the dental implant and prosthesis are placed simultaneously to restore the patient's ability to chew food correctly, smile, and speak. In this case report, we histologically examined an immediately loaded mini-implant used for overdenture. The patient reports receiving two mini dental implants (1.8 mm × 13 mm) in the mandibular interforaminal region two years ago. The implants were immediately loaded with pre-made overdentures. He complains of continuous prosthesis loosening, forcing him to replace the O-rings constantly. The clinical examination showed that the right implant was excessively inclined lingually. After evaluating the different treatment options, a decision is made with the patient to remove the implant and place a new one. Histological samples showed cortical bone with a small medullary space without epithelial cells or connective tissue. Human implants are essential for the long-term evaluation of implants subjected to functional loading. The results confirm clinical findings and help doctors choose the most suitable surgical technique for the patient.

KEYWORDS: *mini-implant, immediate loading, narrow implant, overdenture*

INTRODUCTION

Dental implants have been proven to be highly successful long-term rehabilitation options for edentulous or partial edentulous patients. They are currently the best prosthetic alternative in several clinical indications, with high survival and success rates (1).

Osseointegrated dental implant fruit the osseointegration process discovered by Brånemark and defined as “the structural, functional and direct connection between bone and dental surface” (2). One usually waits a healing period of

Received: 21 February 2024

Accepted: 24 March 2024

ISSN 2975-1276 [online]

Copyright © by BIOLIFE 2024

This publication and/or article is for individual use only and may not be further reproduced without written permission from the copyright holder. Unauthorized reproduction may result in financial and other penalties. Disclosure: All authors report no conflicts of interest relevant to this article.

several months before placing a prosthesis and then loading the implant. The primary function of the dental implant is to transmit occlusal load to the bone with a non-submerged surgical procedure that provides the patient with a provisional restoration. Immediate loading is a clinical procedure in which the dental implant and prosthesis are placed simultaneously to restore the patient's ability to chew food correctly, smile, and speak (3). In most cases, the prosthesis is applied from the patient's tooth within the same day of implant placement or 48 hours, which makes the process quick.

Many studies have been conducted in animal models, such as monkeys and dogs (1, 4), to identify the reasons for the success or failure of immediate-loading dental implant treatments.

All these studies make it possible to investigate aspects of peri-implant tissue healing and peri-implant disease development. Still, they have a low quality of evidence, and the results obtained from these studies could be automatically transposed to a human situation. It is unethical to perform randomised studies on men; for this reason, it is essential to evaluate the occasionally retrieved human implants. In some cases, it is necessary to remove the implant for prosthetic complications, prosthetics, misalignment, or other problems or be obtained as part of a research protocol approved by an Ethical Committee. Immediately loaded and removed implants are essential data for understanding the nature of the complex and soft tissues in contact with the implant. In this case report, we histologically examined an immediately loaded mini-implant used for overdenture.

CLINICAL CASE

Material and methods

The patient reports receiving two mini dental implants (1.8 mm × 13 mm) in the mandibular interforaminal region two years ago. The implants were immediately loaded with pre-made overdentures. He complains of continuous prosthesis loosening, forcing him to replace the O-rings constantly. The clinical examination showed that the right implant was excessively inclined lingually (Fig. 1).

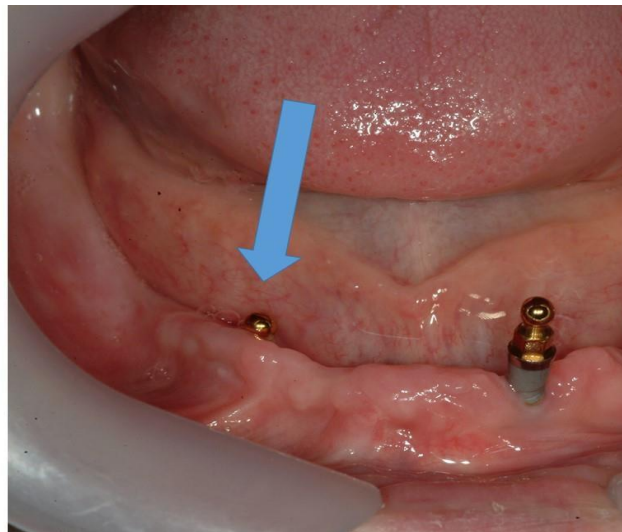


Fig. 1. *The implant was excessively inclined lingually (Arrow).*

Unfortunately, the position of the implant resulted in poor retention and premature wear of the O-rings. After evaluating the different treatment options, a decision was made with the patient to remove the implant and place a new one. Preoperatively, the patient was extensively informed concerning the surgical procedures. An attempt was made to unscrew the implant without success, so it was decided to remove it by performing a blok section with ultrasound (Esacrom, Imola-Italy).

Prior to surgery, the subject's mouth was rinsed with a chlorhexidine digluconate solution of 0.2% for 2 min. Local anesthesia was performed by Articaine® (Ubistesin 4% - Espe Dental AG Seefeld, Germany) with epinephrine 1:100.000. The blok section was stored in 10% buffered formalin and processed for histology and histomorphometry at the Implant Retrieval Centre, Dental School, University of Chieti-Pescara, Italy, to obtain thin ground sections with the Scan 1 Automated System (Pescara, Italy). The sample was dehydrated in an ascending series of alcohol rinses and embedded in a glycolmethacrylate resin (Technovit 7200 VLC, Kulzer, Wehrheim, Germany). After completion of the

polymerization process, each specimen was sectioned longitudinally along its major axis with a high-precision diamond disc at about 150 μm and ground down to about 30 μm . Three slides were obtained and stained with acid fuchsin and toluidine blue. The nomenclature approved by the American Society of Bone and Mineral Research was used to evaluate bone quality and histomorphometric measurements (5). It was observed in normal transmitted light under a Nikon microscope ECLIPSE (Nikon, Tokyo, Japan). The different hard tissues, medullary space, and biomaterials were carried out by a light microscope connected to a high-resolution video camera (16.25-megapixel) (Digital Sight series microscope cameras), interfaced to a high-definition monitor and a personal computer (Notebook Toshiba Satellite pro r50-c-15w). This optical system was associated with a histometry software package with image-capturing capabilities, then recorded using a Sony α 330 digital camera and subjected to morphometric analysis using digital image analysis (NIS-Elements AR 3.0 software, Nikon, Minato, Japan).

Results

At low magnification, the sample showed cortical bone with a small medullary space and without epithelial cells or connective tissue. No gap was observed between the bone and the implant at high magnification. No pathological inflammatory cell infiltrates or foreign body reactions were evident, and few osteoblasts were present in the specimens evaluated (Fig. 2).

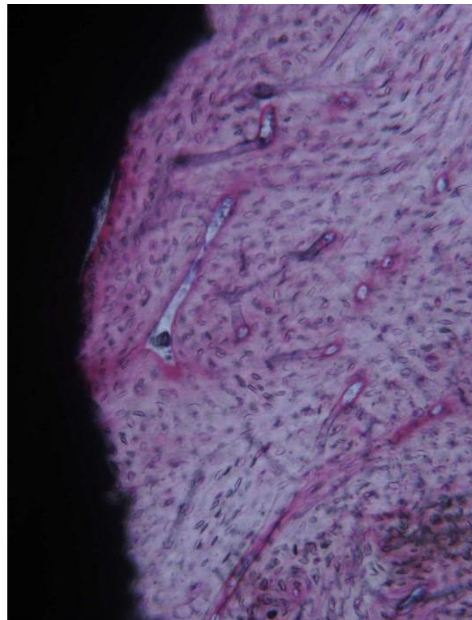


Fig. 2. Compact bone with small marrow spaces can be observed around the implant perimeter. The bone tissue is also located above the implant shoulder. Acid fuchsin-toluidine blue 40X.

DISCUSSION

Dental implants have become a successful and good option to enhance the stability and retention of complete dentures over resorbed ridges. Mini dental implants are a valid alternative to standard dental implants due to their small diameter, low primary costs, and avoidance of invasive treatments such as bone augmentation. They are usually used in elderly patients with various diseases or being treated with many drugs. The clinical outcomes of immediately loaded mini dental implants used as retainers for mandibular overdenture were recently investigated by different authors.

Scepanovic et al. reported a 98.3% implant success rate at the 1-year follow-up (6). The results in the present case report confirm the success rate of the mini-implant used for the mandibular overdenture. The outcome showed a high percentage of bone in direct contact with the implant. These histological results justify the high success rates reported by various authors (7, 8).

The initial stability of the mini implant is important for successful osteointegration and a high success rate. It depends upon the implant design, bone quality, and surgical technique used. The initial healing period of an implant is the phase of the osseointegration process that is primarily affected by the surface condition of the implant (9).

A cascade of biological events is initiated when an implant is placed into a bone site (10). Osteogenic cells are recruited and migrated to the implant surface. Immediate loading was clinically proposed more than 50 years ago when

Linkow et al. introduced endosseous blade implants (11). Piattelli and colleagues histologically demonstrated that immediately loaded implants achieve a very high BIC (12-16).

CONCLUSIONS

Histological evaluation is extremely important for the long-term evaluation of implants subjected to functional loading. For this reason, it is essential to analyse the removed implants histologically. The results confirm clinical findings and help doctors choose the most suitable surgical technique for the patient. Although we have described only one clinical case, the case report allows us to histologically confirm the validity of immediately loaded mini dental implants as overdenture retainers.

REFERENCES

1. Piattelli A, Paolantonio M, Corigliano M, Scarano A. Immediate loading of titanium plasma-sprayed screw-shaped implants in man: a clinical and histological report of two cases. *J Periodontol.* 1997;68(6):591-597. doi:https://doi.org/10.1902/jop.1997.68.6.591
2. Branemark PI, Adell R, Breine U, Hansson BO, Lindstrom J, Ohlsson A. Intra-osseous anchorage of dental prostheses. I. Experimental studies. *Scand J Plast Reconstr Surg.* 1969;3(2):81-100. doi:https://doi.org/10.3109/02844316909036699
3. Degidi M, Nardi D, Piattelli A. 10-year prospective cohort follow-up of immediately restored XiVE implants. *Clin Oral Implants Res.* 2016;27(6):694-700. doi:https://doi.org/10.1111/clr.12642
4. Blanco J, Linares A, Villaverde G, Perez J, Munoz F. Flapless immediate implant placement with or without immediate loading: a histomorphometric study in beagle dog. *J Clin Periodontol.* 2010;37(10):937-942. doi:https://doi.org/10.1111/j.1600-051X.2010.01608.x
5. Parfitt AM. Bone histomorphometry: standardization of nomenclature, symbols, and units (summary of proposed system). *Bone.* 1988;9(1):67-69. doi:https://doi.org/10.1016/8756-3282(88)90029-4
6. Šćepanović M, Todorović A, Marković A, et al. Immediately loaded mini dental implants as overdenture retainers: 1-Year cohort study of implant stability and peri-implant marginal bone level. *Ann Anat.* 2015;199:85-91. doi:10.1016/j.aanat.2013.12.005
7. Zygogiannis K, Aartman IH, Parsa A, Tahmaseb A, Wismeijer D. Implant Mandibular Overdentures Retained by Immediately Loaded Implants: A 1-Year Randomized Trial Comparing the Clinical and Radiographic Outcomes Between Mini Dental Implants and Standard-Sized Implants. *Int J Oral Maxillofac Implants.* 2017;32(6):1377-1388. doi:https://doi.org/10.11607/jomi.5981
8. Aunmeungtong W, Kumchai T, Strietzel FP, Reichart PA, Khongkhunthian P. Comparative Clinical Study of Conventional Dental Implants and Mini Dental Implants for Mandibular Overdentures: A Randomized Clinical Trial. *Clin Implant Dent Relat Res.* 2017;19(2):328-340. doi:https://doi.org/10.1111/cid.12461
9. Skiba THI, Kalil EC, Piattelli A, Shibli JA. Human Histological Analysis of Early Bone Response to Immediately Loaded Narrow Dental Implants with Biphasic Calcium Phosphate((R)) Grid-Blasted Surface Treatment: A Case Report. *Dent J (Basel).* 2023;11(7):doi:https://doi.org/10.3390/dj11070177
10. Inchingolo F, Inchingolo AM, Latini G, et al. Application of Graphene Oxide in Oral Surgery: A Systematic Review. *Materials (Basel).* 2023;16(18):doi:https://doi.org/10.3390/ma16186293
11. Linkow LI, Miller RJ. Immediate loading of endosseous implants is not new. *J Oral Implantol.* 2004;30(5):314-317. doi:https://doi.org/10.1563/0683.1
12. Piattelli A, Corigliano M, Scarano A, Costigliola G, Paolantonio M. Immediate loading of titanium plasma-sprayed implants: an histologic analysis in monkeys. *J Periodontol.* 1998;69(3):321-327. doi:https://doi.org/10.1902/jop.1998.69.3.321
13. Piattelli A, Corigliano M, Scarano A, Quaranta M. Bone reactions to early occlusal loading of two-stage titanium plasma-sprayed implants: a pilot study in monkeys. *Int J Periodontics Restorative Dent.* 1997;17(2):162-169.
14. Degidi M, Artese L, Piattelli A, et al. Histological and immunohistochemical evaluation of the peri-implant soft tissues around machined and acid-etched titanium healing abutments: a prospective randomised study. *Clin Oral Investig.* 2012;16(3):857-866. doi:https://doi.org/10.1007/s00784-011-0574-3
15. Degidi M, Scarano A, Iezzi G, Piattelli A. Histologic analysis of an immediately loaded implant retrieved after 2 months. *J Oral Implantol.* 2005;31(5):247-254. doi:https://doi.org/10.1563/1548-1336(2005)31[247:HAOAIL]2.0.CO;2
16. Scarano A, Murmura G, Carinci F, Lauritano D. Immediately loaded small-diameter dental implants: Evaluation of retention, stability and comfort for the edentulous patient. *European Journal of Inflammation.* 2021;10(19-23).