



---

## Editorial

In the last decade, a significant increase in scientific publications has been detected in literature, with over 479,000 articles on the Scopus index with “dentistry” as the subject area, representing an increase of about 55% compared to the previous period from 2012 to 2002. The scientific production inflation is reflected in a total of 157 scientific journals classified with the “dentistry, oral surgery & medicine” category on Journal Citation Report (Clarivate) with a median impact factor of 2.6 on Science Citation Index Expanded (SCIE database) and 0.8 on Emerging Sources Citation Index (ESCI).

The *Annals of Stomatology* is a novel international peer-reviewed journal committed to publishing high research papers regarding the different fields of dentistry, maxillofacial disease, and translational and regenerative medicine. The topic’s relevance has recently been confirmed by the World Health Organisation, which recently launched a formal Global Oral Health Action Plan for 2023-2030, recognising the relevance of oral disease in the healthcare and welfare system. In this way, the WHO recognised 3.2 billion patients suffering from oral disease, including teeth loss worldwide, in 2020. The WHO Council Agenda determined six different strategic fields focused on the public dental healthcare properties: governance, oral health promotion and prevention, health workforce, oral health care, information systems and research; this confirms the vital role played by the mouth in the aesthetics and function of the individual, in his social relationships and complete self-acceptance in the different phases of human existence.

The recent insights in regenerative dentistry and biomedicine are emerging promising advances in implant device surfaces, bioactive materials and tissue engineering that can improve biological responses and oral tissue healing.

Novel targets have been determined by identifying new-generation materials promoting bone tissue response and rehabilitation predictability. In this way, dental implant rehabilitation represents a highly debated topic in line with the bibliometric spread of the dentistry area concerning innovative medical devices, clinical protocols, predictability, long-term outcomes and complications. The importance of this field is immediately clarified by the dimension of the worldwide dental implant market valued at 4.15 billion USD in 2022.

On the other hand, the journal’s purpose will be to produce a significant translational impact on the scientific knowledge in dental clinical practice. The interdisciplinarity will be a consistent component of the editorial line, especially with the dental innovations and emerging issues in this field with high evidence. The different topic areas will be addressed considering innovative, original research, including full papers, clinical case reports, systematic reviews, randomised clinical trials, cohort and pilot studies, and editorials through a high-quality peer review by a qualified, respectable expert.

An Editorial Board will define the journal’s scientific line and orientation with a respectable international membership, and the Editor-in-Chief will preliminarily evaluate the manuscript’s suitability for publication. The peer review will be conducted through at least two double-blind expert reviewers with full respect to the journal’s ethical transparency policy.

The journal’s goal will be to maintain a rapid correspondence with authors, reducing any delay of the review processing no more than one month from the submission process in full respect to the quality content expectation of the scientific products. Particular attention will be given to the ethical and methodological aspects of the study proposal, the adherence to the Good Clinical Practice Guidelines and the data availability of the experiments. Also, any conflict of interest will be managed and declared in the publications to maintain the journal policy’s high transparency.

---

Copyright © by BIOLIFE 2023

This publication and/or article is for individual use only and may not be further reproduced without written permission from the copyright holder. Unauthorized reproduction may result in financial and other penalties. **Disclosure: All authors report no conflicts of interest relevant to this article.**

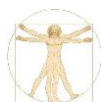ISSN 2975-1276

The Editorial Board plays a pivotal role in shaping the content and direction of the *Annals of Stomatology*; a journal focused on staying at the forefront of the ever-evolving medical field. Their responsibility includes keeping abreast of current trends and emerging global issues within the healthcare system, all while adhering to the principles of evidence-based medicine and evidence-based dentistry.

Their dedication to these principles and the dynamic nature of medical science instill confidence in the potential for rapid success and widespread recognition of the *Annals of Stomatology*.

We extend our best wishes to the journal and its Editorial Board, hoping for continued achievements and valuable contributions to the field of stomatology.

EDITOR-IN-CHIEF  
Prof. Antonio Scarano MD, DDS  
Full Professor in Dentistry



Original Article

## ELECTROMYOGRAPHIC ANALYSIS OF PATIENTS DURING ORTHODONTIC TREATMENT WITH F22 ALIGNER

A. Fantauzzo and G. Kussini

Postgraduate School of Orthodontics, University of Ferrara, Ferrara, Italy

Correspondence to:

A. Fantauzzo, DDS

Postgraduate School of Orthodontics,

University of Ferrara,

Via Luigi Borsari 46,

Ferrara 44121, Italy.

e-mail: [alessandro\\_fantauzzi@yahoo.it](mailto:alessandro_fantauzzi@yahoo.it)

### ABSTRACT

The aim of this research paper is to investigate the electromyographic behavior of the elevator, masseter and temporal muscles, during the orthodontic treatment with aligners (F22). The subjects were 8 healthy adult patients between 20-40 years of age. EMG carried out at the beginning of the therapy (T0) and after each month (T1, T2, T3) with and without aligners (F22). In the statistical analysis, for each measure, a repeated measures ANOVA with post-hoc tests was used. The post-hoc tests show that the impact of the appliance is significant only at time T0. After an initial elevation, a subsequent lowering of the electromyographic values of the muscles Masseter and Temporal in patients wearing aligners (with F22 systematics) could suggest an adaptation of the entire stomatognathic system.

**KEYWORDS:** *clear aligners, F22, electromyography, EMG*

### INTRODUCTION

Electromyography is a technique that deals with capturing, measuring and analyzing an electrical signal made by the muscles, in unfavorable conditions. The reference measurement inherent to this muscle “discharge” is expressed in microvolts ( $\mu$ Volts) of very low intensity (1). Electromyography arises between biology and physics, and only the technological development of recent years has allowed it to become a discipline capable of contributing fully to the knowledge of neuromuscular physiology, so as to provide a valid aid for the diagnosis of numerous pathologies of nerves and muscles (2).

Received: 16 January 2023

Accepted: 28 February 2023

Copyright © by BIOLIFE 2023

This publication and/or article is for individual use only and may not be further reproduced without written permission from the copyright holder. Unauthorized reproduction may result in financial and other penalties. **Disclosure: All authors report no conflicts of interest relevant to this article.**

ISSN 2975-1276

The theory of Neuromuscular Occlusion recognizes the role of muscles as *primum movens* in the functional physiology of the stomatognathic system, influences the muscle heads and actively uses TENS (Transcutaneous Electrical Nerve Stimulation) (3), B. Jankelson in 1969 (4) began to use the patient's muscles to be pointed the physiological centric position, in 1975, with the mandibular kinesiograph he began to measure the different mandibular positions for the different functions and the different resting positions before and after TENS (5). The development of this tool, further modified the diagnostic protocol developed by Jankelson over the years (6).

Some studies (7-9) have shown that the use of these devices can reduce the parafunctional activity, which often appears in times of stress. There is also a disparity of views regarding the influence of the type of material (rigid or resilient) on the neuromuscular response of individual patients (10,11).

In the literature, studies have been reported to date concerning the muscular response of patients undergoing therapies carried out with rigid splints, or with disclusion plates, in any case devices that do not have a selectively orthodontic effect, but only of partial coverage or of the entire dental arch. As there is an increasing interest about esthetics and the use of these methods even in challenging cases (12-14), we tried to evaluate the behavior of these muscles during the first stages of orthodontic treatment with aligners (F22).

## MATERIALS AND METHODS

From examining 8 patients from the Clinic of the School of Specialization in Orthodontics of the University of Ferrara, all adults, aged between 20 and 40 years, with the absence of periodontal, dental and joint temporomandibular and / or muscular pathologies in progress. Were used: K7 kinesiographic assessment system, produced by MYO-TRONICS inc., eight-channel electromyographic evaluation MYO-TRONICS inc., DUOTRODES dedicated bipolar electrodes, in silver / chloride for electromyography, pre-coated with gel, Aligners F22. Each session included 6 measurements (scans) of 15 seconds each, in particular, 3 scans with aligners worn and 3 scans without. A statistical analysis was then performed on a data set consisting of 8 on which four electromyographic measurements relating to individual muscle were measured over four times (0, 1, 2, 3), Left Anterior Temporal Muscle (LTA), Temporal Right Anterior (RTA), Left Masseter (LMM) and Right Masseter (RMM), with or without the presence of appliance (NO / YES). The purpose of the analysis is to verify whether and how the variations in measurements with or without a device change over time. To carry out the statistical analysis, for each measure, a repeated measures ANOVA with post-hoc tests was used.

Furthermore, the statistical software R (R Core Team 2016) and the packages *lsmeans* (Lenth 2016) and *nlme* (Pinheiro et al. 2016) were used.

The reference significance thresholds used are the following: weak (p-value between 10% and 5%), standard (p-value between 5% and 1%), strong (p-value less than 0.001).

For each measure the following are reported: the descriptive statistics (number of observations, mean, minimum and maximum standard deviation) by combination of time and device, as well as the graph. The results of the multiple measures ANOVA test which indicate, by means of the p-value, the significance of respectively: time effect, means that the measures change over time; appliance effect, if generally the presence (YES) or absence (NO) of the aligner changes the measurement; interaction effect, if the appliance effect changes over time. The post hoc analysis, means estimation of the YES / NO variation effect of the device on the measurement as time changes and related post-hoc confidence intervals.

## RESULTS

### Left temporal muscle (LTA)

The table shows the statistic variable for the LTA. Average value of 8 patients for the left temporal muscle

Muscle	Time of treatment	Wearing aligners	Number of patients	Average	Standard deviation	Min	Max
LTA	0	NO	8	3.6	1.7	1.5	7.1
LTA	0	YES	8	4.7	2.6	2.0	10.7
LTA	1	NO	8	3.7	1.6	1.5	7.2
LTA	1	YES	8	3.6	2.7	1.3	10.0
LTA	2	NO	8	3.7	1.7	1.4	7.3
LTA	2	YES	8	3.7	3.0	1.2	11.0
LTA	3	NO	8	3.7	1.6	1.5	7.2
LTA	3	YES	8	3.4	2.2	1.2	8.6

The post - hoc tests are reported below, showing that the impact of the appliance is only significant at time 0

Measure	Time	Difference	Estimate	p-value
LTA	0	NO - YES	-1.15	0.002515
LTA	1	NO - YES	0.0625	0.8582
LTA	2	NO - YES	-0.004167	0.9905
LTA	3	NO - YES	0.2458	0.4839

### Left temporal muscle (RTA)

The table shows the statistic variable for the RTA. Average value of 8 patients for right temporal muscle

Muscle	Time of treatment	Wearing aligners	Number of patients	Average	Standard deviation	Min	Max
RTA	0	NO	8	4.4	2.6	1.6	8.8
RTA	0	YES	8	6.1	4.2	2.0	14.1
RTA	1	NO	8	4.4	2.7	1.6	9.3
RTA	1	YES	8	4.4	3.9	1.3	13.0
RTA	2	NO	8	4.5	2.7	1.6	9.4
RTA	2	YES	8	4.4	3.8	1.3	13.1
RTA	3	NO	8	4.5	2.6	1.7	9.1
RTA	3	YES	8	4.4	3.5	1.5	11.8

The post - hoc tests are reported below, showing that the impact of the appliance is only significant at time 0

Measure	Time	Difference	Estimate	p-value
RTA	0	NO - YES	-1.712	0.0008049
RTA	1	NO - YES	-25	0.9567
RTA	2	NO - YES	0.04167	0.9278
RTA	3	NO - YES	0.06667	0.8848

Left masseter muscle (LMM)

The table shows the statistic variable for the LMM. Average value of 8 patients for the left temporal muscle

Muscle	Time of treatment	Wearing aligner	Number of patient	Average	Standard deviation	min	max
LMM	0	NO	8	2.8	1.3	1.7	5.9
LMM	0	YES	8	3.6	2.0	2.2	8.3
LMM	1	NO	8	3.0	1.4	1.8	6.2
LMM	1	YES	8	2.9	2.1	1.5	7.9
LMM	2	NO	8	3.0	1.4	1.8	6.2
LMM	2	YES	8	3.1	2.4	1.5	8.8
LMM	3	NO	8	3.2	2.1	1.8	8.1
LMM	3	YES	8	3.3	2.7	1.4	9.8

The post - hoc tests are reported below, showing that the impact of the appliance is only significant at time 0

LMM, time average variation

Contrast	Estimate	SE	df	t.ratio	p-value
0 - 1	0.5312	0.245	21	2.168	0.1648
0 - 2	0.4854	0.245	21	1.981	0.2265
0 - 3	0.5979	0.245	21	2.44	0.0999
1 - 2	-0.04583	0.245	21	-0.1871	0.9976
1 - 3	0.06667	0.245	21	0.2721	0.9927
2 - 3	0.1125	0.245	21	0.4592	0.9671

Right masseter muscle (RMM)

The table shows the statistic variable for the RMM. Average value of 8 patients for right masseter muscle

Muscle	Time of treatment	Wearing aligners	Number of patients	Average	Standard deviation	Min	Max
RMM	0	NO	8	3.6	2.4	1.8	7.7
RMM	0	YES	8	4.7	3.5	2.3	10.7
RMM	1	NO	8	3.6	2.4	1.7	8.0
RMM	1	YES	8	3.4	3.1	1.5	10.4
RMM	2	NO	8	3.7	2.5	1.8	8.2
RMM	2	YES	8	3.6	3.4	1.4	11.3
RMM	3	NO	8	3.7	2.4	1.8	8.0
RMM	3	YES	8	3.6	3.3	1.4	11.1

The post - hoc tests are reported below, showing that the impact of the appliance is only significant at time 0

RMM, post hoc table

Measure	Time	Difference	Estimate	p-value
RMM	0	NO - YES	-1.117	0.007261
RMM	1	NO - YES	0.1667	0.6689
RMM	2	NO - YES	0.05417	0.8893
RMM	3	NO - YES	0.02083	0.9573

## DISCUSSION

In the beginning of the orthodontic treatment with aligners (F22), there was an increase in electromyographic values: at the beginning of therapy with aligners (T0), in the condition of the appliance worn (values in microvolts rise, from “Wearing aligner” NO to “Wearing aligner” YES, in T0). In the subsequent phases of therapy (T1, T2 and T3), there was a lowering of the electromyographic values, wearing the aligners (values that drop from “Wearing device” NO to “Wearing device” YES, in T1, T2 and T3).

In the past, other authors have investigated the electromyographic behavior of the mandibular muscles, with particular reference to the Masseter and Temporal muscles. The results of these investigations essentially indicate that a skeletal expansion in the transverse plane of the maxilla generally causes an increase in the electromyographic activity of the muscles mentioned above (15,16), while we note that there are different results in studies that consider the trend of these electromyographic values measured in growing patients treated with functional devices

## CONCLUSION

The present research wanted to highlight, within the proposed limits, after an initial elevation, a subsequent lowering of the electromyographic values of the muscles Masseter and Temporal in patients wearing aligners (with F22 systematics).

The very stable electromyographic picture in the months following the start of therapy, could suggest an adaptation of the entire stomatognathic system

## REFERENCES

1. Bazzotti L. *L'Elettromiografia Cutanea*. Pecetto Torinese(TO),Officina Grafica la Collina, 1996.
2. Bazzotti L, Boschiero R. *Principi Di Occlusione Neuromuscolare*. Bologna, Ed. Grasso, 1991.
3. Cattaneo R, Monaco A. *Elettromiografia E Chinesiografia per La Clinica Odontoiatrica*. Ascoli Piceno, Futura Ed. 2007
4. Jankelson B, Swain CW, Crane PF, Radke JC. Kinesiometric instrumentation: a new technology. *Journal of the American Dental Association (1939)*. 1975;90(4):834-840. doi:10.14219/jada.archive.1975.0164
5. Matheson DW, Toben TP, de la Cruz DE. EMG scanning: Normative data. *Journal of Psychopathology and Behavioral Assessment*. 1988;10(1):9-20. doi:10.1007/bf00962981
6. Okeson PJ. *Il Trattamento Delle Disfunzioni Dell'occlusione E Dei Disordini Temporomandibolari*. V Edizione, Bologna, Ed. Martina, 2006.
7. Clark GT. Occlusal therapy: occlusal appliances. In: *The President's Conference on the Examination, Diagnosis and Management of Temporomandibular Disorders*. Chicago, 1983, American Dental Association, pp. 137-146.
8. Solberg WK, Clark GT, Rugh JD. Nocturnal electromyographic evaluation of bruxism patients undergoing short term splint therapy. *Journal of Oral Rehabilitation*. 1975;2(3):215-223. doi:10.1111/j.1365-2842.1975.tb00915.x
9. SHEIKHOESLAM A, HOLMGREN K, RIISE C. A clinical and electromyographic study of the long-term effects of an occlusal splint on the temporal and masseter muscles in patients with functional disorders and nocturnal bruxism. *Journal of Oral*

- Rehabilitation*. 1986;13(2):137-145. doi:10.1111/j.1365-2842.1986.tb00646.x
10. Botelho AL, Silva BC, Gentil FHU, Sforza C, da Silva MAMR. Immediate effect of the resilient splint evaluated using surface electromyography in patients with TMD. *Cranio: The Journal of Craniomandibular Practice*. 2010;28(4):266-273. doi:10.1179/crn.2010.034
  11. De la Torre Canales G, Manfredini D, Grillo CM, Guarda-Nardini L, Machado Gonçalves L, Rizzatti Barbosa CM. Therapeutic effectiveness of a combined counseling plus stabilization appliance treatment for myofascial pain of the jaw muscles: A pilot study. *Cranio*. 2016;35(3):180-186. doi:10.1080/08869634.2016.1168071
  12. Oliverio T, Cremonini F, Lombardo L, Siciliani G. Tooth Whitening in Association with Clear Aligner Treatment. *Journal of Clinical Orthodontics*. 2019;53(9):508-517.
  13. Lombardo L, Carlucci A, Palone M, Mollica F, Siciliani G. Stiffness comparison of mushroom and straight SS and TMA lingual archwires. *Progress in Orthodontics*. 2016;17(1). doi:10.1186/s40510-016-0140-2
  14. Lombardo L, Ceci M, Mollica F, Mazzanti V, Palone M, Siciliani G. Mechanical properties of multi-force vs. conventional NiTi archwires. *Journal of Orofacial Orthopedics*. 2019;80(2):57-67. doi:10.1007/s00056-018-00164-4
  15. Arat FE, Arat ZM, Acar M, Beyazova M, Tompson B. Muscular and condylar response to rapid maxillary expansion. Part 1: Electromyographic study of anterior temporal and superficial masseter muscles. *American Journal of Orthodontics and Dentofacial Orthopedics*. 2008;133(6):815-822. doi:10.1016/j.ajodo.2006.07.028
  16. De Rossi M, De Rossi A, Hallak JEC, Vitti M, Regalo SCH. Electromyographic evaluation in children having rapid maxillary expansion. *American Journal of Orthodontics and Dentofacial Orthopedics*. 2009;136(3):355-360. doi:10.1016/j.ajodo.2007.08.027





Original Article

# EVALUATION OF LONG-TERM STABILITY OF EDGEWISE ORTHODONTIC TECHNIQUE

E. Morin and L.P. Calcò

Postgraduate School of Orthodontics, University of Ferrara, Ferrara, Italy

Correspondence to:

Eugenia Morin, DDS

Postgraduate School of Orthodontics,

University of Ferrara,

Via Luigi Borsari 46,

Ferrara 44121, Italy

e-mail: morin.eugenia@gmail.com

## ABSTRACT

The relapse of teeth after orthodontic treatment has been a topic of ongoing interest for practitioners. The instability of the orthodontic treatment depends on different variables, such as the normal developmental maturation process of the maxillofacial complex. It is common to use posttreatment retentions to avoid a relapse, permanent or removable, depending on the previous malocclusion. The casts of 15 subjects treated with the edgewise technique between 1985 and 2000 were selected to evaluate dental arch changes among 17 years posttreatment. Time points were pretreatment (T1), posttreatment (T2) and follow-up (T3). The parameters considered were intercanine, interpremolar and intermolar width, dental arch length and crowding. The collected data were submitted for statistical analysis. The intercanine width outcome is the most significant, with the greater changes observed during the treatment among T1 and T2, maintained over time as the difference between T3 and T1 is statistically significant. The other parameter values were not statistically significant. Within the field of the edgewise technique, the intercanine width outcome is the most significant: greater changes from the pretreatment to the posttreatment condition led to more significant relapse.

**KEYWORDS:** *relapse, stability, edgewise technique, intercanine width*

## INTRODUCTION

The achievement of a good result was investigated over time and led to an improvement in materials, procedures, vestibular fixed appliance technique, and more esthetic treatments like aligners (1) and lingual orthodontics; this made possible even complex cases' treatments (2). However, a stable result over time is today a real challenge for the entire

Received: 04 January 2023

Accepted: 10 February 2023

Copyright © by BIOLIFE 2023

This publication and/or article is for individual use only and may not be further reproduced without written permission from the copyright holder. Unauthorized reproduction may result in financial and other penalties. **Disclosure: All authors report no conflicts of interest relevant to this article.**

ISSN 2975-1276

professional category. Therefore, different systems that could lead to the required results have been tested during these years, even applying light and continuous forces (3, 4).

Considering that less than 30% of treatment presents a satisfactory clinical alignment after 10 years from the end of the therapy, the percentage decreases to 10% after 20 years (5). Relapse after orthodontic treatment is defined as an undesired resurgence of a previously adjusted malocclusion, and this has been a topic of ongoing interest throughout most of this century (6, 7). Nowadays, we can relate several causes for relapsing: the skeletal growth (8-11), the neuromuscular forces (12, 13), the inferior incisors inclination variation (14), the variation of the inter canine's inferior width and the third molar eruption (7, 15, 16). In addition, it has been proved that the whole maxillo-facial complex is subject to physiological changes. Development of the arches affects intercanine and intermolar width, dental arch length (17-19) and crowding (20, 21). Several types of permanent or removable systems are used to avoid relapse risk. Depending on the previous malocclusion, they can be positioned in the lower arch, the upper arch, or both (22). Finally, the purpose of this study was to evaluate the stability of edgewise treatments over time through the examination of the changes in both arches over 17 years from the end of the treatment.

## MATERIALS AND METHODS

### *Patient sample*

For this study, 15 subjects treated with edgewise technique between 1985 and 2000 were selected from doctors Calderone's storage in Palermo and Cefalù (PA) in 2017. The inclusion criteria were:

- presence of pretreatment (T1) and posttreatment (2) dental casts in optimal condition;
- possibility for the patient to come for dental impressions;
- arches conditions not affected by trauma or periodontal disease;
- posttreatment retention suspended for 3 years at least.

Of those patients, 12 females and 3 males were treated between 12-35 years old. In addition, 8 cases were treated with extractions and 7 without them. Regarding Angle's classification, 7 presented a bilateral class I, 6 presented a bilateral class II and 2 a bilateral class III. However, the sample is not homogeneous for malocclusion variability due to the complexity of recovering long-time records, the current presence of retention and the unavailability of patients to come for dental impressions after 17 years.

### *Analysis of dental casts.*

Patients came for alginate dental impressions. Casts obtained (T3), along with pretreatment (T1) and posttreatment (T2) casts, were scanned with Sirona inEos X5. For every couple of casts, .stl files were obtained and used for software 3Shape Orthoanalyzer measurement. The focus was on intercanine, interpremolar and intermolar width, dental arch length and crowding. Also, overjet and overbite were calculated from casts in occlusion.

### *Statistical analysis.*

The collected data were submitted to statistical analysis with average values and standard deviation. Fisher's F ANOVA test was used to compare these values for every parameter of the three different time points. The level of statistical significance was predetermined as  $p < 0.05$ . Finally, Bonferroni's post-hoc test was used to verify where were located the significant differences among average group values.

## RESULTS

### *Upper intercanine width*

Fig. 1 shows that the upper intercanine width average values increase along the second measurement and decrease along the third measurement. Blue circles represent average values that must be compared with those displayed on the left. Vertical lines represent the standard deviation. From Bonferroni's test, the ICD average upper at T2 (35.2) is significantly higher ( $p=0,001258$ ) than the ICD upper average at T1 (33.2). Unlike this, there is no significant difference between the ICD upper average at T2 and T3.

### Lower intercanine width

Fig. 2 shows that the average values increase along the second measurement and decrease along the third. The ICD lower average at T2 (27.0) is significantly higher ( $p=0,001914$ ) than the ICD average at T1 (25.2). Otherwise, there is no statistically significant difference between the ICD lower average at T2 and T3, as there is no significant difference between the ICD average at T1 and T3.

### Upper interpremolar width

The IPD average values increase from the T1 time point to T2 and decrease from T2 to T3. However, no significant differences were observed among the three time points ( $p > 0.05$ ).

### Lower interpremolar width

The IPD lower average values increase from T1 time point to T2 and decrease from T2 to T3. No significant differences were observed among the three time points ( $p > 0.05$ ).

### Upper intermolar width

The IMD upper average values increase from T1 to T2 and decrease from T2 to T3. No significant differences were observed among the three time points ( $p > 0.05$ ).

### Lower intermolar width

The IMD lower average values increase from T1 to T2 and decrease from T2 to T3. However, no significant differences were observed among the three time points ( $p > 0.05$ ).

### Dental arch length

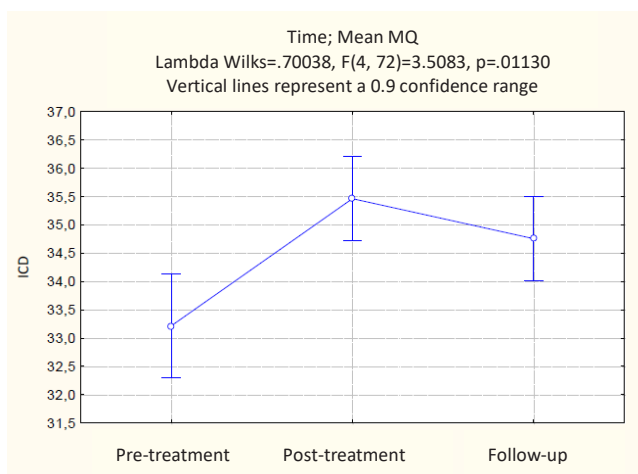
The AL upper average values decrease from T1 to T2 but stay unvaried from T2 to T3; no significant differences were observed among the three time points ( $p > 0.05$ ). The AL lower average values decrease from T1 to T2 but stay unvaried from T2 to T3; however, no significant differences were observed among the three time points ( $p > 0.05$ ).

### Upper crowding

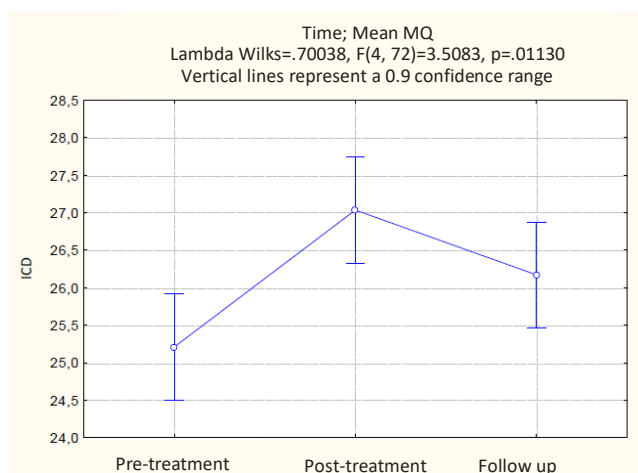
The average values at T2 are significantly higher ( $p=0.009958$ ) than the T1 average. Otherwise, there is no significant difference between T1, T2 and T3 values; likewise, there is no significant difference between the T1 and T3 average values.

### Lower crowding

The average values at T2 are significantly higher than those at T1. However, there is no significant difference between T2 and T3 average values, likewise between T1 and T3 average values. For what concerns *Overjet* and *Overbite* analysis, obtained results are not statistically significant.



**Fig. 1.** Upper intercanine width ICD average values comparison.



**Fig. 2.** Lower intercanine width ICD average values comparison.

## DISCUSSION

Based on the results, intercanine width outcomes are the most significant, with the greater changes observed during the treatment among T1 and T2. These are maintained over time due to the statistical difference between T3 and T1. Lower intercanine width changed mainly during treatment, while changes due to the relapse were not considerable. In the same way, upper and lower crowding average values suggest that the main change was during treatment, without relevant results about relapse. Regarding the other parameters analyzed, the interpremolar and intermolar width results were not statistically significant. Both outcomes showed an increase from T1 to T2 and a slight decrease from T2 to T3. Both upper and lower dental arch length tends to decrease from T1 to T2 but remains stable from T2 to T3. At last, overjet and overbite outcomes contrast with previous studies due to the variety of the sample.

Obtained results are, therefore, comparable to the primary studies carried out by Little at Washington University (6). It is interesting to notice that there are no significant differences for every parameter between the end of the therapy (T2) and the control over time (T3). The analyzed cases present excellent stability over time, proven by the 17 years of follow-up with no retention for at least 3 years. Tweed's edgewise technique can be important in achieving such a treatment goal. The diagnosis is obtained through the characteristic diagnostic triangle, and the therapy is carried out respecting the anterior limit of the dentition and without manipulating the occlusal plane inclination.

Nowadays, the innovation and improvement of the techniques applied have brought the possibility to improve the quality of the treatment and many clinical advantages, such as reduced chair time, less compliance requirement, less discomfort for the patient, and a shortened treatment time.

In order to obtain a satisfactory and stable result, it is mandatory to consider the anterior limit of the dentition, as well as the preservation of the patient's initial dental arch width and the achievement of an occlusion balanced with neuromuscular forces. In addition, it is essential to avoid rapid movements that do not allow the reshaping of periodontal fibres, which generally takes 4-6 months. Therefore, the need for a retention phase is considered primary, especially in parafunctional patients with muscle hypertonia.

## CONCLUSIONS

This study reveals that, in edgewise treatment, the intercanine width outcome is the most significant; the results show considerable changes from the pretreatment to the posttreatment condition without a substantial relapse. These findings highlight the importance of the clinical practice of a correct diagnosis to plan a stable treatment in time. The intercanine width expansion, in most cases, leads to a recovery of the preexisting condition, which is why the clinician shall preserve the initial dimensions. Future research should investigate the range in which it is safe to expand without risking relapse, and guidelines should be drawn to help the clinician in the treatment planning.

## REFERENCES

1. Gomes MN, Dutra H, Morais A, Sgura R, Devito-Moraes AG. In-Office Bleaching During Orthodontic Treatment. *Journal of Esthetic and Restorative Dentistry*. 2016;29(2):83-92. doi:https://doi.org/10.1111/jerd.12276.
2. Guarneri MP, Oliverio T, Silvestre I, Lombardo L, Siciliani G. Open bite treatment using clear aligners. *The Angle Orthodontist*. 2013;83(5):913-919. doi:10.2319/080212-627.1
3. Malik N, Dubey R, Kallury A, Chauksye A, Shrivastav T, Kapse BR. A Review of Orthodontic Archwires. *Journal of Orofacial Research*. 2015;5(1):6-11.
4. Lombardo L, Carlucci A, Palone M, Mollica F, Siciliani G. Stiffness comparison of mushroom and straight SS and TMA lingual archwires. *Progress in Orthodontics*. 2016;17(1). doi:10.1186/s40510-016-0140-2
5. Little RM, Riedel RA, Artun J. An evaluation of changes in mandibular anterior alignment from 10 to 20 years postretention. *American Journal of Orthodontics and Dentofacial Orthopedics*. 1988;93(5):423-428. doi:10.1016/0889-5406(88)90102-3
6. Little RM. Stability and relapse of mandibular anterior alignment: University of Washington Studies. *Seminars in Orthodontics*.

- 1999;5(3):191-204. doi:10.1016/s1073-8746(99)80010-3
7. Vaden JL, Harris EF, Gardner RL. Relapse revisited. *American Journal of Orthodontics and Dentofacial Orthopedics*. 1997;111(5):543-553. doi:10.1016/s0889-5406(97)70291-9
  8. Baydaş B, Erdem A, Yavuz İ, Ceylan İ. 4. Baydaş B, Erdem A, Yavuz İ, Ceylan İ. Heritability of facial proportions and soft-tissue profile characteristics in Turkish Anatolian siblings. *American Journal of Orthodontics and Dentofacial Orthopedics*. 2007;131(4):504-509. doi:https://doi.org/10.1016/j.ajodo.2005.05.055
  9. Carter GA, McNamara JA. Longitudinal dental arch changes in adults. *American Journal of Orthodontics and Dentofacial Orthopedics*. 1998;114(1):88-99. doi:10.1016/s0889-5406(98)70243-4
  10. Sinclair PM, Little RM. Maturation of untreated normal occlusions. *American Journal of Orthodontics*. 1983;83(2):114-123. doi:10.1016/s0002-9416(83)90296-8
  11. Maino G, Turci Y, Arreghini A, Paoletto E, Siciliani G, Lombardo L. Skeletal and dentoalveolar effects of hybrid rapid palatal expansion and facemask treatment in growing skeletal Class III patients. *American Journal of Orthodontics and Dentofacial Orthopedics*. 2018;153(2):262-268. doi:10.1016/j.ajodo.2017.06.022
  12. Reitan K. Tissue Rearrangement During Retention Of Orthodontically Rotated Teeth. *The Angle Orthodontist*. 1959;29(2):105-113.
  13. Anuwongnukroh N, Dechkunakorn S, Kunakornporamut K, Tua-Ngam P. Dental arch changes in postretention in Class II division 1 extraction cases. *International Orthodontics*. 2017;15(2):208-220. doi:10.1016/j.ortho.2017.03.005
  14. Tweed CH. The diagnostic facial triangle in the control of treatment objectives. *American Journal of Orthodontics*. 1969;55(6):651-657. doi:10.1016/0002-9416(69)90041-4
  15. Miclotte A, Grommen B, Cadenas de Llano-Pérula M, Verdonck A, Jacobs R, Willems G. The effect of first and second premolar extractions on third molars: A retrospective longitudinal study. *Journal of Dentistry*. 2017;61:55-66. doi:10.1016/j.jdent.2017.03.007
  16. Vego L. A longitudinal study of mandibular arch perimeter. *Angle Orthodontist*. 1962;32(3):187-192.
  17. Moorrees CF, Chadha JM. Available space to the incisors during dental development: a growth study based on physiologic age. *The Angle Orthodontist*. 1965;35:12-22.
  18. Moorrees CF, Lebrecht L, Kent R. Changes in the natural dentition after second molar emergence (13-18 years). *AJO*, 1980.
  19. Brook A, Jernvall J, Smith R, Hughes T, Townsend G. The dentition: the outcomes of morphogenesis leading to variations of tooth number, size and shape. *Australian Dental Journal*. 2014;59(Suppl 1):131-142. doi:10.1111/adj.12160
  20. Foster TD, Hamilton MC, Lavelle CL. A study of dental arch crowding in four age-groups. *The Dental Practitioner and Dental Record*. 1970;21(1):9-12.
  21. Tibana RHW, Palagi LM, Miguel JAM. Changes in dental arch measurements of young adults with normal occlusion--a longitudinal study. *The Angle Orthodontist*. 2004;74(5):618-623.
  22. Case CS. Principles of retention in orthodontia. *American Journal of Orthodontics and Dentofacial Orthopedics*. 2003;124(4):352-361. doi:10.1016/s0889-5406(03)00541-9





Review

## CORRELATION BETWEEN ORAL SURGERY AND MANDIBULAR FRACTURES IN OSTEOPOROSIS PATIENTS

A. Rosa<sup>1\*</sup>, A. Pujia<sup>2</sup>, S. Casella<sup>3</sup> and C. Arcuri<sup>3</sup>

<sup>1</sup>Materials for Health, Environment and Energy, Department of Chemical Science and Technologies, Dentistry, University of Tor Vergata, Rome, Italy;

<sup>2</sup>Department of Biomedicine and Prevention, University of Rome Tor Vergata, Rome, Italy;

<sup>3</sup>Department of Clinical Sciences and Translational Medicine, University of Rome Tor Vergata, Rome, Italy.

\*Corresponding author

Alessio Rosa

Materials for Health

Environment and Energy

Department of Chemical Science and Technologies

University of Tor Vergata

Via Montpellier 1

00133 Roma

alessio.rosa.21@alumni.uniroma2.eu

### ABSTRACT

The purpose of this study was to investigate how osteoporosis can adversely affect one of the rarest, but now very common, complications of surgery on the posterior jaw: the mandibular fracture. The term “mandibular fracture” refers to a broken jaw (mandible), while fractures of the upper jaw are sometimes called “jaw fractures”, but are usually considered facial fractures (maxillofacial fracture). The fracture usually causes pain and swelling in the affected area, as well as a feeling of misalignment of the teeth. Often, there is a narrowing of the opening of the mouth and a lateral displacement when opening or closing. The authors examined the literature to provide the scientific community with an etiological overview underlying this complication. Our analysis shows that although there are few articles in the indexed literature, this complication is quite common and often linked to the operator’s inexperience, but also to the systemic pathological influence of osteoporosis. For this reason it would seem appropriate to prevent everything by using surgical protocols that reduce jaw fractures by assessing the risk that the disease may involve.

**KEYWORDS:** *third molar, mandibular fracture, oral surgery, impacted tooth, angle mandibular*

Received: 18 February 2023

Accepted: 25 March 2023

Copyright © by BIOLIFE 2023

This publication and/or article is for individual use only and may not be further reproduced without written permission from the copyright holder. Unauthorized reproduction may result in financial and other penalties. **Disclosure: All authors report no conflicts of interest relevant to this article.**

ISSN 2975-1276

## INTRODUCTION

The mandible is the only movable bone in the skull. It is of the dense and hard type and constitutes the lower third of the facial skeleton. Surgical extraction of the lower third molars is one of the most common procedures in oral surgery (1). This surgical procedure may be accompanied by intra- and postoperative complications such as pain, trismus, bleeding, infection, edema, lesions of the inferior alveolar nerve, displacement of teeth into adjacent spaces and mandibular fractures (Fig. 1).

Osteoporosis is a widespread metabolic disease affecting bone, is characterized by bone density collapse along with microarchitectural failure leading to bone fragility and exposure to fracture risk. It affects one in three women and one in five men over the age of 50. The female sex demonstrates declining bone loss as early as menopause, predominantly in trabecular bone, which is then followed by slower loss of trabecular and cortical bone. The mandible has some weak areas less resistant to fractures such as the mandibular angle, the condyle, the mandibular symphysis, the body and the coronoid process. The specific bony anatomy of the gonial angle with its location between the ascending ramus and the mandibular body, as well as its association with the impaction of the lower third molar, makes it one of the most frequent fracture sites (40%). It is the most frequently fractured bone in the maxillofacial skeleton due to its prominence (2, 3). The jaw commonly fractures in the angle, condyle, and chin region (4). The horizontal fracture of the mandible (Fig. 2) is very rare and only a few cases have been reported in the literature (5).

The estimated incidence of mandibular fracture is 11.5 cases per 10,000 individuals (6). The mandibular angle is a frequent fracture site, accounting for 25-33% of all mandibular fractures.

In the literature there are several variables that influence the fracture: for example the anatomical bone component, the masticatory forces, the different dental occlusal loads.

A not very recent but quite simplistic study by Joshi et al. (7) reports that mandibular fractures are more frequent in regions where there is the presence of teeth rather than in edentulous regions of the mandible. Bones often fracture at sites of stress and tensile stress because their resistance to compressive forces is greater. Furthermore, Bodner et al. showed that the isolated mandible is subjected to non-equivalent tensile stress diffusion patterns when perpendicular forces are exerted on it (8).

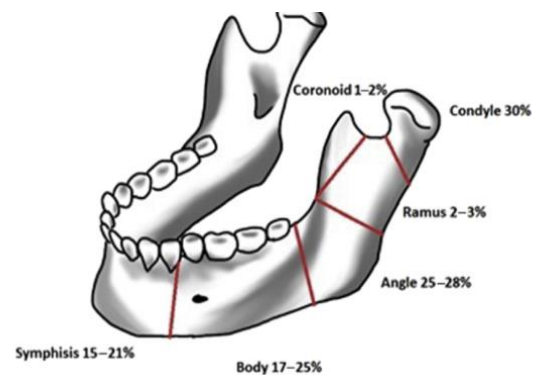
## MATERIALS AND METHODS

This study followed the PRISMA (Preferred Reporting Items for Systematic Reviews and Meta-Analyses) statement (Fig. 1). The main research question was captured in the PICO (Population, Intervention, Comparison, Outcomes) format: "Can a less invasive operation during oral surgery in the jaw reduce the risk of fractures?".

### The signs and symptoms of a mandibular fracture

Trismus
Bleeding from lacerated gingival or mucosal tissue
Ecchymosis/hematoma (at the fracture site or the sublingual space)
Loose, fractured, or displaced teeth
Palpable or visible "step" in the dental arch
Inability to chew or subjective (or obvious) altered bite
Paresthesia of the lip/chin
Lack of motion of the mandibular condyles with palpation through the external auditory canal
<i>From Viozzi CF. Maxillofacial and mandibular fractures in sports. Clin Sports Med 2017;36(2):355-68.</i>

**Fig. 1.** The signs and symptoms of mandibular fracture



**Fig. 2.** Distribution of mandibular fractures (Mooney S, Gulati RD, Yusupov S, Butts SC. Mandibular Condylar Fractures.

*Facial Plast Surg Clin North Am. 2022 Feb;30(1):85-98. doi: 10.1016/j.fsc.2021.08.007. PMID: 34809889.)*



The search strategy involved searching electronic databases: the PubMed (National Library of Medicine), Google Scholar, Scopus, Embase, Medline, and Cochrane Library databases were searched without time or language restriction to find articles describing the basic principles of HRW and its applications in dental practice (Fig. 3).

All studies reviewed were published between January 1, 2000, and April 30, 2023. The search strategy used a combination of different MESH terms and keywords on the six databases: “mandibular surgery”, “mandibular fractures”, “impacted tooth”, “bone fracture”, “mandibular cyst”, “wisdom tooth”, “osteoporosis”, “treatment” and “dysodontiasis”; the additional filter “Language: English” was used. The eligibility criteria for the following review include observational studies on patients after dental and cystic-type oral surgery in the mandible, iatrogenic fractures, traumatic fractures, all LeFort types; reviews; systematic reviews with or without meta-analysis, retrospective studies, RCTs, case reports.

Studies on animal models, 3D models, letters

were excluded. The search strategy identified 345 references published between 2000 and 2022, 143 references were selected for eligibility, and only 14 were included in this review because they met the eligibility criteria.

## RESULT

### *Mandibular fracture and wisdom teeth surgery*

In this review, the risk of mandibular fracture during the surgical procedure of extraction of the included eighth was analyzed, sometimes, although rare, as a postoperative complication. It is strictly necessary to include this complication in the pre-surgical informed consent to be submitted to patients by clearly explaining this eventuality. A study by Libersa et al. showed that the incidence of intraoperative or postoperative mandible fracture was reported to be 0.0049% (9). Osborn et al. unveiled in a major retrospective study the rate of intraoperative mandibular fracture is 1 in 30,583 patients, while the postoperative rate is 1 in 23,714 (10). Kunkel et al. along with his other colleagues showed in a review that mandibular fracture has an incidence of 1 in 29,000 cases (11).

Possible predisposing conditions were traced in this review: certainly advanced age of the patient, the presence of mandibular atrophic conditions, patient-dependent systemic problems such as stages of medium to severe osteoporosis. The mandibular region is also significant in the risk of fracture during extraction of included or semi-erupted eighths. For example, the retromolar region is an area of lower resistance to fracture because it is thin in cross section. In that area, the presence of an included and mesioverted tooth occupies a relatively significant space within the bone. All the more reason if we were faced with an osteoporotic bone with extractive surgical need that would involve removal of the surrounding bone to mobilize it. All this weakens this area mechanically. Studies by Hino et al. (12) retrospectively evaluated the clinical and radiographic data of 12 patients with 13 mandibular fractures after wisdom teeth removal. It was observed that patients older than 30-40 years with tooth roots overlapping the lower alveolar canal or adjacent to the canal had a high risk of mandibular fracture. There were few intraoperative fractures, while slightly more late fractures,

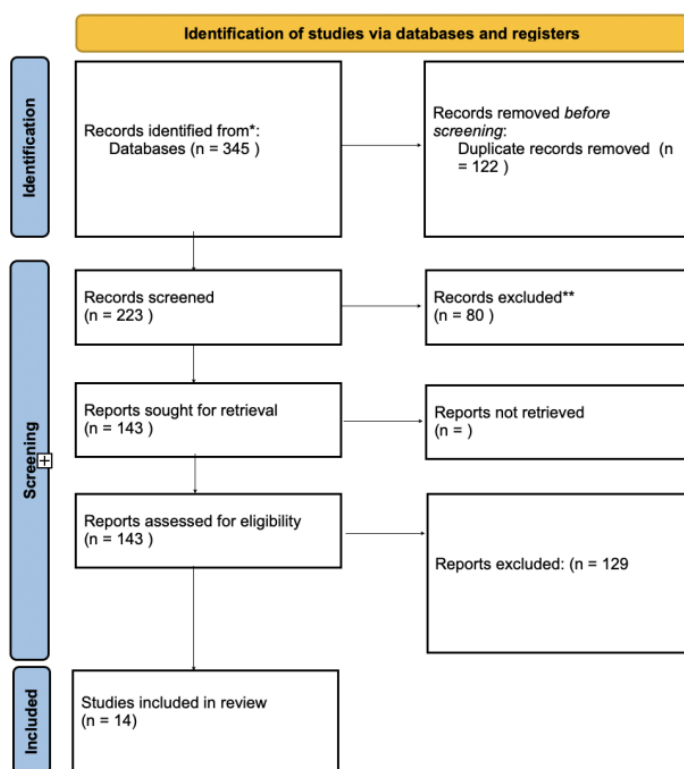


Fig. 3 Search strategy flow chart

which occurred on average 6.6 days after surgery exclusively during chewing. Libersa et al. (9) evaluated 37 fractures in 750,000 extractions in a retrospective study and identified 17 intraoperative fractures and 10 late fractures. Of the 10 late fractures, 8 occurred in men and 6 occurred during mastication. Most of the late fractures occurred between 13 and 21 days after surgery, which could be caused by increased masticatory function and occlusal forces exceeding bone healing.

Differently, Krimmel and Reinert (13) retrospectively analyzed six patients who suffered a mandibular fracture following removal of a third molar. They showed that fractures occurred from 5 to 28 days (with an average of 14 days) after tooth removal. The patients ranged in age from 42 to 50 years and all had complete dentition. The authors of that study concluded that the main risk factor for mandibular fracture appears to have been the patient's advanced age in combination with a full dentition present in the arch.

Regardless of the mechanism, it was found that mandibular fractures occurring during or immediately after extraction of a mandibular third molar are not displaced. They generally radiate from an extraction site toward the weakest point.

In addition, the above review showed that the side of the fracture is less discussed as a risk factor. Wagner et al. (14) noted that fractures on the left side accounted for 70 percent of cases, because right-handed surgeons have a better view of the right surgical field, which results in a less extensive osteotomy. Regarding angulation, the dystangular position is generally considered the most difficult (15). This is probably because mesioangular and vertical angulations are more common in patients generally.

In terms of position of the impacted tooth, they were found to have higher incidences of mandibular fracture than the upper jaw. This is probably related to a higher degree of difficulty in extraction and more extensive bone removal (16). This review found a higher incidence of mandibular fracture for fully impacted teeth (64.8%) than for partially impacted teeth. This is because when the tooth is fully included in the bone you require more osteotomy access and bone removal for extraction. Postoperatively, this results in less cortical bone remaining and thus a more fragile mandibular angle, which can be an important causative factor for late fracture.

Another retrospective study found a relationship between pericoronitis cases on semi-included eighths (68.3%) and the incidence of late mandibular fracture (17). Recurrent infections may contribute to decalcification and thus to an increased likelihood of late fracture. Although the results are confounding enough to make a connection with mandibular fractures, but clearer retrospective data would be needed. This review also observed how mandibular bone quality and density may affect fracture risk.

Pires et al. (18) showed that the period of greatest risk is the second and third postoperative weeks; what happens is that the newly formed granulation tissue in the postextraction socket is replaced by connective tissue and the strength of mandibular bone decreases during this period.

According to Bodner et al. (8) a delay in bone maturation during the regeneration period predisposes to weakening, because two-thirds of the socket is not filled with osteoid material. Thus, causing a decrease in mandibular bone strength.

Osteoporosis in elderly patients may be another highly predisposing reason. A major study (19) showed that elderly patients had thinning of the periodontal ligament and thus dental ankylosis which increases the degree of extraction difficulty. All this leads to a significant need for osteotomies that facilitate the likelihood of a possible fracture.

### *Mandibular fracture and osteoporosis*

Osteoporosis is a widespread metabolic disease affecting bone, is characterized by bone density collapse along with microarchitectural failure leading to bone fragility and exposure to fracture risk (20). It affects one in three women and one in five men over the age of 50. The female sex demonstrates declining bone loss as early as menopause, predominantly in trabecular bone, which is then followed by slower loss of trabecular and cortical bone (21).

Because osteoporotic fractures represent a worldwide health burden, it is important to prevent them. Recently, the literature has focused on the morphology of the inner part of the mandibular cortex below the mental foramen. Since then, and to date, several studies have demonstrated the usefulness of the mandibular cortical index as a predictive indication of osteoporosis (22).

Taguchi et al. suggested that bone findings of mandibular morphology would be useful in screening patients with osteoporosis in postmenopausal women (23). On the other hand, Yamada et al. reported in a study of 1021 Japanese men and women found that the mandibular cortical index was useful in identifying dental patients with osteoporosis, but not those with osteoporotic fractures (20).

According to Perry and Goldberg (24), the risk of mandibular fracture during lower third molar extraction in patients with osteoporosis is due to the creation of a bone area with a weakened structure that makes this type of complication more likely to occur. These changes may cause significant weakening of bone, particularly in the mandibular angle region. Therefore, it can be concluded that there is a relationship between the presence of pathological bone changes and the subsequent occurrence of fractures. Joshi et al. (7) pointed out the possibility that postoperative fractures may be incomplete intraoperative fractures, which may have exceeded stress tolerance limits in the weeks following extraction, as patients felt better and pain symptoms had almost disappeared by the end of the following week.

Recent pilot studies have shown that only alendronate and zoledronate have been shown to be less incident in the risk of jaw fractures (25, 26).

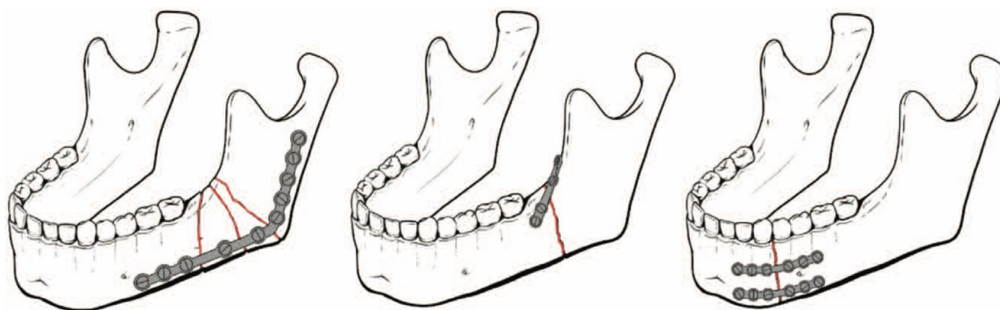
Risedronate has been shown to be more incident in susceptibility to mandibular fractures, McClung et al. shows in a specific study of elderly patients with osteoporosis diagnosed on the basis of bone mineral density rather than risk factors (27).

Some studies indicate that cranio-maxillofacial trauma in elderly women with osteoporosis is associated with falls. A recent systemic analysis showed that the number of maxillofacial fractures sustained in a series of 59 subjects older than 60 years was significantly related to the severity of osteoporosis as determined by a radiographic index of vertebral bone density. This association held for low-energy falls and motor vehicle accidents, observations taken as evidence of maxillofacial bone fragility in osteoporotic subjects (28). An analysis of 355 postmenopausal women showed that osteoporosis per se is associated with cranio-mandibular dysfunction (29). Some information is available on the risks of surgical failure in TMJ patients. A study of outcomes in a series of subjects undergoing arthroplasty or discectomy indicated that osteoporosis was the most significant risk factor for technical failure (30). Although mechanisms were neither indicated nor suggested by this study, it is clear that systemic factors must be considered in surgical planning. Although osteoporosis is a very common condition with a sometimes silent sometimes aggressive course, to date the literature does not present crisp guidelines to be followed to prevent this complication. More studies in this regard would be needed to have more scientific evidence

#### *Treatment of mandibular fractures*

The vast majority of mandibular fractures require surgical stabilization in order to obtain healing and correct occlusion which is lost after the trauma. In cases of a non-displaced fracture without obvious mobility on manual physical examination, a soft diet for 4 to 6 weeks is generally recommended (31). Displaced fractures or fractures that demonstrate mobility on physical examination are different. In this case, in fact, immobilization of the mandible is expected. Although mandibular fractures with good dentition on both sides of the fracture line can in some cases be treated with a period of intermaxillary fixation, most surgeons and patients prefer open reduction and internal fixation, which allows for a much quicker return to full pre-injury function and mobility (32). Patient demographics, comorbidities, dentition, and fracture characterization influence the treating surgeon's choice of fixation. Internal fixation for mandibular fracture can be divided into two categories: weight-bearing fixation and weight-bearing fixation denote a structure capable of withstanding all the load generated by the mandibular function (33). Typically, this requires the application of a large reconstructive plate to the lower margin of the mandible (Fig. 4).

Other studies have demonstrated that load-sharing fixation characterizes a fixation scheme in which the functional



**Fig. 4.** *Differents types of mandibular fixation (Rzewuska A, Kijak E, Halczy Kowalik L. Rehabilitation in the treatment of mandibular condyle fractures. Dent Med Probl. 2021 Jan Mar;58(1):89-96. doi: 10.17219/dmp/128092. PMID: 33847468)*

load is shared between the base of fixation and the long fracture margin (34). Load-sharing fixation can be further divided into rigid and non-rigid (functionally stable) fixation. In the past, surgeons often referred to plates by the size of the outer diameter of the screw used in the plate (e.g., 2.0 mm plate, 2.4 mm plate). Today, new reviews have highlighted the importance of more complex but more predictable plate systems (35, 36).

Ellis et al. in a randomized study demonstrated that the vast majority of unilateral mandibular fractures, with good occlusion, can be treated in a closed manner (35).

Differently, the situation is not so clear for bilateral fractures (37). This review took into consideration the management of atrophic jaw fractures and how the literature expresses itself on the matter. Today the most common form with the best results is the application of plates and lathes, so blocked systems are the first option. In the atrophic mandible, factors are considered that decrease the possibilities of consolidation of the low contact surface, poor vascular port.

## DISCUSSION

The results obtained from this review lead to the rationale that the risk of post-extraction mandibular fracture is mainly linked to excessive osteotomy and/or local alterations. Patients at risk must be carefully informed about the importance of food choices in the post-operative period. Finally, the nonsurgical treatment plan appears to be the most suitable approach to nondisplaced fractures for cooperative patients. Technique comparisons addressed general aspects of surgical procedures for mandibular third molars including: type of raised surgical flap, use of retractors, bone removal techniques, wound irrigation, wound closure, wound drainage, and complete/incomplete tooth removal. All studies analyzed by this review report evidence for each of these comparisons, but due to the limited number of studies and patients and the high risk of bias, the evidence to make changes to surgical practice is therefore limited. However, this review helps describe the state of research evidence to support practice so that surgeons can make an informed choice in adopting new techniques or continuing with established techniques.

Although today the use of the mandibular cortical index appears to be quite predictive to evaluate total bone density in patients with bone demineralization, this study did not find great scientific evidence regarding the correlation between iatrogenic mandibular fractures and systemic bone conditions.

Furthermore, this review makes clear the need to carry out new clinical studies, such as randomized or prospective studies with longitudinal follow-up, since most of the data currently available comes from case series and retrospective studies. However, with the case evaluation of this review, it was possible to clearly identify that there were no late postoperative fractures in patients younger than 20 years. This fact should be shared with third-party payers, who now deny authorization for the removal of asymmetric third molars that will never function. The data from this review also show that the patient at greatest risk for late post-third molar extraction fractures of the mandible is men aged 25 years or older, who have had a preoperative or postoperative infection, or menopausal woman suffering from osteomyelitis or taking some types of bisphosphonates. This group should be identified and educated before the intervention and receive unequivocal postoperative instructions that must be strictly respected to avoid late fractures.

## REFERENCES

1. Pickrell BB, Hollier LH, Jr. Evidence-Based Medicine: Mandible Fractures. *Plast Reconstr Surg.* 2017;140(1):192e-200e. doi:<https://doi.org/10.1097/PRS.0000000000003469>
2. Oji C. Jaw fractures in Enugu, Nigeria, 1985-95. *Br J Oral Maxillofac Surg.* 1999;37(2):106-109. doi:<https://doi.org/10.1054/bjom.1997.0083>
3. Olson RA, Fonseca RJ, Zeitler DL, Osbon DB. Fractures of the mandible: a review of 580 cases. *J Oral Maxillofac Surg.* 1982;40(1):23-28. doi:[https://doi.org/10.1016/s0278-2391\(82\)80011-6](https://doi.org/10.1016/s0278-2391(82)80011-6)
4. Garza JR, Papel ID. *Mandibular fractures : Facial plastic and reconstructive surgery.* New York: Thieme Medical Publishers; 2002.
5. Mitsukawa N, Satoh K, Uemura T, Hosaka Y. An unusual traumatic fracture of the mandibular symphysis resembling horizontal

- osteotomy for genioplasty. *J Craniofac Surg.* 2004;15(2):229-231; discussion 232. doi:<https://doi.org/10.1097/00001665-200403000-00011>
6. Bezerra TP, Studart-Soares EC, Pita-Neto IC, Costa FW, Batista SH. Do third molars weaken the mandibular angle? *Med Oral Patol Oral Cir Bucal.* 2011;16(5):e657-663. doi:<https://doi.org/10.4317/medoral.16970>
  7. Joshi A, Goel M, Thorat A. Identifying the risk factors causing iatrogenic mandibular fractures associated with exodontia: a systemic meta-analysis of 200 cases from 1953 to 2015. *Oral Maxillofac Surg.* 2016;20(4):391-396. doi:<https://doi.org/10.1007/s10006-016-0579-9>
  8. Bodner L, Brennan PA, McLeod NM. Characteristics of iatrogenic mandibular fractures associated with tooth removal: review and analysis of 189 cases. *Br J Oral Maxillofac Surg.* 2011;49(7):567-572. doi:<https://doi.org/10.1016/j.bjoms.2010.09.007>
  9. Libersa P, Roze D, Cachart T, Libersa JC. Immediate and late mandibular fractures after third molar removal. *J Oral Maxillofac Surg.* 2002;60(2):163-165; discussion 165-166. doi:<https://doi.org/10.1053/joms.2002.29811>
  10. Osborn TP, Frederickson G, Jr., Small IA, Torgerson TS. A prospective study of complications related to mandibular third molar surgery. *J Oral Maxillofac Surg.* 1985;43(10):767-769. doi:[https://doi.org/10.1016/0278-2391\(85\)90331-3](https://doi.org/10.1016/0278-2391(85)90331-3)
  11. Kunkel M, Kleis W, Morbach T, Wagner W. Severe third molar complications including death-lessons from 100 cases requiring hospitalization. *J Oral Maxillofac Surg.* 2007;65(9):1700-1706. doi:<https://doi.org/10.1016/j.joms.2007.04.014>
  12. Hino S, Yamada M, Araki R, Kaneko T, Iizuka T, Horie N. What Are Possible Contributors to Associated Dental Injury in Mandibular Fractures? *J Oral Maxillofac Surg.* 2022;80(1):127-136. doi:<https://doi.org/10.1016/j.joms.2021.09.002>
  13. Krimmel M, Reinert S. Mandibular fracture after third molar removal. *J Oral Maxillofac Surg.* 2000;58(10):1110-1112. doi:<https://doi.org/10.1053/joms.2000.9566>
  14. Wagner KW, Otten JE, Schoen R, Schmelzeisen R. Pathological mandibular fractures following third molar removal. *Int J Oral Maxillofac Surg.* 2005;34(7):722-726. doi:<https://doi.org/10.1016/j.ijom.2005.03.003>
  15. Xu JJ, Teng L, Jin XL, Lu JJ, Zhang C. Iatrogenic mandibular fracture associated with third molar removal after mandibular angle osteotomy. *J Craniofac Surg.* 2014;25(3):e263-265. doi:<https://doi.org/10.1097/SCS.0000000000000566>
  16. Steinberg JP, Hirsch EM, Olsson AB, Olsson AB. Functionally stable fixation for an infected mandibular angle fracture associated with third molar extraction during pregnancy. *J Craniofac Surg.* 2013;24(3):1050-1051. doi:<https://doi.org/10.1097/SCS.0b013e318280211d>
  17. Al-Belasy FA, Tozoglu S, Ertas U. Mastication and late mandibular fracture after surgery of impacted third molars associated with no gross pathology. *J Oral Maxillofac Surg.* 2009;67(4):856-861. doi:<https://doi.org/10.1016/j.joms.2008.09.007>
  18. Pires WR, Bonardi JP, Faverani LP, et al. Late mandibular fracture occurring in the postoperative period after third molar removal: systematic review and analysis of 124 cases. *Int J Oral Maxillofac Surg.* 2017;46(1):46-53. doi:<https://doi.org/10.1016/j.ijom.2016.09.003>
  19. Woldenberg Y, Gatot I, Bodner L. Iatrogenic mandibular fracture associated with third molar removal. Can it be prevented? *Med Oral Patol Oral Cir Bucal.* 2007;12(1):E70-72.
  20. Yamada S, Uchida K, Iwamoto Y, et al. Panoramic radiography measurements, osteoporosis diagnoses and fractures in Japanese men and women. *Oral Dis.* 2015;21(3):335-341. doi:<https://doi.org/10.1111/odi.12282>
  21. Cosman F, de Beur SJ, LeBoff MS, et al. Clinician's Guide to Prevention and Treatment of Osteoporosis. *Osteoporos Int.* 2014;25(10):2359-2381. doi:<https://doi.org/10.1007/s00198-014-2794-2>
  22. Taguchi A. Triage screening for osteoporosis in dental clinics using panoramic radiographs. *Oral Dis.* 2010;16(4):316-327. doi:<https://doi.org/10.1111/j.1601-0825.2009.01615.x>
  23. Taguchi A, Tanaka R, Kakimoto N, et al. Clinical guidelines for the application of panoramic radiographs in screening for osteoporosis. *Oral Radiol.* 2021;37(2):189-208. doi:<https://doi.org/10.1007/s11282-021-00518-6>
  24. Perry PA, Goldberg MH. Late mandibular fracture after third molar surgery: a survey of Connecticut oral and maxillofacial surgeons. *J Oral Maxillofac Surg.* 2000;58(8):858-861. doi:<https://doi.org/10.1053/joms.2000.8204>
  25. Black DM, Thompson DE, Bauer DC, et al. Fracture risk reduction with alendronate in women with osteoporosis: the Fracture

- Intervention Trial. FIT Research Group. *J Clin Endocrinol Metab.* 2000;85(11):4118-4124. doi:<https://doi.org/10.1210/jcem.85.11.6953>
26. Black DM, Rosen CJ. Clinical Practice. Postmenopausal Osteoporosis. *N Engl J Med.* 2016;374(3):254-262. doi:<https://doi.org/10.1056/NEJMc1513724>
  27. McClung MR, Geusens P, Miller PD, et al. Effect of risedronate on the risk of hip fracture in elderly women. Hip Intervention Program Study Group. *N Engl J Med.* 2001;344(5):333-340. doi:<https://doi.org/10.1056/NEJM200102013440503>
  28. Bischoff-Ferrari HA, Willett WC, Wong JB, Giovannucci E, Dietrich T, Dawson-Hughes B. Fracture prevention with vitamin D supplementation: a meta-analysis of randomized controlled trials. *JAMA.* 2005;293(18):2257-2264. doi:<https://doi.org/10.1001/jama.293.18.2257>
  29. Klemetti E, Vainio P, Kroger H. Craniomandibular disorders and skeletal mineral status. *Cranio.* 1995;13(2):89-92. doi:<https://doi.org/10.1080/08869634.1995.11678050>
  30. Kirk WS, Jr. Risk factors and initial surgical failures of TMJ arthrotomy and arthroplasty: a four to nine year evaluation of 303 surgical procedures. *Cranio.* 1998;16(3):154-161. doi:<https://doi.org/10.1080/08869634.1998.11746053>
  31. Morrow BT, Samson TD, Schubert W, Mackay DR. Evidence-based medicine: Mandible fractures. *Plast Reconstr Surg.* 2014;134(6):1381-1390. doi:<https://doi.org/10.1097/PRS.0000000000000717>
  32. Ellis E, 3rd, Miles BA. Fractures of the mandible: a technical perspective. *Plast Reconstr Surg.* 2007;120(7 Suppl 2):76S-89S. doi:<https://doi.org/10.1097/01.prs.0000260721.74357.e7>
  33. Agnihotri A, Prabhu S, Thomas S. A comparative analysis of the efficacy of cortical screws as lag screws and miniplates for internal fixation of mandibular symphyseal region fractures: a randomized prospective study. *Int J Oral Maxillofac Surg.* 2014;43(1):22-28. doi:<https://doi.org/10.1016/j.ijom.2013.07.001>
  34. Stacey DH, Doyle JF, Mount DL, Snyder MC, Gutowski KA. Management of mandible fractures. *Plast Reconstr Surg.* 2006;117(3):48e-60e. doi:<https://doi.org/10.1097/01.prs.0000209392.85221.0b>
  35. Ellis E, 3rd, Kellman RM, Vural E. Subcondylar fractures. *Facial Plast Surg Clin North Am.* 2012;20(3):365-382. doi:<https://doi.org/10.1016/j.fsc.2012.05.002>
  36. Kushner GM, Tiwana PS. Fractures of the growing mandible. *Atlas Oral Maxillofac Surg Clin North Am.* 2009;17(1):81-91. doi:<https://doi.org/10.1016/j.cxom.2008.11.001>
  37. Cienfuegos R. Fracture treatment in atrophic mandible. *Cir Cir.* 2023;91(2):240-246. doi:<https://doi.org/10.24875/CIRU.21000281>
  38. Liu FC, Halsey JN, Oleck NC, Lee ES, Granick MS. Facial Fractures as a Result of Falls in the Elderly: Concomitant Injuries and Management Strategies. *Craniomaxillofac Trauma Reconstr.* 2019;12(1):45-53. doi:<https://doi.org/10.1055/s-0038-1642034>



Case Report

## HYALURONIC ACID ENRICHED WITH AMINOACID USED TO FILL BONE DEFECT AFTER CYST NASOPALATINE ENUCLEATION: A CASE REPORT

P. Scarano<sup>1</sup>, S.R. Tari<sup>1</sup>, F. Di Nardo Di Maio<sup>2</sup>, M. Di Carmine<sup>1</sup>, F.S. Al-Hamed<sup>3</sup> and A. Scarano<sup>1,4\*</sup>

<sup>1</sup>Department of Innovative Technologies in Medicine & Dentistry, University of Chieti-Pescara, Italy;

<sup>2</sup>Private practice in Pineto, Italy;

<sup>3</sup>College of Dental Medicine, QU Health, Qatar University, Doha, Qatar;

<sup>4</sup>Department of Oral Implantology, Dental Research Division, College Ingá, UNINGÁ, Cachoeiro de Itapemirim, Espírito Santo, Brazil

\*Correspondence to:

Antonio Scarano, D.D.S., M.D.,

Department of Innovative Technologies in Medicine & Dentistry,

University of Chieti-Pescara,

Via Dei Vestini 31,

66100 Chieti Italy

e-mail. ascarano@unich.it

### ABSTRACT

In this study we aim to evaluate the hyaluronic acid enriched with aminoacid used for fill bone defect after cyst enucleation. A 56-year-old man was referred by the dentist to the Department of Oral Surgery, University of Chieti-Pescara, concerning a nasopalatine duct cyst. Hyaluronic acid was placed for better healing. The flap was sutured with interrupted suturing with 3-0. The cyst material was sent for histopathological examination. Microscopical examination revealed a cystic cavity covered by pseudostratified epithelium. The clinical, radiologic and histopathological aspect were suggestive of infected nasopalatine duct cyst. No adverse reactions were recorded, and the post-operative course was characterized by the absence of pain. Clinical and radiographic controls were performed at 2 and 4 months by digital dental X-ray after cystic enucleation surgery. The X-ray showed increased bone mineralization. Within the limits of the present investigation, this case report mainly summarized the potential mechanism of HA in promoting bone regeneration and the application prospects of hyaluronic acid-based in bone regeneration.

**KEYWORDS:** *hyaluronic acid, cyst, nasopalatine duct, bone healing, bone graft, biomaterials*

Received: 23 February 2023

Accepted: 03 April 2023

Copyright © by BIOLIFE 2023

This publication and/or article is for individual use only and may not be further reproduced without written permission from the copyright holder. Unauthorized reproduction may result in financial and other penalties. **Disclosure: All authors report no conflicts of interest relevant to this article.**

ISSN 2975-1276

## INTRODUCTION

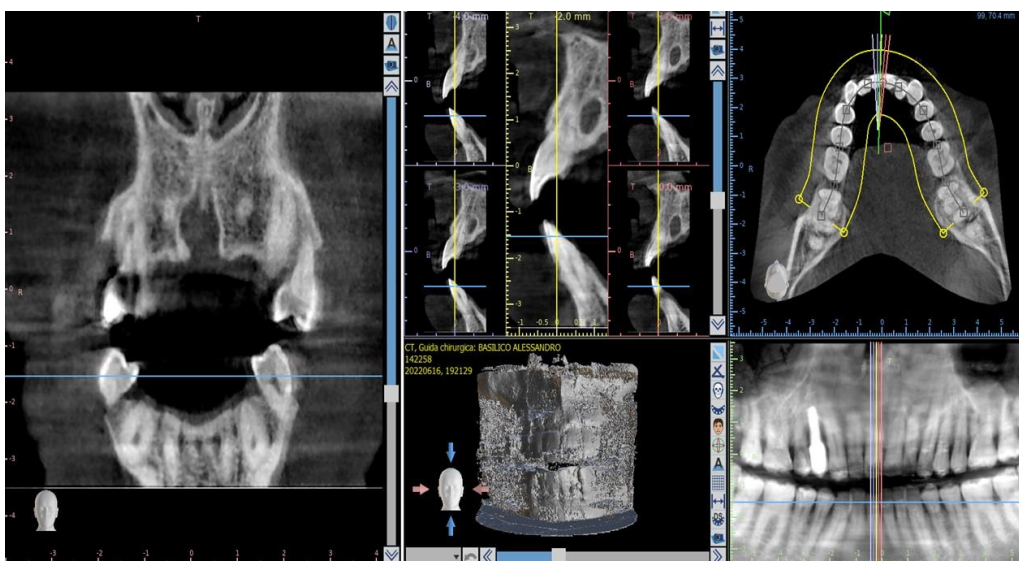
Cystic lesions are very frequent in the oral and maxillo-facial area (1, 2). Nasopalatine duct cyst (NPDC), also known as incisive canal cysts, is the commonest developmental cysts in the jaws (3). The aetiology is not certain probably mechanical trauma or bacterial infection, and it could stimulate proliferation residual epithelial tissue in the nasopalatine duct. Genetic factors sometimes play a role (4). Secondary cysts are formed by mucus secretion from the retained epithelial cells. Males are affected 18–20 times more often than females. NPDC is suggested when the aspirate is clear and straw coloured (3, 4). The differential diagnosis must be made with lateral radicular cyst and cystic ameloblastoma (5). If the nasopalatine duct appears to be greater than 7 mm in dm, the presence of a cyst should be suspected. Cyst enucleation and local curettage is a general treatment for nasopalatine cysts (6).

Usually, the cysts remain asymptomatic and notable common symptom is a recurrent swelling, in the palatal aspect between the central incisors, at times the cyst may extend labiopalatally and fluctuation will be positive (7). The nasopalatine duct cyst is seen as a well-defined cystic outline, between or above the apices of the maxillary first incisor teeth (8). Kay et al. (1972) reported that any radiograph, which showed radiolucency less than 6 mm wide may be considered within normal limits as an incisive canal fossa in the absence of specific symptoms (9). Histopathology are present the epithelium may be stratified squamous at a lower level, more superiorly it may be pseudostratified columnar, cuboidal as well as ciliated (10). Presence of mucous glands, goblet cells and cilia is highly indicative of their origin within the incisive canal as is the presence of nerves and blood vessels in the fibrous capsule (11).

Cystic contents are an important diagnostic aid to rule out a normal incisive canal fossa radiolucency. The viscous fluid content may be mucoid material or even pus if the cyst has been infected (12). Surgical enucleation is the line of treatment of nasopalatine duct cysts, by raising a palatal flap from canine to canine. In the present case report the residual bone defect after cyst enucleation was filled with hyaluronic acid enriched with amino acid (13).

## CASE REPORT

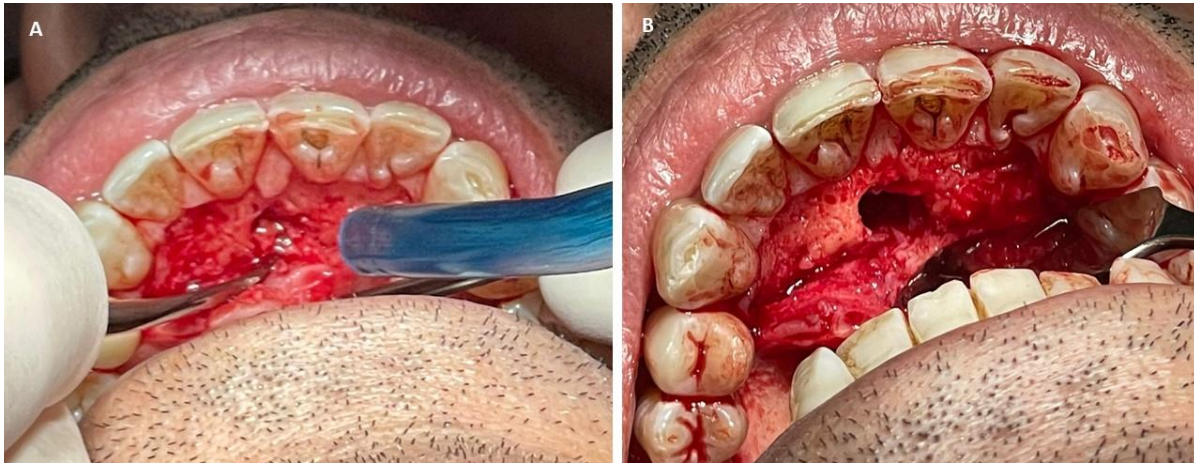A 56-year-old man was referred by the dentist to the Department of Oral Surgery, University of Chieti-Pescara, concerning a nasopalatine duct cyst. The swelling was initially small which gradually increased in size. No history of trauma was reported by patients. Intraoral examination revealed a pink-colored well-defined swelling located between the roots of central incisors. The panoramic radiograph and cone-beam computed tomography (CBCT) showed a well-defined unilocular radiolucent area beyond the nasal floor. The size evaluated by CBCT approximately was 4x3.5cm (Fig.1).



**Fig. 1.** A well-defined, unilocular radiolucent lesion in the maxillary anterior region on the CBCT was detected.

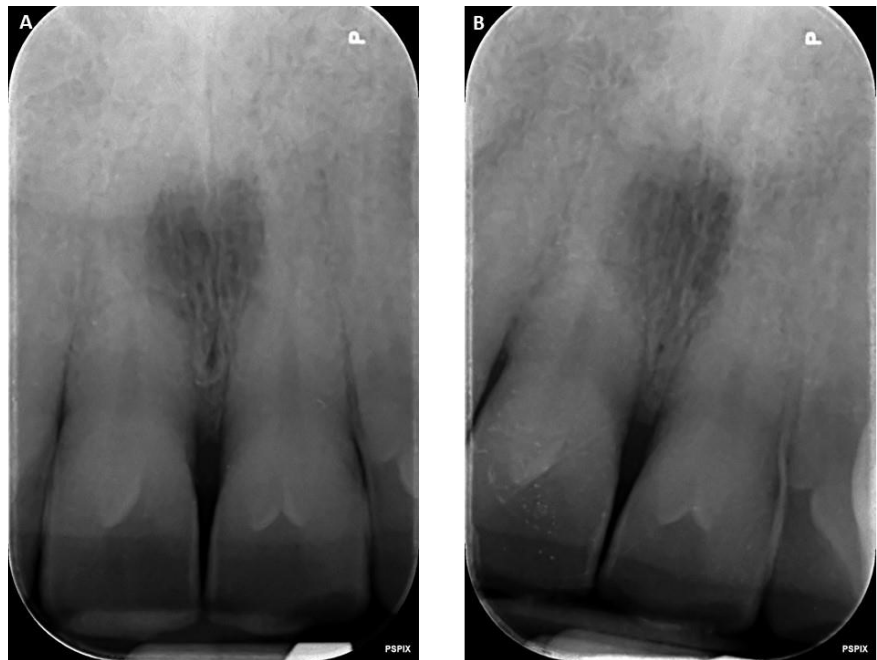


The patient was subjected to antibiotic treatment with Amoxicillin + Clavulanic acid (GlaxoSmithKline, UK) 2 gr/day for six days from the one prior to surgery. Disinfection of the oral cavity was achieved by rinsing with Chloroxidine digluconate at 0.2%. Conscious sedation was achieved by intravenous administration of benzodiazepines. After loco-regional infiltration anesthesia with Articain + Adrenaline 1/100.000 (Septodont, France), and full-thickness of the palatal mucosa is engraved (Fig. 2).



**Fig. 2.** Intraoperative image showing the size of the cyst with. B- Residual bone defect after cyst enucleation.

A palatal mucoperiosteal flap was reflected by a periosteal elevator to expose the cyst. The neurovascular bundle is salvaged and the cyst is carefully dissected free, from its bony bed. The inner lining of the cyst was scraped off and sent for microscopic evaluation. Hyaluronic acid (Italfarmacia, Rome, Italy) was placed to improve the healing response (14). The flap was sutured with interrupted suturing with 3-0 polyamide (Assumid, Assut, Europe, Magliano dei Marsi, AQ Italy). The cyst material was sent for histopathological examination. Microscopical examination revealed a cystic cavity covered by pseudostratified epithelium. There is a fibrous connective tissue wall with inflammatory of lymphocytes and plasma cells. The clinical, radiologic and histopathological aspect were suggestive of infected nasopalatine duct cyst. No adverse reactions were recorded, the post-operative course was characterized by the absence of pain. Clinical and radiographic controls were performed at 2 and 4 months by digital dental X-ray after cystic enucleation surgery. The X-ray showed increased bone mineralization (Fig. 3).



**Fig. 3.** A- Digital x-Ray after 2 months. B- Digital x-ray after 4 months shows a bone defect reduction and an increase of mineralization.

## DISCUSSION

The clinical results of this case report show absence of pain and a good soft tissue healing. Progressive healing has been recorded and minor post-operative symptoms occurred such as swelling, very low pain, absence of sensitive alterations and no haemorrhagic complications.

Bone healing involving a variety of cells, growth factors, cytokines, chemokines, and intracellular and extracellular signaling pathways and have a limited ability to self-heal after injury. When the length of the bone defect exceeds 2 to 2.5 times the diameter of the damaged bone, the self-healing ability of bone tissue alone is not enough (15, 16). For this reason, many biomaterials have been proposed such as, autologous bone, hydroxyapatite, porcine bone, bovine bone etc. In recent years, hyaluronic acid-based hydrogels have received extensive attention in soft tissue augmentation regeneration and in bone regeneration (17). It is generally present in mammalian tissues and plays a critical role in cell differentiation, migration, proliferation, inflammation, angiogenesis, wound healing (18, 19).

In this case report, we described the use of HA to fill the cyst cavity, through clinical evaluation and reported a good healing without clinical signs. Also, the x-ray shows the radiopacity of the bone defect residual after cyst and residual cavity volume reduction was recorded.

The clinical use of biomaterial with or without barrier membranes in bone defects resulting from cystic lesions is not completely clarified (20-25). Cystic cavities have been shown to heal well without the use of biomaterials, which could behave like foreign bodies. In this study, we used cross-linked high molecular weight hyaluronic acid (HA) enriched with amino acid.

The hyaluronic acid has been used in oral surgery for treated with success the periodontal defect (26). In conclusion this case report mainly summarized the potential mechanism of HA in promoting bone regeneration and the application prospects of hyaluronic acid-based in bone regeneration.

## REFERENCES

1. Ettl T, Gosau M, Sader R, Reichert TE. Jaw cysts - filling or no filling after enucleation? A review. *J Craniomaxillofac Surg*. 2012;40(6):485-493. doi:<https://doi.org/10.1016/j.jcms.2011.07.023>
2. Robertson H, Palacios E. Nasopalatine duct cyst. *Ear Nose Throat J*. 2004;83(5):313.
3. Escoda Francoli J, Almendros Marques N, Berini Aytés L, Gay Escoda C. Nasopalatine duct cyst: report of 22 cases and review of the literature. *Med Oral Patol Cir Bucal*. 2008;13(7):E438-443.
4. Shear M, Speight P. *Cysts of the Oral and Maxillofacial Regions*: Wiley; 2007.
5. Gnanasekhar JD, Walvekar SV, al-Kandari AM, al-Duwairi Y. Misdiagnosis and mismanagement of a nasopalatine duct cyst and its corrective therapy. A case report. *Oral Surg Oral Med Oral Pathol Oral Radiol Endod*. 1995;80(4):465-470. doi:[https://doi.org/10.1016/s1079-2104\(05\)80372-5](https://doi.org/10.1016/s1079-2104(05)80372-5)
6. Nortjé CJ, Farman AG. Nasopalatine duct cyst. *International Journal of Oral Surgery*. 1978;7(2):65-72.
7. Swanson KS, Kaugars GE, Gunsolley JC. Nasopalatine duct cyst: an analysis of 334 cases. *J Oral Maxillofac Surg*. 1991;49(3):268-271. doi:[https://doi.org/10.1016/0278-2391\(91\)90217-a](https://doi.org/10.1016/0278-2391(91)90217-a)
8. Allard RH, van der Kwast WA, van der Waal I. Mucosal antral cysts. Review of the literature and report of a radiographic survey. *Oral Surg Oral Med Oral Pathol*. 1981;51(1):2-9. doi:[https://doi.org/10.1016/0030-4220\(81\)90118-3](https://doi.org/10.1016/0030-4220(81)90118-3)
9. Killey HC, Kay LW. *Benign Cystic Lesion of the Jaws, their Diagnosis and Treatment*. Livingstone, Ltd, Edinburgh & London.: E & S.
10. Killey HC, Kay LW. Observations based on the surgical closure of 362 oro-antral fistulas. *Int Surg*. 1972;57(7):545-549.
11. De Cuyper K, Vanhoenacker FM, Hintjens J, Verstraete KL, Parizel PM. Nasopalatine duct cyst. *JBR-BTR*. 2008;91(4):179.
12. Vasconcelos R, de Aguiar MF, Castro W, de Araujo VC, Mesquita R. Retrospective analysis of 31 cases of nasopalatine duct cyst. *Oral Dis*. 1999;5(4):325-328. doi:<https://doi.org/10.1111/j.1601-0825.1999.tb00098.x>
13. Moss HD, Hellstein JW, Johnson JD. Endodontic considerations of the nasopalatine duct region. *J Endod*. 2000;26(2):107-110. doi:<https://doi.org/10.1097/00004770-200002000-00012>

14. Scarano A, Rapone B, Amuso D, Inchingolo F, Lorusso F. Hyaluronic Acid Fillers Enriched with Glycine and Proline in Eyebrow Augmentation Procedure. *Aesthetic Plast Surg*. 2022;46(1):419-428.
15. Wiese A, Pape HC. Bone defects caused by high-energy injuries, bone loss, infected nonunions, and nonunions. *Orthop Clin North Am*. 2010;41(1):1-4, table of contents. doi:<https://doi.org/10.1016/j.ocl.2009.07.003>
16. Scarano A, Degidi M, Perrotti V, Degidi D, Piattelli A, Iezzi G. Experimental evaluation in rabbits of the effects of thread concavities in bone formation with different titanium implant surfaces. *Clin Implant Dent Relat Res*. 2014;16(4):572-581. doi:<https://doi.org/10.1111/cid.12033>
17. Xin L, Wei C, Tong X, et al. In situ delivery of apoptotic bodies derived from mesenchymal stem cells via a hyaluronic acid hydrogel: A therapy for intrauterine adhesions. *Bioact Mater*. 2022;12(107-119). doi:<https://doi.org/10.1016/j.bioactmat.2021.10.025>
18. Passi A, Vigetti D. Hyaluronan as tunable drug delivery system. *Adv Drug Deliv Rev*. 2019;146(83-96). doi:<https://doi.org/10.1016/j.addr.2019.08.006>
19. Scarano A, Bugea C, Leo L, Santos de Oliveira P, Lorusso F. Autologous Platelet Gel (APG): A Preliminary Evaluation of the Mechanical Properties after Activation with Autologous Thrombin and Calcium Chloride. *Materials (Basel)*. 2021;14(14):doi:<https://doi.org/10.3390/ma14143941>
20. Di Dio M, Scarapecchia D, Porcelli D, Arcuri C. Spontaneous bone regeneration after removal of cysts: one-year follow-up of 336 consecutive cases. *JOURNAL OF ORAL SCIENCE & REHABILITATION*. 2016;2(2):50-56.
21. Wachtel H, Fickl S, Hinze M, Bolz W, Thalmair T. The bone lamina technique: a novel approach for lateral ridge augmentation--a case series. *Int J Periodontics Restorative Dent*. 2013;33(4):491-497. doi:<https://doi.org/10.11607/prd.1248>
22. Chiapasco M, Rossi A, Motta JJ, Crescentini M. Spontaneous bone regeneration after enucleation of large mandibular cysts: a radiographic computed analysis of 27 consecutive cases. *J Oral Maxillofac Surg*. 2000;58(9):942-948; discussion 949. doi:<https://doi.org/10.1053/joms.2000.8732>
23. Santamaria J, Garcia AM, de Vicente JC, Landa S, Lopez-Arranz JS. Bone regeneration after radicular cyst removal with and without guided bone regeneration. *Int J Oral Maxillofac Surg*. 1998;27(2):118-120. doi:[https://doi.org/10.1016/s0901-5027\(98\)80308-1](https://doi.org/10.1016/s0901-5027(98)80308-1)
24. Chacko R, Kumar S, Paul A, Arvind. Spontaneous Bone Regeneration After Enucleation of Large Jaw Cysts: A Digital Radiographic Analysis of 44 Consecutive Cases. *J Clin Diagn Res*. 2015;9(9):ZC84-89. doi:<https://doi.org/10.7860/JCDR/2015/13394.6524>
25. Scarano A, Ciccicarese S, Amuso D, Mortellaro C, Lorusso F. Cortical bone lamina approach for mandibular large cystic defect: a case report. *J Biol Regul Homeost Agents*. 2019;33(6 Suppl. 2):85-91 DENTAL SUPPLEMENT.
26. Pilloni A, Marini L, Gagliano N, et al. Clinical, histological, immunohistochemical, and biomolecular analysis of hyaluronic acid in early wound healing of human gingival tissues: A randomized, split-mouth trial. *J Periodontol*. 2023;94(7):868-881. doi:<https://doi.org/10.1002/JPER.22-0338>





Comparative Study

## PAIN-REDUCING EFFICACY OF ANESTHETIC SPRAY VERSUS COMPRESSION TO REDUCE THE PAIN DURING TOPICAL INJECTION IN PALATAL ZONE

S.R. Tari<sup>1</sup>, R. Scarano<sup>1</sup>, F.S. Al-Hamed<sup>2</sup>, F. Lorusso<sup>1</sup> and P. Scarano<sup>1\*</sup>

<sup>1</sup>Department of Innovative Technologies in Medicine & Dentistry, University of Chieti-Pescara, Italy

<sup>2</sup>College of Dental Medicine, QU Health, Qatar University, Doha, Qatar

\*Correspondence to:

Paolo Scarano, DDS

Department of Innovative Technologies in Medicine & Dentistry,

University of Chieti-Pescara,

Via Dei Vestini 31,

66100 Chieti Italy

e-mail: pscarano849@gmail.com

### ABSTRACT

In this study we aim to evaluate the pain-reducing efficacy of xylocaine spray versus compression to reduce the pain during topical anesthetic in palatal zone. Thirty healthy individuals needing local anaesthesia in the palatal area, participated in this comparative study. Male and female patients who consented for treatment between the age groups of 24–65 years with at least one posterior maxillary tooth extraction have been included in this study. All subject provided signed informed consent. Exclusion criteria were as follows: smoking and malignant tumours. The subjects were randomly divided into two groups: Group A: 15 patients treated with Xylocaine spray; Group B: 15 patients treated with local compression. Pain during injection and procedure satisfaction grade were recorded with visual analog scale (VAS). The patient's perceptions were scored through the SEM score. No significant differences in patient's perceptions and clinical pain were associated to the pre-anesthesia techniques ( $p>0.05$ ). No differences regarding the procedure satisfaction were detected between the xylocaine spray vs. pressure groups ( $p>0.05$ ). Within the limits of the present investigation, the xylocaine spray and pressure procedure were effective for the pain distress control during palatine local anesthesia.

**KEYWORDS:** *anesthetic spray, xylocaine, pain, palate, compression, tooth extraction*

### INTRODUCTION

Local anesthesia refers to the loss of sensation caused by a reversible blockade of nerve conduction around the site of application. In dentistry, local anesthetics are administered via a variety of anesthetic techniques that are classified according to specific effects as (1) conduction anesthesia, (2) infiltration anesthesia, (3) topical anesthesia or surface

Received: 29 January 2023

Accepted: 06 March 2023

Copyright © by BIOLIFE 2023

This publication and/or article is for individual use only and may not be further reproduced without written permission from the copyright holder. Unauthorized reproduction may result in financial and other penalties. **Disclosure: All authors report no conflicts of interest relevant to this article.**

ISSN 2975-1276

anesthesia (1). Although conduction anesthesia and infiltration anesthesia produce a deep anesthesia, the use of needles may arouse fear and pain in patients.

The thought and performance of local anaesthetic injection often provoke feelings of discomfort in the patient and have been described as one of the most anxiety-provoking procedures in dentistry (2). Acute pain depends on psychological factors, such as anxiety, fear, trust, and level of perception of stimulus, which has put forward the use of dental topical anesthesia efficacy.

On the other hand, although the intensity of the anesthesia is weak, topical anesthetics have little side effects with easy administration and reduces pain caused by needle injections and can thus generate positive responses towards dental treatment in patients (3).

Topical anaesthetic gels are frequently used in dentistry to reduce or eliminate pain during the injection procedure(2). Topical anesthetics alter pain thresholds by controlling pain sensations through a blockade of signals that are transmitted from the peripheral sensory nerve fibers. However, they are only effective in blocking the pain stimuli in the superficial layer of the mucosa. Local anesthetics that are used for topical anesthesia must have superior mucosal permeability in order to easily reach free nerve terminals (4).

Vasoconstrictors are not added to topical local anesthetics because they undermine mucosal permeability. Furthermore, topical local anesthetics are typically more concentrated than injectable anesthetics in order to promote diffusion after passing through the mucosa (5).

In addition to topical anesthesia, there are some other simple methods to diminish pain during injection, for example, local pressure on the area before injection. According to the theory of gate control, which was first presented by Melzack and Wall, local pressure could reduce pain during injection. Stimulation of A beta fibers through pressure and vibration could regulate the medullary dorsal horn, resulting in a decrease in painful nerve inputs from peripheral tissues (6, 7).

The aim of this was to compare the effect of local pressure and topical anesthesia with Xylocaine gel on pain during infiltration injection for topical anesthetic in dental nerve blocks.

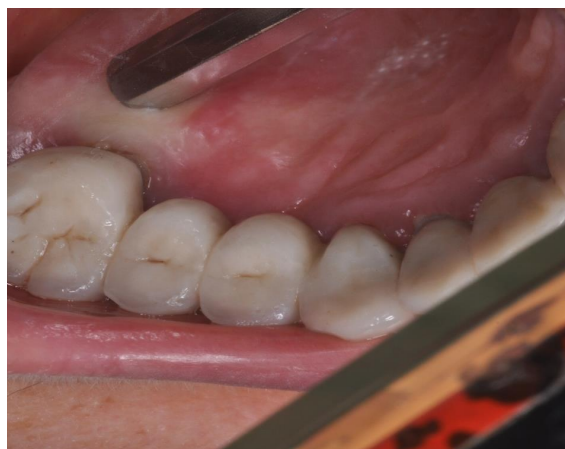## MATERIALS AND METHODS

In this clinical randomized study, thirty patients were evaluated. Patients who agreed to participated in this study were randomly assigned to the study groups without considering their gender. A total of thirty healthy subjects needing local anesthesia in the posterior palatal area, participated in this comparative study. Male and female patients who consented for treatment between the age groups of 24–65 years with at least one posterior maxillary tooth extraction. All subjects provided signed the signed informed consent. The subjects were randomly divided into two groups: Group A: 15 patients treated with Xylocaine spray; Group B: 15 patients treated with local compression. Pain during injection was recorded with visual analog scale (VAS)(8, 9). Randomization was performed using the computer generated random equal numbers of blinded packages containing either of the group code. Blinded packages were prepared by the nonclinical staff according to the generated random chart and were available to the investigator only after the subject was recruited for the study.

Before administration of anesthesia in each group, one side was randomly selected as experimental and the opposite side as control. In group B, pressure was applied with the handle of the mirror until the area was ischemic on the alveolar mucosa at injection site (Fig. 1).

In group A the site was treated with xylocaine spray applied with xylocaine-soaked cotton for 5 minutes (Fig. 2).

We followed the same protocol of asking patients to keep the mouth open, and using suction apparatus to clear the pooling saliva, to maintain the adhesiveness of cotton on the mucosa. In all groups, palatal infiltration of 2% articaine with 1:200.000



**Fig. 1.** Ischemic area produced on the alveolar mucosa by the pressure.

adrenaline was carried out. All the injections were performed by a 25 mm and 27gauge needle was done. During the insertion of needle and anaesthetic infiltration, the patient’s behaviour was evaluated for pain perception using sound, eye, motor (SEM) scale and visual analog scale (VAS) by the operator (Fig. 3).

Immediately after the injection, the volunteers were asked to rate their pain during needle penetration and injection on the 10 mm VAS forms. In this scale, 0 was considered as no pain, 1 to 3 as mild pain, 4 to 6 as moderate pain, and 7 to 9 as severe pain. Patient Satisfaction was validated using VAS satisfaction score which had two descriptors representing the rates of satisfaction, the patients rated his satisfaction by making vertical mark on the scale of 0 to 10, where 0 stands for not satisfy all and 10 score for completely satisfied (Fig. 4).

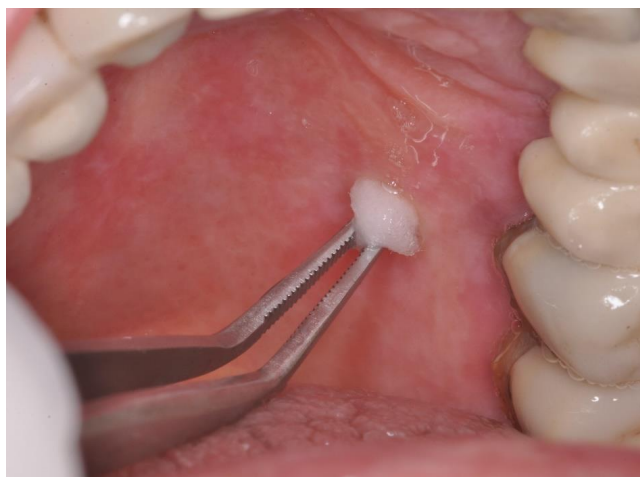
The VAS was chosen due to of its simplicity and as it is accepted as a standard scale for pain score. In the study, the patient’s behavior was evaluated for pain perception using SEM (Sound, eye, motor) scale by the operator (Table I).

*Statistical analysis*


The assessment has been conducted by the statistical package GraphPad 8.0 (Prism, San Diego CA USA). The descriptive statistics has been conducted calculating the means, standard deviation and 95% Confidence Intervals of the means. The Mann Whitney test has been applied to compare the study variables means. The level of significance was considered for  $p < 0.05$ .

**RESULTS**


Pain score by VAS is a numerical rating scale where 0 stands for no pain and 10 represents the possible worst pain. Patient satisfaction score was also assessed by VAS. At the beginning and at the end of the scale, are two descriptors representing extremes of satisfaction where 0 stands for not satisfied at all and 10 stands for completely satisfied. The exact question which has been asked for Pain VAS and Satisfaction VAS has been mentioned.



**Fig. 2.** During the application of xylocaine-soaked cotton.



**Fig. 3.** Pain VAS: Are you having during palatine injection?



**Fig. 4.** Satisfaction VAS: Are you satisfied with palatine block given during treatment?

**Table I.** SEM scoring (sound, eye motor) during palatine injection

Parameter	Comfort (1)	Mild discomfort (2)	Moderate discomfort (3)	Severe discomfort (4)
Sound	No sound	Non-specific sound	Verbal complaint, louder sound	Verbal complaint, shouting, crying
Eye	No sign	Dilated eyes without tears (anxiety sign)	Tears, sudden eye movements	Crying, tears covering the face
Motor	Relaxed body and hand status	Muscular contraction, hands contraction	Sudden body and hand movements	Hand movement for defence turning the head to opposite side

Out of 30 patients included in the study, 14 were male and 16 were female in the age group of 24–65 years with a mean age of 6.27 years. Tables II and III show a comparison between both the test groups under VAS and SEM scales. The mean scores obtained for the group B were lower than the group A under both pain scales. However, the mean scores under both the pain scales were statistically not significant ( $p > 0.05$ ).

**Table II.** Comparison of pain determined by the anaesthesia procedures by VAS

Group	N of patients	Mean $\pm$ SD	95% CI	P Value
A – Xylocaine spray	15	1 $\pm$ 0.4	(0.79-1.2)	p=0.827
B – Pressure	15	0.9 $\pm$ 0.5	(0.68-1.2)	

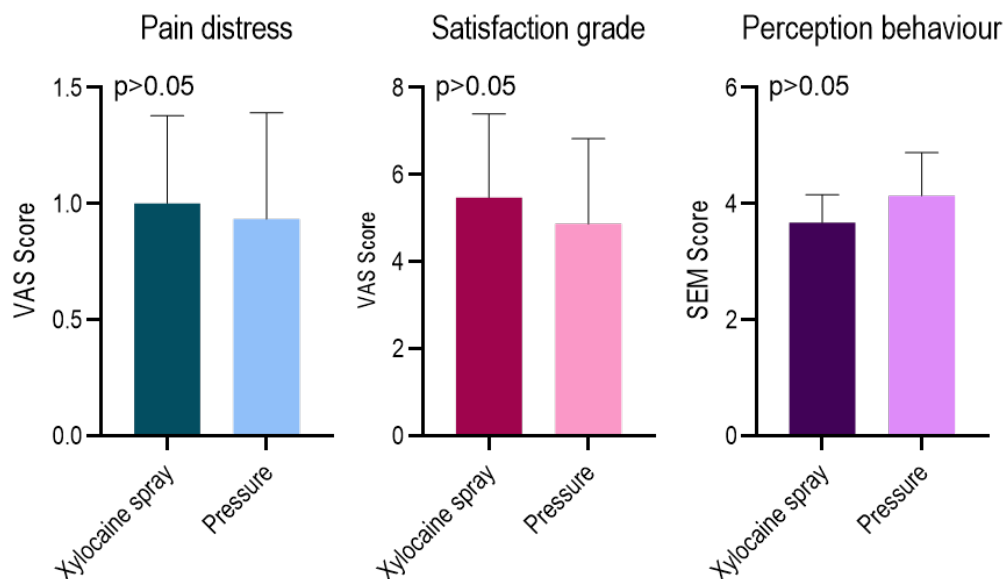
**Table III.** Comparison between both test groups using SEM

Group	N of patients	Mean $\pm$ SD	95% CI	P Value
A – Xylocaine spray	15	3.7 $\pm$ 0.13	(3.4-3.9)	p=0.105
B – Pressure	15	4.1 $\pm$ 0.19	(3.7-4.5)	

The pain distress associated to xylocaine spray vs. pressure group were respectively 1 $\pm$  0.4 (95% CI: 0.79-1.2) and 0.9 $\pm$ 0.5 (95% CI: 0.68-1.2) ( $p=0.827$ ). The SEM scale for xylocaine spray vs. pressure group were respectively 3.7 $\pm$  0.13 (95% CI: 3.4-3.9) and 4.1 $\pm$ 0.19 (95% CI: 3.8-6.0) ( $p=0.105$ ). The procedure satisfaction associated with xylocaine spray vs pressure were 5.5 $\pm$  1.9 and 4.9 $\pm$ 2.0 ( $p=0.447$ ) (Table IV) (Fig. 5).

**Table IV.** Comparison of satisfaction determined by the anaesthesia procedures by VAS

Group	N of patients	Mean $\pm$ SD	95% CI	P Value
A – Xylocaine spray	15	5.5 $\pm$ 1.9	(4.4-6.5)	p=0.447
B – Pressure	15	4.9 $\pm$ 2.0	(3.8-6.0)	



**Fig. 5.** Chart summary of the VAS and SEM scoring of the xilocain spary vs pressure group ( $p > 0$ )



## DISCUSSION

Topical anesthetics are highly useful for reducing discomfort, pain, and anxiety during dental procedures. Traditional topical anesthetic agents with benzocaine and lidocaine as active ingredients are available in various forms and products and they should be selected based on the intended use (10). In this randomized clinical trial, we compared the effect of local pressure and Xylocaine Gel as a topical anesthetic agent on pain during infiltration injection for maxillary canine teeth. Topical anesthetics typically act for 10–15 min (11). When topical anesthetics are applied on the dried mucous membrane, they reversibly inhibit peripheral sensory nerve fibers, altering pain thresholds. Thus, the surface anesthetic action largely depends on the drug permeability (1). One method to improve the surface permeability is to alter the mode of drug delivery (12). In addition, dental anxiety and fear of needle is one of the most common problem encountered during dental extraction. Needle phobia is treated as one of the medical condition, affecting 10% populations, which can result in physiological changes like blood pressure, heart rate, ECG and stress hormones variations in the body (13).

The rationale behind investigating the effect of local pressure on pain during infiltration injection in this study was that it could be effective in reducing pain during injection, according to the gate control theory (14). One of the most primitively used technique gaining popularity is acupressure, which involves application of pressure at certain key points that stimulates the nervous system to initiate natural healing (15). It is a procedure which either involves application of pressure directly by finger in circular motion or application of consistent and constant pressure through bead/pellet at the stipulated points. The myelinated nerve fibers in muscles are stimulated with the application of pressure at acupoints which in turn will activate the midbrain and pituitary-hypothalamus via the spinal cord. Various neurotransmitters like Enkephalin, b-endorphin, Dynorphin, Serotonin, and Noradrenalin, play an important role by stimulating A $\delta$  fibers situated in the skin and muscles. The A $\delta$  fibers which terminate in the second layer of the black horn release the enkephalins which inhibit the incoming painful sensations (16). In conclusion the xylocaine spray and pressure are equally effective in controlling pain during the administration of local anesthesia.

## REFERENCES

1. Boyce RA, Kirpalani T, Mohan N. Updates of Topical and Local Anesthesia Agents. *Dent Clin North Am.* 2016;60(2):445-471. doi:https://doi.org/10.1016/j.cden.2015.12.001
2. Bagesund M, Tabrizi P. Lidocaine 20% patch vs lidocaine 5% gel for topical anaesthesia of oral mucosa. *Int J Paediatr Dent.* 2008;18(6):452-460. doi:https://doi.org/10.1111/j.1365-263X.2007.00910.x
3. Covino BG. Pharmacology of local anaesthetic agents. *Br J Anaesth.* 1986;58(7):701-716. doi:https://doi.org/10.1093/bja/58.7.701
4. Meechan JG. Intraoral topical anesthesia. *Periodontol 2000.* 2008;46(56-79). doi:https://doi.org/10.1111/j.1600-0757.2008.00231.x
5. de Freiras GC, Pozzobon RT, Blaya DS, Moreira CH. Efficacy of Benzocaine 20% Topical Anesthetic Compared to Placebo Prior to Administration of Local Anesthesia in the Oral Cavity: A Randomized Controlled Trial. *Anesth Prog.* 2015;62(2):46-50. doi:https://doi.org/10.2344/0003-3006-62.2.46
6. Eidelman A, Weiss JM, Lau J, Carr DB. Topical anesthetics for dermal instrumentation: a systematic review of randomized, controlled trials. *Ann Emerg Med.* 2005;46(4):343-351. doi:https://doi.org/10.1016/j.annemergmed.2005.01.028
7. Juhlin L, Evers H, Broberg F. A lidocaine-prilocaine cream for superficial skin surgery and painful lesions. *Acta Derm Venereol.* 1980;60(6):544-546. doi:https://doi.org/10.2340/0001555560544546
8. Scarano A, Carinci F, Lorusso F, et al. Ultrasonic vs Drill Implant Site Preparation: Post-Operative Pain Measurement Through VAS, Swelling and Crestal Bone Remodeling: A Randomized Clinical Study. *Materials (Basel).* 2018;11(12):doi:https://doi.org/10.3390/ma11122516
9. Scarano A, Lorusso F, Arcangelo M, D'Arcangelo C, Celletti R, de Oliveira PS. Lateral Sinus Floor Elevation Performed with Trapezoidal and Modified Triangular Flap Designs: A Randomized Pilot Study of Post-Operative Pain Using Thermal Infrared Imaging. *Int J Environ Res Public Health.* 2018;15(6):doi:https://doi.org/10.3390/ijerph15061277
10. Ramacciato JG, Meechan JG. Recent advances in local anaesthesia. *Dent Update.* 2005;32(1):8-10, 12-14. doi:https://doi.org/10.12968/denu.2005.32.1.8

11. Lee HS. Recent advances in topical anesthesia. *J Dent Anesth Pain Med.* 2016;16(4):237-244. doi:<https://doi.org/10.17245/jdapm.2016.16.4.237>
12. Franz-Montan M, Ribeiro LNM, Volpato MC, et al. Recent advances and perspectives in topical oral anesthesia. *Expert Opin Drug Deliv.* 2017;14(5):673-684. doi:<https://doi.org/10.1080/17425247.2016.1227784>
13. Alla I, Lorusso F, Gehrke SA, Inchingolo F, Di Carmine M, Scarano A. Implant Survival in Patients with Chronic Kidney Disease: A Case Report and Systematic Review of the Literature. *Int J Environ Res Public Health.* 2023;20(3):doi:<https://doi.org/10.3390/ijerph20032401>
14. Hutchins HS, Jr., Young FA, Lackland DT, Fishburne CP. The effectiveness of topical anesthesia and vibration in alleviating the pain of oral injections. *Anesth Prog.* 1997;44(3):87-89.
15. Wang SM, Gaal D, Maranets I, Caldwell-Andrews A, Kain ZN. Acupressure and preoperative parental anxiety: a pilot study. *Anesth Analg.* 2005;101(3):666-669. doi:<https://doi.org/10.1213/01.ANE.0000175212.17642.45>
16. Gupta D, Dalai DR, Swapnadeep, et al. Acupuncture ( zhen jiu ) - an emerging adjunct in routine oral care. *J Tradit Complement Med.* 2014;4(4):218-223. doi:<https://doi.org/10.4103/2225-4110.139113>



Case report

## GRAFT OF THE ILIAC CREST AND TOTAL IMPLANT FULL ARCH REHABILITATION: A MULTICASE REPORT

A.M. Pujia<sup>1</sup>, A. Rosa<sup>2\*</sup>, V. Tognoni<sup>3</sup>, S. Casella<sup>4</sup> and C. Arcuri<sup>4</sup>

<sup>1</sup>Department of Biomedicine and Prevention, University of Rome Tor Vergata, Rome, Italy

<sup>2</sup>Department of Chemical Science and Technologies, Dentistry, University of Tor Vergata, Rome, Italy

<sup>3</sup>Department of Emergency Surgery, Policlinico Tor Vergata, University of Rome Tor Vergata, Rome, Italy

<sup>4</sup>Department of Clinical Sciences and Translational Medicine, University of Rome Tor Vergata, Rome, Italy

\*Corresponding author:

Alessio Rosa

Department of Chemical Science and Technologies,

University of Tor Vergata,

Via Montpellier 1,

00133 Roma, Italy

e-mail: dott.alessiorosa@gmail.com

### ABSTRACT

The purpose of this study was to assess changes in bone volume after the block bone increase and placement of dental implants and further assess the aesthetic outcome. This case highlights the success of implant osseointegration and aesthetic oral rehabilitation 5 months after the maxillary graft with a corticocancellous block obtained from the iliac crest. This article was conducted through a literature review based on international epidemiological data. This study presents the case of two patients who benefit from this method of treatment that leads to jaw reconstruction and dental implant placement. The postoperative evolution of the patients was favourable, with the integration of the grafts of the iliac ridge and the dental implants. After the prosthetic loading, the masticatory and aesthetic function of the patients were restored. This jaw reconstruction method has proven effective, with a high degree of reliability and a significant improvement in patients' quality of life.

**KEYWORDS:** *bone regeneration, iliac crest graft, dental implants, maxillary reconstruction, full arch*

### INTRODUCTION

Bone grafts are indicated in several cases: congenital and/or acquired defects, lack of teeth, post-traumatic resorption or loss of teeth, infections, infections and cancer. Due to inherent genetic, inductive and conductive qualities, self-transplants

Received: 16 February 2023

Accepted: 25 April 2023

Copyright © by BIOLIFE 2023

This publication and/or article is for individual use only and may not be further reproduced without written permission from the copyright holder. Unauthorized reproduction may result in financial and other penalties. **Disclosure: All authors report no conflicts of interest relevant to this article.**

ISSN 2975-1276

present the best material for grafts (1). Although current literature indicates several suitable sites for explanting (jaw bone and extra-oral sources such as ribs, skull, and tibia), most authors prefer explanting from the iliac crest for four major reasons:

- Abundance of both sponge and cortical bone, easily adaptable to implant site;
- Ease and subsequent speed of explantation;
- The curvature of the iliac crest is very adaptable to the maxillary facial area;
- Infrequent diseases.

The loss of the teeth causes bone resorption of the jaw, creating aesthetic and rehabilitative problems. Important atrophies can compromise facial aesthetics, particularly in cases where the simile reveals an uneven rapport between arches (2). Moreover, in This case, a non-harmonious rapport between teeth and gums or a limited opening of the oral cavity renders hygiene difficult and causes several problems.

Over the years, numerous techniques for treating maxillary atrophies, using grafts and transplants, have been proposed.

In 1980, Breine et al. (3) were the first to study the effects of these procedures. Later, Mish et al. began associating the correction and excellent results of three-dimensional maxillary defects with explant and grafting of cortical bone from the anterior-medial area of the iliac crest to elevate the maxillary sinus. Mish et al. (4) obtained a 99% survival rate after 8 years with implants inserted in grafts. After Mish et al., many others successfully proposed auto-explants from the iliac crest, with or without the maxillary sinus elevation or subsequent implant insertion. These later researches revealed that the procedure is safe (4).

## TECHNIQUES

### *Deep incision explant*

Many authors use this method when collecting large quantities of bone is necessary. The procedure requires the detachment of the gluteal muscles and the muscle of the medial hip wall (5). In the iliac crest, two incisions, one frontal and one posterior, are performed, followed by grafting. Undoubtedly, this procedure provides large quantities of bone; however, it is not free of important complications:

- Abdominal hernias
- Bleeding
- In situ e peritoneal vascular damage

Worthy of note is the risk of fracture of the iliac crest and subsequent aesthetic problems. Several variants of this technique aim to limit muscle detachment and maintain the crest's conformation (6).

### *Lateral explants*

This procedure requires the detachment of the gluteal muscles from the hip and four bone explants of a thinner section that may or may not interest the iliac crest (sub-crest). The surgery is relatively easy and rapid. Minor aesthetic problems are produced if the iliac crest is maintained. Postoperative pain, however, and impairment of deambulation are evident and long-lasting due to the detachment of the gluteal muscle and the tensor sideband. The risk of perforating the medial cortical hip wall and subsequent vascular damage, peritonitis and intestinal fissures or occlusions is not underestimated (7).

### *Medial explant*

Similar to the lateral explant technique, the procedure involves postural muscles. The involvement of a postural muscle and not the gluteus (necessary for deambulation) makes many authors prefer this technique. Due to the minor adhesion of the periosteum compared to that of the lateral hip wall, the detachment of the postural muscles is easier. The same authors also report fewer complications, such as peritoneal bleeding, loss of sensibility and aesthetic problems (8). They note that pain and deambulatory problems are less severe and require less time to recover. The theoretical risk remains of a lesion of the lateral femoral cutaneous nerve because of its location on the medial iliac. The repositioning of both periosteum and abdominal muscles seems to reduce haemorrhaging and oedema due to the pressure exerted by the intestines (9).

### *Bicortical explant with maintenance in situ of flat spongy bone*

Periosteum and medial and lateral muscles are disassembled, and four osteotomies are performed on each side to

isolate two specular bone blocks, leaving a spongiosa lamina in situ (10). This procedure leaves the iliac crest intact, even if reduced in size. Deambulatory problems remain because of the detachment of the periosteum and muscle. The risk of fracture of the remaining iliac crest, however, exists.

The oblique explant of only spongy bone segments from the crest and repositioning the crest without muscle detachment is another technique, avoiding complications (11). The two incisions are divergent; one incision starts from the crest and is executed towards the bottom of the hip bone, and a second begins laterally and extends outwards. These two incisions allow the explant of marrow bone while maintaining the residual fragments of the crest, mostly cortical, integral through bone synthesis.

#### *Explant of lateral cortical marrow bone*

This surgical procedure calls for a crosswise, full-length incision of the hip bone starting laterally under the crest. This procedure leaves the bony cap crest attached to the periosteum and abdominal muscles. To effect the incision, scalpels and spoons are required to explant the cortical marrow segment. After the explant, the crest is returned to its original position. The surgery facilitates access to the hip, reduces postoperative complications, and preserves the crest. The detachment of the gluteo muscle often compromises deambulation (12).

#### *Explant of cortical marrow medial bone with rotation of medial crest*

This procedure begins with an incision in the iliac crest membrane and continues laterally and medially to create a bony cap attached to the abdominal muscles. The cap is rotated to detach the membrane and the iliac muscle from the medial side of the ileum. A successive incision is made from a bone segment containing both cortical and marrow bone. This segment is shaped from cortical and marrow flap (results of cortical hip disk) (13). The membrane and muscle are repositioned, and the iliac crest is repositioned and secured. This procedure, sparing the gluteal and abdominal muscles from detachment and sensibly reducing problems of postoperative pain and deambulation, provides large quantities of bone and preservation of the crest. According to several authors, this surgery also avoids the necessity of drainage as the entire area of the operation is closed.

The possible complications cited by the various authors are the fracture of the residual cortical bone and the subsequent formation of retroperitoneal bleeding and hematomas (14).

### **EXPLANT SURGERY: MONO-BICORTICAL EXPLANT**

After sterilizing with iodopovidone, the operating site is delimited with sterile bandages, anaesthesia and vasoconstrictor infiltration (15).

An incision along the iliac crest is made for a length of 5-8 cm, starting at least 1 cm from the anterior point of the iliac and continuing toward the posterior iliac crest.

The subcutaneous incision includes the fascia lata and periosteum, using clamps to stop bleeding. The detachment of the periosteum exposes the explant site, giving particular attention to the iliac muscle.

The cortical bone segments are created with manual and oscillating saw blades, cutting the vertical incisions and then two parallel incisions to limit a box. The bone segment graft consists of the marrow section along the straight bone cuts. The segments should be stored in a physiologic solution before implantation. From the exposed area, spongy bone material can be collected using a surgical spoon. Intra-Osseo bleeding is controlled with collagen sponges or shaped fibrin and, if required, orthopaedic wax.

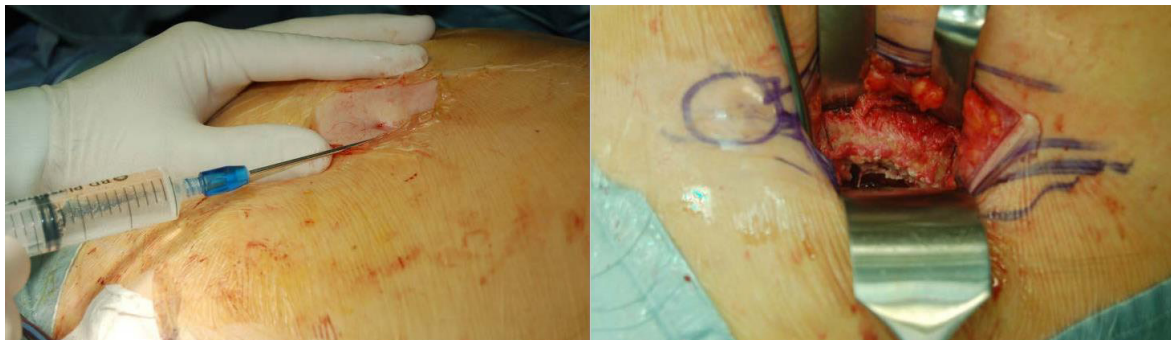After drainage placement, the suturing follows the anatomical levels inversely, starting at the periosteum and fascia lata using resorbable sutures and separate stitches. The suturing continues on the subcutaneous level with rapid absorption sutures and finally on the cutaneous level with separate or continuous stitches (16, 17). It is crucial to observe several parameters prior to the first incision (Fig. 1):

- A distance of 1 cm from the anterior point of the iliac crest to avoid damage to the inguinal canal and the insertion of the sartorius muscle;
- Safety of the ileum-gastric nerve, assuring that it lays sideways on the crest;

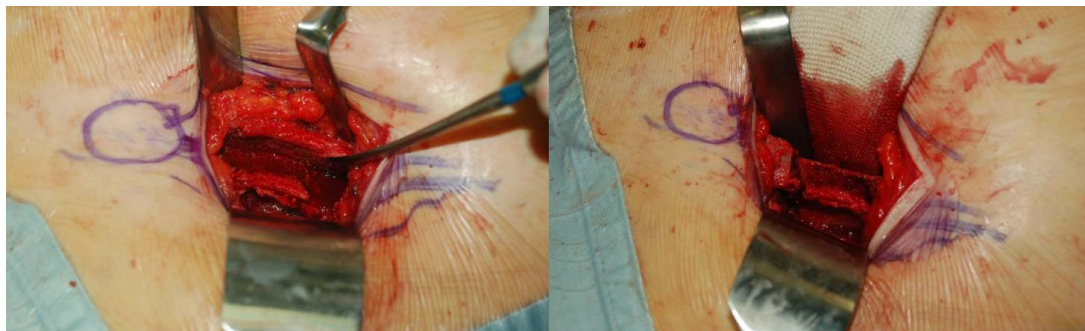
- The length of the incision is proportional to the size of the explant, usually 5-8 cm; longer incisions must always follow the vertical direction.

With adequate clamping, the lower-level incisions are executed. Without damaging the iliac and gluteal muscles, the periosteum of the crest is carefully detached from the lateral and medial sections of the hip. It is useful to perform a wide divarication and tissue protection (Fig. 2, 3), followed by a manual evaluation of the graft (18).

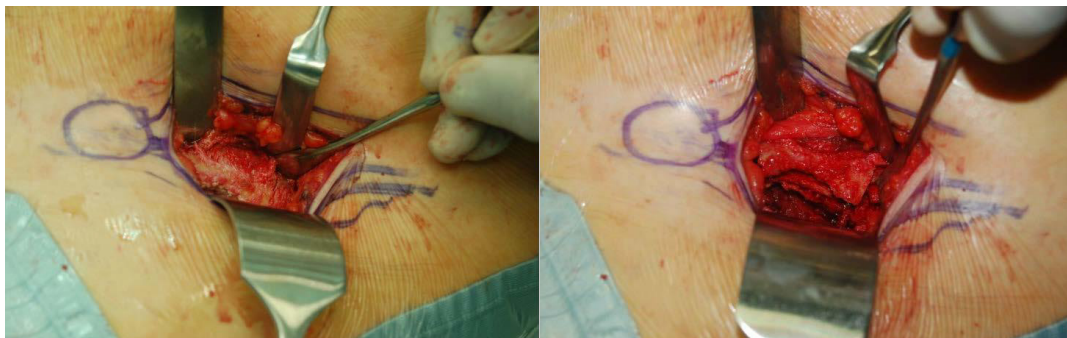The osteotomy can be made with manual or oscillating saws below the crest. The area is then delimited with two incisions of the desired width perpendicular to the iliac crest and terminates with the caudal portion resection to free the flap from the surrounding bone. A surgical spoon can be employed in the exposed area if more marrow bone is necessary. The explanted segment is preserved in a physiologic solution. The crest fragments are recomposed with plates and screws.



**Fig. 1.** *Anesthesia and first incision*



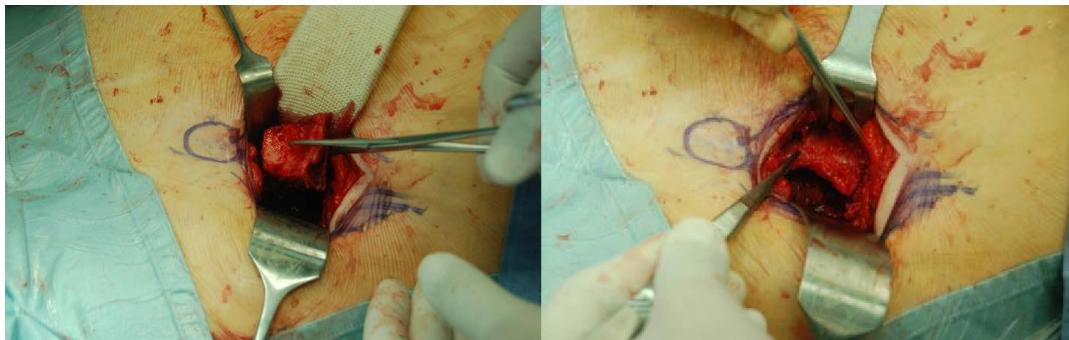**Fig. 2.** *Showing and clamping of iliac crest*



**Fig. 3.** *Showing and clamping of iliac crest*

Vascular intra-osseo hemostasis is done with collagenous sponges and compressed, and when necessary, orthopaedic wax (Fig. 4, 5) (19).

Before closing the exposed area, it is paramount to inspect accurately for bleeding to avoid complications; the suturing proceeds from the lowest level, periosteum and fascia lata, with separate stitches using slow absorption filament. The subcutaneous sutures should use rapidly absorbable filament (20). The cutaneous suturing can be either continuous or separate stitching, preferably intracutaneous, for better aesthetic results. After suturing, a compressive dressing to be removed after 24 hours, and ice packings are recommended.



**Fig. 4.** Osteotomy and harvesting of the autologous graft

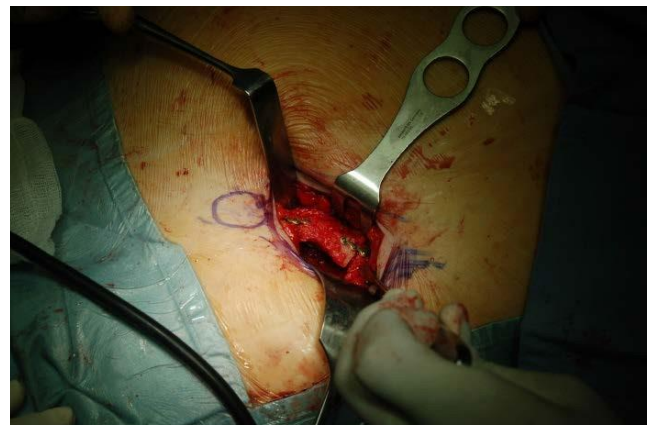#### Complications

Although relatively safe, this surgery carries both minor and major complications. The minor complications include pain, infections, accumulation of liquid and difficulty walking (21). Among the severe complications are nerve and vascular damage, fractures and hernias. The nerve damage usually interests three structures:

- The lateral branch of the cutaneous intercostal nerve;
- The lateral cutaneous branch of the iliohypogastric nerve;
- The lateral cutaneous femoral nerve.

This last complication generally occurs in those cases where the nerve is situated along the medial anterior iliac crest and below the inguinal ligament, even if in 2,7% of the cases, the nerve runs above the inguinal ligament. This position of the nerve increases the risk of nerve damage, which, if permanent, causes muscle pain.

Postoperative pain and difficulty in walking is to be expected (22). The return to normal deambulation varies with the size of the explant, and the pain may vary from a few days to 2 weeks.



**Fig. 5.** Osteotomy and harvesting of the autologous graft

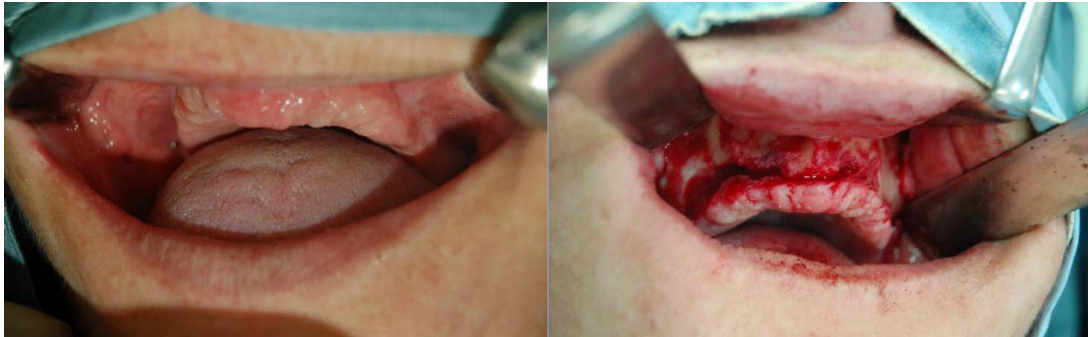
## BONE GRAFT OPERATION

Once the explant is completed, the subsequent step is the grafting in the recipient site. After preparing the site with chlorhexidine and sterile cloths, anaesthesia and vasoconstrictors to control bleeding and postoperative pain, an incision is made along the mucosa genienna (Fig. 6), extending it perpendicularly and outwards to the free mucous in order to detach the periosteum and expose the bone.

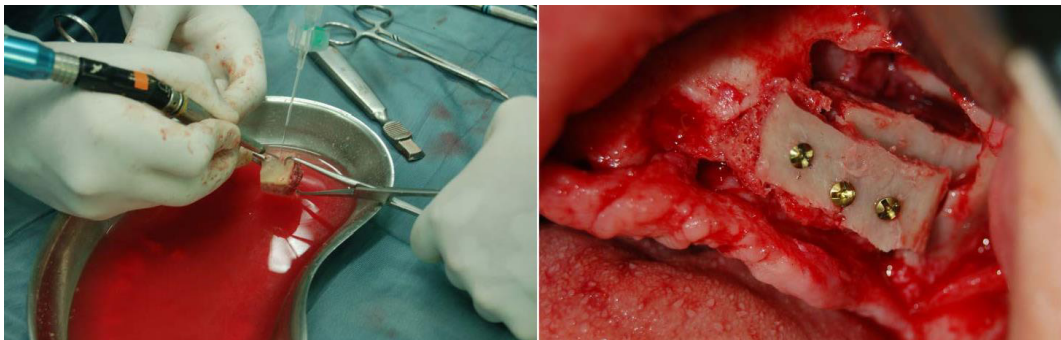
The graft is secured location using screws (Fig. 7). Sometimes, dividing the box into smaller segments may be necessary to facilitate the reconstruction of irregular surfaces. Bone spurs and rough edges can be smoothed with a hand

drill. The eventual spaces between the alveolar and the graft should be filled with spongy bone segments (23).

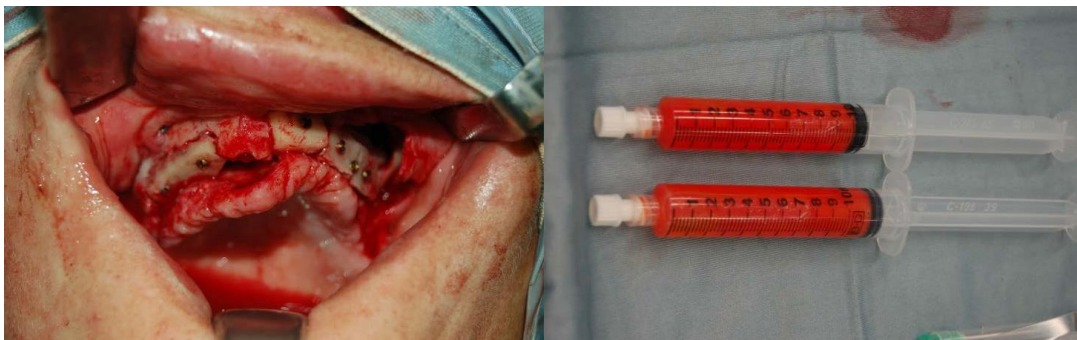Extending the incision to have sufficient tissue to close it may be necessary. The incision of the mucous membrane is closed with resorbable sutures (Fig. 8, 9) (24).



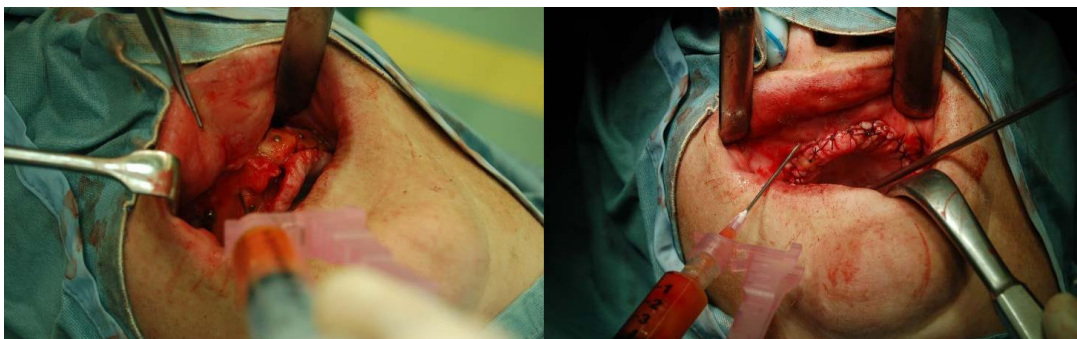
**Fig. 6.** Preparation of the maxillary site



**Fig. 7.** Preparation of bone graft and fixation with screw



**Fig. 8.** Suture of the flap



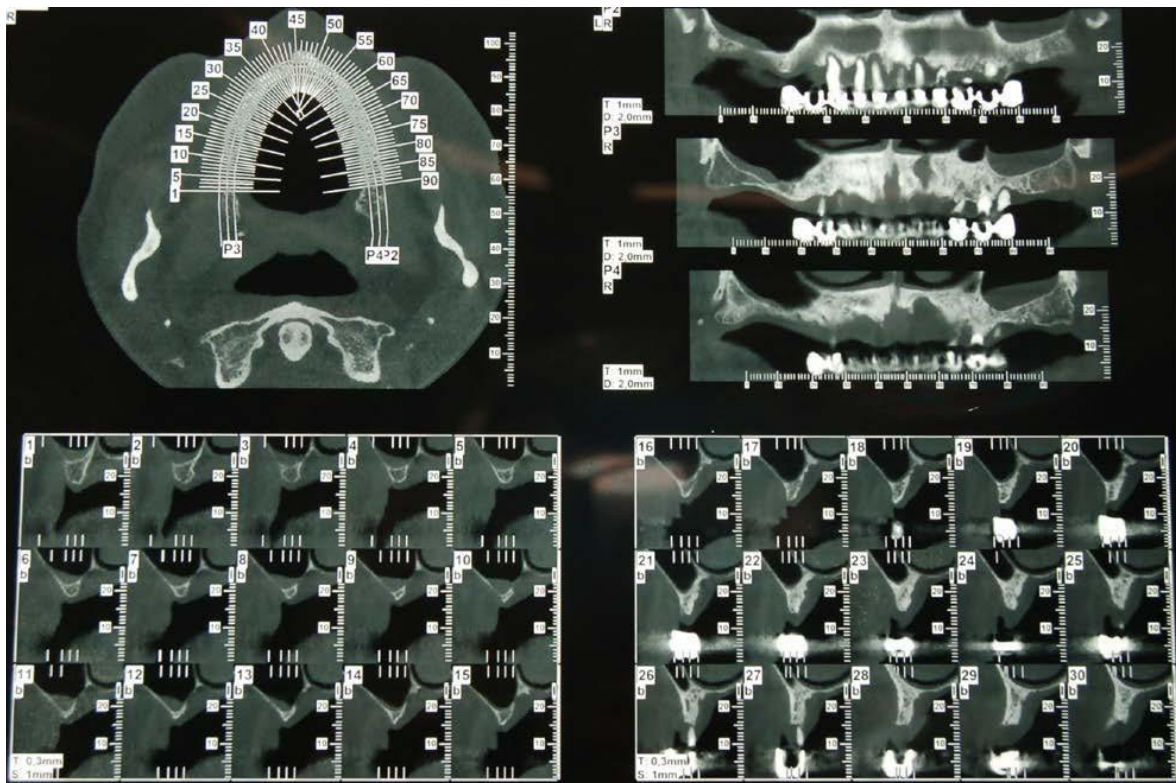
**Fig. 9.** Suture of the flap



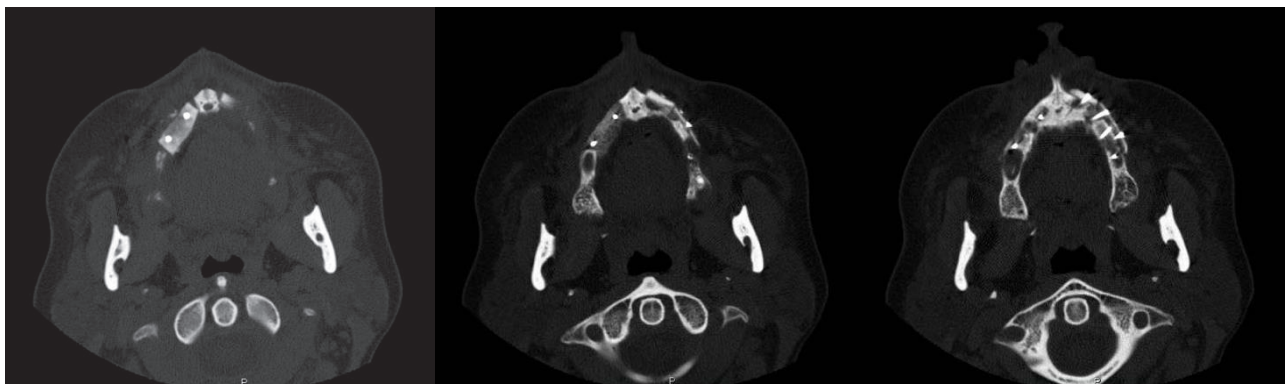## INSERTION OF THE DENTAL IMPLANTS

After 4 months without complications, the graft's integration and volume maintenance are verified with X-rays (Fig. 10, 11). In order to insert the dental implants, it is necessary to prepare a wax model and a surgical bite plate.

The insertion can be done in the dentist's office. The oral cavity is rinsed with a 0.20% chlorhexidine solution, followed by an injection of anaesthesia and vasoconstrictors. A flap of the muco-periosteum is lifted in the grafted area, and the screws used to fix the graft are removed. At the same time, it is useful to check the graft's consolidation and state of maintenance.



**Fig. 10.** Case 1: preoperative Tc Conebeam



**Fig. 11.** Coronal section of CBCT which demonstrated the fixed graft

The implant site is prepared using a drill of increasing dimensions and irrigating with a physiologic solution. When the dental cavity is ready, the implant is screwed into place (Fig. 12) using a rotating instrument and finished manually. Before suturing, a plug screw should be used to protect the thread of the dental implant (25).

Healing and maturation of bone require about 3 months. The prosthesis phase can then begin. When the complete adaption of the peri-implant tissue and a satisfactory aesthetic result is reached, the procedure may be considered optimally terminated (26) (Fig. 13, 14).

## CONCLUSIONS

Our case report and the literature review highlight that therapy for the reconstruction of important maxillary defects should be thoroughly studied and planned before selecting the best therapeutic options for each case.

In our option, the most important parameters to consider are:

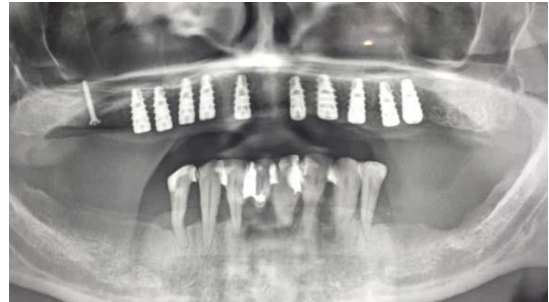The extension and form of the defect;

The subsequent determination of the site to collect the graft;

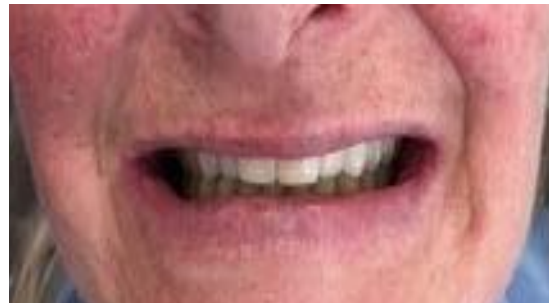We have not experienced a significant loss of bone graft volume during the healing process; therefore, iliac crest grafts are a valid and successful solution today.

## REFERENCES

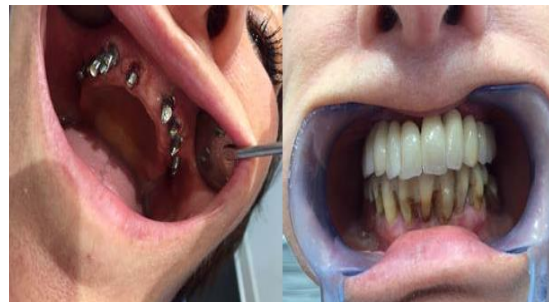1. Acocella A, Nardi P, Tedesco A, Beninati F, Giannini D. Innesto di cresta iliaca anteriore: tecniche e complicanze. *Minerva Stomatologica*. 2003;52(441-453).
2. Castagnola M, Sacco R, De Micheli L. "Innesto di cresta iliaca e rialzo del seno mascellare nella ricostruzione delle gravi atrofie posteriori. *Italian Oral Surgery* 2010;9(4):181-187.
3. Breine U, Branemark PI. Reconstruction of alveolar jaw bone. An experimental and clinical study of immediate and preformed autologous bone grafts in combination with osseointegrated implants. *Scand J Plast Reconstr Surg*. 1980;14(1):23-48. doi:https://doi.org/10.3109/02844318009105733
4. Misch CE, Dietsh F. Endosteal implants and iliac crest grafts to restore severely resorbed totally edentulous maxillae--a retrospective study. *J Oral Implantol*. 1994;20(2):100-110.
5. Sjoström M, Sennerby L, Nilson H, Lundgren S. Reconstruction of the atrophic edentulous maxilla with free iliac crest grafts and implants: a 3-year report of a prospective clinical study. *Clin Implant Dent Relat Res*. 2007;9(1):46-59. doi:https://doi.org/10.1111/j.1708-8208.2007.00034.x
6. Sjoström M, Sennerby L, Lundgren S. Bone graft healing in reconstruction of maxillary atrophy. *Clin Implant Dent Relat Res*. 2013;15(3):367-379. doi:https://doi.org/10.1111/j.1708-8208.2011.00368.x
7. Burgess M, Leung M, Chellapah A, Clark JR, Batstone MD. Osseointegrated implants into a variety of composite free flaps: A comparative analysis. *Head Neck*. 2017;39(3):443-447. doi:https://doi.org/10.1002/hed.24609
8. Mohlhenrich SC, Kniha K, Elvers D, et al. Intraosseous stability of dental implants in free revascularized fibula and iliac crest



**Fig. 12.** Rx-Orthopantomogram postoperative with multi-implants inserted in graft



**Fig. 13.** Extra-oral view of full-arch rehabilitation.



**Fig. 14.** Intra-oral view of full-arch rehabilitation.

- bone flaps. *J Craniomaxillofac Surg*. 2016;44(12):1935-1939. doi:<https://doi.org/10.1016/j.jcms.2016.09.011>
9. Shayesteh YS, Khojasteh A, Siadat H, et al. A comparative study of crestal bone loss and implant stability between osteotome and conventional implant insertion techniques: a randomized controlled clinical trial study. *Clin Implant Dent Relat Res*. 2013;15(3):350-357. doi:<https://doi.org/10.1111/j.1708-8208.2011.00376.x>
  10. Blake F, Bubenheim M, Heiland M, Pohlenz P, Schmelzle R, Gbara A. Retrospective assessment of the peri-implant mucosa of implants inserted in reanastomosed or free bone grafts from the fibula or iliac crest. *Int J Oral Maxillofac Implants*. 2008;23(6):1102-1108.
  11. Meloni SM, Tallarico M, De Riu G, et al. Guided implant surgery after free-flap reconstruction: Four-year results from a prospective clinical trial. *J Craniomaxillofac Surg*. 2015;43(8):1348-1355. doi:<https://doi.org/10.1016/j.jcms.2015.06.046>
  12. Lopez GD, Hijji FY, Narain AS, Yom KH, Singh K. Iliac Crest Bone Graft: A Minimally Invasive Harvesting Technique. *Clin Spine Surg*. 2017;30(10):439-441. doi:<https://doi.org/10.1097/BSD.0000000000000556>
  13. Suchomel P, Barsa P, Buchvald P, Svobodnik A, Vanickova E. Autologous versus allogenic bone grafts in instrumented anterior cervical discectomy and fusion: a prospective study with respect to bone union pattern. *Eur Spine J*. 2004;13(6):510-515. doi:<https://doi.org/10.1007/s00586-003-0667-z>
  14. Shao MH, Zhang F, Yin J, Xu HC, Lyu FZ. Titanium cages versus autogenous iliac crest bone grafts in anterior cervical discectomy and fusion treatment of patients with cervical degenerative diseases: a systematic review and meta-analysis. *Curr Med Res Opin*. 2017;33(5):803-811. doi:<https://doi.org/10.1080/03007995.2017.1284050>
  15. Nandi SK, Roy S, Mukherjee P, Kundu B, De DK, Basu D. Orthopaedic applications of bone graft & graft substitutes: a review. *Indian J Med Res*. 2010;132(15-30).
  16. de Freitas RM, Susin C, Spin-Neto R, et al. Horizontal ridge augmentation of the atrophic anterior maxilla using rhBMP-2/ACS or autogenous bone grafts: a proof-of-concept randomized clinical trial. *J Clin Periodontol*. 2013;40(10):968-975. doi:<https://doi.org/10.1111/jcpe.12148>
  17. Schmitt CM, Doering H, Schmidt T, Lutz R, Neukam FW, Schlegel KA. Histological results after maxillary sinus augmentation with Straumann(R) BoneCeramic, Bio-Oss(R), Puros(R), and autologous bone. A randomized controlled clinical trial. *Clin Oral Implants Res*. 2013;24(5):576-585. doi:<https://doi.org/10.1111/j.1600-0501.2012.02431.x>
  18. Stellingsma K, Raghoobar GM, Visser A, Vissink A, Meijer HJ. The extremely resorbed mandible, 10-year results of a randomized controlled trial on 3 treatment strategies. *Clin Oral Implants Res*. 2014;25(8):926-932. doi:<https://doi.org/10.1111/clr.12184>
  19. Chiapasco M, Di Martino G, Anello T, Zaniboni M, Romeo E. Fresh frozen versus autogenous iliac bone for the rehabilitation of the extremely atrophic maxilla with onlay grafts and endosseous implants: preliminary results of a prospective comparative study. *Clin Implant Dent Relat Res*. 2015;17 Suppl 1(e251-266). doi:<https://doi.org/10.1111/cid.12191>
  20. Fretwurst T, Wanner L, Nahles S, et al. A prospective study of factors influencing morbidity after iliac crest harvesting for oral onlay grafting. *J Craniomaxillofac Surg*. 2015;43(5):705-709. doi:<https://doi.org/10.1016/j.jcms.2015.03.023>
  21. Kuik K, Putters TF, Schortinghuis J, van Minnen B, Vissink A, Raghoobar GM. Donor site morbidity of anterior iliac crest and calvarium bone grafts: A comparative case-control study. *J Craniomaxillofac Surg*. 2016;44(4):364-368. doi:<https://doi.org/10.1016/j.jcms.2015.12.019>
  22. Shaw KA, Griffith MS, Shaw VM, Devine JG, Gloystein DM. Harvesting Autogenous Cancellous Bone Graft from the Anterior Iliac Crest. *JBJS Essent Surg Tech*. 2018;8(3):e20. doi:<https://doi.org/10.2106/JBJS.ST.17.00068>
  23. Hettwer W, Horstmann PF, Bischoff S, et al. Establishment and effects of allograft and synthetic bone graft substitute treatment of a critical size metaphyseal bone defect model in the sheep femur. *APMIS*. 2019;127(2):53-63. doi:<https://doi.org/10.1111/apm.12918>
  24. Azi ML, Aprato A, Santi I, Kfuri M, Jr., Masse A, Joeris A. Autologous bone graft in the treatment of post-traumatic bone defects: a systematic review and meta-analysis. *BMC Musculoskelet Disord*. 2016;17(1):465. doi:<https://doi.org/10.1186/s12891-016-1312-4>
  25. Lemos CA, Ferro-Alves ML, Okamoto R, Mendonca MR, Pellizzer EP. Short dental implants versus standard dental implants

- placed in the posterior jaws: A systematic review and meta-analysis. *J Dent.* 2016;47(8-17). doi:<https://doi.org/10.1016/j.jdent.2016.01.005>
26. Albrektsson T, Johansson C. Osteoinduction, osteoconduction and osseointegration. *Eur Spine J.* 2001;10 Suppl 2(Suppl 2):S96-101. doi:<https://doi.org/10.1007/s005860100282>